

GOVERNMENT OF INDIA

ARCHAEOLOGICAL SURVEY OF INDIA

CENTRAL  
ARCHAEOLOGICAL  
LIBRARY

ACCESSION NO. 36208

CALL No. 611. LeV

D.G.A. 79.

TYPEWRITING USE OF GEOGRAPHY WAY TO POETRY WRIT  
COOKERY FOR GIRLS DOGS AS PETS FOR BOYS AND GIRLS KNIT  
PHOTOGRAPHY FOR BOYS AND GIRLS RADIO FOR BOYS RIDING  
SOCCER FOR BOYS STAMP COLLECTING FOR BOYS AND GIRLS WO  
ACTING ANATOMY ARABIC ASTRONOMY BANKING BEE  
CHILDREN BUSINESS ORGANISATION CALCULUS CANASTA C  
COMMERCIAL ART COMMERCIAL CORRESPONDENCE COMMER  
CONTRACT BRIDGE COOKING CRICKET DRAWING DRESS  
ECONOMICS ELECTRICITY ELECTRICITY IN THE HOUSE ELOCU  
ENGLISH RENAISSANCE ENGLISH RENAISSANCE TO THE ROMANTIC  
LITERATURE ETCHING EVERYDAY FRENCH TO EXPRESS YOURS  
DICTIONARY FRENCH PHRASE BOOK GARDENING GAS IN TH  
GERMAN GERMAN DICTIONARY GERMAN GRAMMAR GERMAN  
CONTROL OF PLANT DISEASES GOOD FARM ACCOUNTING G  
GOOD FARM WORKMANSHIP GOOD FRUIT FARMING GOOD GRA  
GOOD MILK FARMING GOOD PIG KEEPING GOOD POULTRY KEE  
GREGG SHORTHAND GUIDEBOOK TO THE BIBLE HINDUSTANI  
CATHERINE THE GREAT CHATHAM CLEMENCEAU CONSTANTINE CO  
ARC JOHN WYCLIFFE LENIN LOUIS XIV HILTON PERICLES PETER TH  
USE OF HISTORY WARREN HASTINGS WOODROW WILSON HOCKE  
HOUSEHOLD ELECTRICITY HOUSE REPAIRS ITALIAN JOINERY  
MANAGEMENT MATHEMATICS HAND TOOLS ENGINEERING  
DRAUGHTSMANSHIP METEOROLOGY MODEL CRAFT MODERN DAN  
MUSIC NORWEGIAN PERSONAL EFFICIENCY PHILOSOPHY PHO  
SHORTHAND PLANNING AND DESIGN PLUMBING POLISH PO

ARABIC ASTRONOMY BANKING BEE-KEEPING BIOLOGY  
CANALISATION CALCULUS CANASTA CARPENTRY CHEMISTRY  
COMMERCIAL CORRESPONDENCE COMMERCIAL TRAVELLING TO  
CRICKET DRAWING DRESSMAKING DUTCH DUTTON  
ELECTRICITY IN THE HOUSE ELOCUTIONIST EMBROIDERY  
ENGLISH RENAISSANCE TO THE ROMANTIC REVIVAL ROMANTIC  
EVERYDAY FRENCH TO EXPRESS YOURSELF FISHING TO FLY  
HOUSE BOOK GARDENING GAS IN THE HOUSE GEOGRAPHY OF  
DICTIONARY GERMAN GRAMMAR GERMAN PHRASE BOOK GOLF  
GOOD FARM ACCOUNTING GOOD FARM CROPS GOOD FARMING  
HUT FARMING GOOD GRASSLAND GOOD AND HEALTHY ANIMALS  
GOOD POULTRY KEEPING GOOD SHEEP FARMING GOOD SOIL  
HINDUSTANI HISTORY ABRAHAM LINCOLN ALEXANDER THE  
CAESAR CONSTANTINE COOK CRANMER ERASMUS GLADSTONE AND  
MILTON PERICLES PETER THE GREAT PUSHKIN RALEIGH RICHELIEU  
WODROW

... AND HE WILL BE  
YET WISER *Proverbs 9.9*

AND PURPOSE SOCCER SPANISH STEPS AND  
SWEDISH TEACHING THINKING TRIGONOMETRY  
BRITISH RAILWAYS FOR BOYS CAMPING FOR BOYS AND GIRLS  
FOR GIRLS MODELMAKING FOR BOYS NEEDLEWORK FOR GIRLS  
BOYS AND GIRLS SAILING AND SMALL BOATS FOR BOYS AND GIRLS  
WORK FOR BOYS ADVERTISING & PUBLICITY ALGEBRA AMATEUR  
FISHING BIOLOGY BOOK-KEEPING BRICKWORK BRINGING UP  
COUNTRY CHEMISTRY CHESS CHINESE COMMERCIAL ARITHMETIC  
TRAVELLING TO COMPOSE MUSIC CONSTRUCTIONAL DETAILS  
DUTCH DUTTON SPEEDWORDS ECONOMIC GEOGRAPHY  
EMBROIDERY ENGLISH GRAMMAR LITERARY APPRECIATION  
ROMANTIC REVIVAL VICTORIAN AGE CONTEMPORARY  
FISHING TO FLY FREELANCE WRITING FRENCH FRENCH  
HOUSE GEOGRAPHY OF LIVING THINGS GEOLOGY GEOMETRY  
HOUSE BOOK GOLF GOOD CONTROL OF INSECT PESTS GOOD  
FARM CROPS GOOD FARMING GOOD FARMING BY MACHINE  
GOOD AND HEALTHY ANIMALS GOOD MARKET GARDENING  
GOOD SHEEP FARMING GOOD SOIL GOOD ENGLISH GREEK  
HISTORY ABRAHAM LINCOLN ALEXANDER THE GREAT BOLIVAR BOTHA  
CRANMER ERASMUS GLADSTONE AND LIBERALISM HENRY V JOAN OF  
ARCADE PUSKIN RALEIGH RICHELIEU ROBESPIERRE THOMAS JEFFERSON  
HOME NURSING HORSE MANAGEMENT HOUSEHOLD DOCTOR  
JOURNALISM LATIN LAWN TENNIS LETTER WRITER MALAY  
FONENTE WORKSHOP PRACTICE MECHANICS MECHANICAL  
MORE GERMAN MOTHERCRAFT MOTORING MOTOR CYCLING  
PHYSICAL GEOGRAPHY PHYSICS PHYSIOLOGY PITMAN'S  
CHINESE PSYCHOLOGY PUBLIC ADMINISTRATION PUBLIC SPEAKING



THE TEACH YOURSELF BOOKS  
EDITED BY LEONARD CUTTS

ANATOMY

L.B.S

Uniform with this volume  
and in the same  
series

---

TEACH YOURSELF  
TO BRING UP CHILDREN

TEACH YOURSELF  
HOME NURSING

TEACH YOURSELF  
MOTHERCRAFT

TEACH YOURSELF  
SEX  
Its Meaning and Purpose

TEACH YOURSELF  
PHYSIOLOGY

TEACH YOURSELF  
BOTANY

TEACH YOURSELF  
BIOLOGY

THE TEACH YOURSELF  
HOUSEHOLD DOCTOR

# ANATOMY

By

DAVID LE VAY

M.S., F.R.C.S.

36208



611

Le V

THE ENGLISH UNIVERSITIES PRESS LTD

102, NEWGATE STREET

LONDON, E.C.3

*First Printed* . . . . . 1948  
*New Edition* . . . . . 1957  
*This Impression* . . . . . 1958

*All Rights Reserved*

**CENTRAL ARCHAEOLOGICAL  
LIBRARY, NEW DELHI.**

**Acc. No.** ... 36208 .....  
**Date** ..... 4-10-62 .....  
**Call No.** ... 611 / Le V .....  
.....

# CONTENTS

CHAPTER

## PREFACE

I.	DEFINITIONS, APPLICATIONS, HISTORY . . . . .	9
II.	STANDARD POSITIONS, TERMS AND REFERENCES; NOMENCLATURE; THE BODY SYSTEMS; SYMMETRY AND SEGMENTATION . . . . .	16
III.	CELLS AND TISSUES . . . . .	30
IV.	CARTILAGE AND BONE; THE SKELETON; JOINTS . . . . .	46
V.	THE ARM . . . . .	64
VI.	THE LEG . . . . .	102
VII.	ABDOMEN . . . . .	143
VIII.	THORAX . . . . .	190
IX.	HEAD AND NECK . . . . .	212
X.	SPINAL COLUMN . . . . .	238
XI.	NERVOUS SYSTEM . . . . .	246
XII.	ENDOCRINE GLANDS . . . . .	276
XIII.	REPRODUCTION AND DEVELOPMENT . . . . .	281
XIV.	EVOLUTION . . . . .	294
	GLOSSARY-INDEX . . . . .	305



## LIST OF COLOURED PLATES

1. Plan of the main nerves and vessels of the upper limb . . . . . 96
2. Nerves and vessels in the hand . . . [back] 96
3. Surface marking of the arteries of the lower limb . . . . . 128
4. Plan of the main nerves and vessels of the lower limb . . . . . [back] 128
5. Surface markings of certain abdominal organs 160
6. Structure of the posterior abdominal wall . . . [back] 160
7. Surface marking of lungs and pleural cavities |  
 Contents of the right groin . . . . . | 192
8. Contents of the right side of the chest . [centre] 192
9. Contents of the left side of the chest . [centre] 192
10. Surface marking of the great arteries of the neck . . . . . }  
 Great vessels and nerves in their course from } 192  
 trunk to arm . . . . . [back]
11. Larynx, thyroid gland, great vessels of neck . 224
12. Functional areas in left cerebral hemisphere . }  
 Cross section of spinal cord, showing nerve } 224  
 tracts . . . . . [back]

## PREFACE

The study of anatomy without a body to dissect is a little like Hamlet without the Prince. I have tried to make up for this by providing as many illustrations as a book of this size will carry; and it is the reader's duty to make the best use of these, and to persuade himself that he has a sound *visual* grasp of what one portion of text is about before moving on to the next. The surface anatomy of particular regions is also described at some length, and here the student can obtain first-hand information from his own body, or from that of an obliging friend.

Most of the figures are the work of Miss Sheila Hayes, of Messrs. E. O. Sonntag. The remainder are by Mrs. Lucy Geddes. I am indebted to Messrs. Longmans, Green and Company for their kindness in giving me permission to have redrawn a number of illustrations from *Gray's Anatomy*. These are individually acknowledged in the text. My thanks are also due to my Publishers for the care and accuracy they have shown in the preparation of this book.

## PREFACE TO SECOND EDITION

In preparing this edition the book has been carefully revised and some previous errors eliminated. A new Chapter has been added dealing briefly with the evolutionary aspects of human anatomy, and I am grateful to Professor J. Z. Young and the Oxford University Press for permission to use therein certain material from Professor Young's *Life of Vertebrates*. The Index has now become the Glossary-Index originally promised.

D. L.



## CHAPTER I

### DEFINITIONS, APPLICATIONS, HISTORY

#### Definitions.

THE literal meaning of the word anatomy is the cutting up of the body to examine its parts and their relations one to another. Knowledge gained by dissection in this way is essentially *regional* or *topographical*; that is to say, one gains a familiarity with each part, such as the arm or leg, similar to one's acquaintanceship with the particular districts of a city; and this is in fact how the medical student first learns his way about the human body. But every part is found to contain the same kinds of organs—blood vessels, nerves, bones, etc.; so that, superimposed on regional anatomy, there is a *systematic* point of view, in which the body is considered as made up of several co-ordinated systems, vascular, nervous, skeletal, and so on, each of which has a definite unity of its own.

Gross naked-eye observations of this kind are known as *macroscopic* anatomy; this is contrasted, though only in gradation, with microscopic anatomy or *histology*, the study of the structure of the individual cells and tissues.

So far, all this implies a static view of adult anatomy as an unchanging entity, a very necessary practical viewpoint for such people as the surgeon. But there is also the standpoint of developmental anatomy; this consists first, of *embryology*, the growth of the individual within the womb from the single cell formed by the fusion of ovum and spermatozoon, and secondly, the *post-natal*

*development* through infancy and childhood to maturity. Towards the end of life, certain changes of *senescence* begin to appear but these are usually regarded as pathological rather than anatomical; and similarly, *morbid anatomy*, the study of diseased organs, really comes within the separate science of pathology.

The development of the individual is known as *ontogeny*, and is contrasted with *phylogeny*, the evolutionary development of the race from more primitive forms; to some extent, the individual recapitulates phylogeny in a condensed and distorted form during his own development. *Comparative anatomy* is the study of the human body as a finished product in relation to the structure of animals; we sometimes use the word *morphology* for the investigation of differences and resemblances in the structure, use and evolutionary fate of corresponding organs in man and animals. For example, the human foot and the horse's hoof, structures essentially similar, are evolved on modified lines with differing final uses.

Returning for a moment to systematic anatomy, it is obvious that the study of the structure of various body-systems and tissues can only be artificially separated from the investigation of their actual working in life and the related biochemical and biophysical processes, i.e., *physiology*. Nevertheless, the distinction has to be made for the convenience of practical purposes though, unless function is always borne in mind, the mere study of form is sterile.

### Methods.

Of the practical methods of acquiring anatomical knowledge, the oldest and most basic is of course by *dissection*, a process extended in recent centuries by *microscopy*. There is also *surface anatomy*, the relation of the superficial landmarks of the body to the deeper

structures, of particular value to the artist. And there is the use of the *X-rays*, which show up the bones, the skeletal system, and can also be used to demonstrate hollow organs—intestines, canals, blood-vessels—if they are filled with substances opaque to the rays; or solid organs can be studied if they are outlined by surrounding them with air blown in by injection. *Radiographic anatomy* is particularly valuable because it indicates the undisturbed relations of an individual organ to the body as a whole, especially in the living body; such an organ as the stomach, for instance, has been shown to experience unexpectedly great variations in position under such different circumstances as the change from lying to standing position, with emotional upsets, and after meals; some of these positions correspond not at all to the standard views, based on ordinary dissection in formalin-hardened bodies.

### Variation.

A general principle in anatomy is that of the essential similarity of all human beings; but against this background there is a continuous variation from the standard pattern as far as inessential details are concerned. Just as we outwardly vary in height and colouring of eyes or hair, so internally there may be minor aberrations in the arrangement of nerves and blood-vessels, or the exact arrangement of the bile-ducts, or in the particular relation different structures bear to each other. But just as the general descriptive catalogue—"item, two lips, in-different red; item, two eyes, with lids to them; item, one neck, one chin and so forth" is always correct, so we may be sure that the femoral artery or the biceps muscle is where we expect to find it; in fact, the average anatomical structure is considerable less of a fiction than the average man. Occasionally, of course, there are grosser developmental errors which are not really part of this



normal range of variation. They represent a gross failure or distortion of normal processes, e.g., the absence of a part of a limb, or the transposition of the heart or viscera in mirror-image fashion.

### **Applications.**

The application of anatomical knowledge is made by numerous professions. First and foremost by the physician or surgeon, especially by the latter, who needs to be rather more familiar with the geography of the body than with the palm of his own hand; an essentially regional approach in which the individual variations of structure acquire an immediate practical importance, since a vital duct or vessel must be recognized before it is injured and must not be assumed to lie in the "normal position"; a regional approach which has led to some extent to a loss of comprehension of the individual as a whole organism requiring attention in its own right.

The nurse and the medical orderly need some anatomical grounding for two reasons; for their own good as a general discipline informing their daily activities with knowledge and purpose, and for practical use in such nursing procedures as those connected with the orifices of the body, or the checking of hæmorrhage by arterial compression. The masseuse must know, to work to greater advantage, what muscles lie beneath her fingers; and the artist, confined though he may be to surface representation, cannot but be helped by an appreciation of the relations between body contours and the deeper structures which produce them.

## **HISTORY**

Before proceeding to a detailed account of the anatomy of the body, a brief historical review of the subject will be of value. We may assume some prehistoric anatomical instinct in that carvings and cave

drawings are accurate in contour and indicate some acquaintance with underlying structures. And the Egyptians probably had a considerable body of knowledge derived from embalming, from various surgical procedures, and from ritual divination using the viscera of animals. But it is to the Greeks that we owe the real development of the idea of anatomical structure as a matter for deliberate investigation, coloured though their views were throughout by speculative philosophical views on humours and vital spirits, and by misconception of the working of the vascular system. The superb surface anatomy of Greek sculpture is well known; and various operations such as trephining for head injuries were in common practice. Aristotle and Hippocrates are the two great names of this period. Aristotle, the founder of comparative anatomy, probably never did any human dissection but made many accurate observations on adult and embryo animals; Hippocrates worked from a more practical surgical viewpoint in connexion with fractures and dislocations, and accomplished some dissection. After the death of Aristotle the school at Alexandria continued the Greek tradition, establishing an anatomical discipline which included the public dissection of human bodies; in fact, there is some dispute as to whether human vivisection was practised at this time.

During the Roman period there was a medical school in the capital, and systematic descriptions of bones and organs began to be recorded. In the second century A.D., Galen stands out as the greatest physician and anatomist of antiquity; his work was the basis of European knowledge of anatomy for a thousand years, surviving even the Dark Ages which were marked by a cessation of scientific activity for centuries, and reappearing in translation from the Arab scholars.

The Middle Ages were characterized by the rise of the great Italian universities and medical schools such as



Bologna and Padua, at which students were instructed by a rather formal mode of dissection in which the established writ of Galen was still unquestioned. The great figure of Leonardo da Vinci is remarkable in this time as a brilliant dilettante artist and anatomist, who established sound principles of anatomical illustration which were developed by the discovery of printing. In the 16th century, Vesalius effected an enormous and essential change in replacing the traditional reliance on Galen by the method of direct personal observation and dissection; after the publication of his great work "*On the Fabric of the Human Body*", anatomy became rejuvenated.

In England, dissection is not known to have begun until the very end of the 15th century, but some demonstrations on the corpses of criminals by the Barber Surgeons were authorised in Henry VIII's reign; and William Harvey's birth in 1578 heralded the flourishing of a period of anatomical and physiological research, ushered in by the discovery of the circulation of the blood. During the middle and latter parts of the 18th century, the famous brothers William and John Hunter gave an immense impetus, not only to dissection and pure anatomy, but to their applications in surgery; and John's specimens became the basis of the great Hunterian Collection of the Royal College of Surgeons. By the close of the century anatomy was recognized as a basic subject to be taught to new students at the medical schools.

A romantic passage in our own anatomical history is connected with the difficulty in obtaining subjects for dissection in the early 19th century. Only the bodies of hanged criminals were available—in fact their dissection was compulsory by law; but this source proving inadequate, the snatching of freshly-buried corpses by the "resurrection men" became prevalent in London and particularly in Glasgow and Edinburgh, a lucrative profession for the ruffians concerned, who were well paid for

their work. Increasing public anger was aroused, especially when murders were committed to obtain bodies for sale, culminating in the infamous Burke and Hare episode in Edinburgh. The shocking disclosures at their trial in 1828 were ultimately responsible for the Anatomy Act of 1831 regularizing the conduct of schools of anatomy and authorizing the use of unclaimed bodies from institutions.

It has been well said that the history of anatomy "is one long struggle in the search after truth. The early anatomists in their desire for knowledge had to overcome many obstacles, to suppress their own prejudices, to overcome the natural disgust raised by the smell of a corrupting body, to brave human laws; to withstand the ban of the Christian church; to rob the grave in the dead of night, and pursue their studies in secrecy and peril. How well they have succeeded in their task! Topographical anatomy has been probed to its depths, every detail has been exposed, and there is little left for us to do."\*

\*R. H. Hunter : *A Short History of Anatomy*. London, 1931.

## CHAPTER II

### STANDARD POSITIONS, TERMS AND REFERENCES; NOMENCLATURE; THE BODY SYSTEMS; SYMMETRY AND SEGMENTATION

#### Positions, Terms and References.

It is essential to understand that, for the purposes of anatomical description and the localization of parts, the body is always considered as being in a particular conventional position. This is as important as in map-reading, where two people can understand each other's references because of a prior agreement to stick to the same methods of plotting and the same arrangement of North and South. In this standard position the body is imagined erect, with the arms by the side and the thumbs out, so that the palms of the hands face forwards. The front of the body and limbs is the *anterior* surface, the back is *posterior*; so that if the relation of any two structures is being considered, one may be described as anterior or posterior to the other in so far as it is nearer the anterior or posterior surface. Anterior is sometimes also called *ventral*, and posterior *dorsal*, a derivation from the condition in animals where the belly faces the ground.

The position of structures is also related to the median plane of the body (AA in fig. 1). One point is said to be *medial* to another which is placed further from the mid-line, the second point being *lateral* to the first. And points nearer the head end are *superior* to those *inferior* ones nearer the feet; *cranial* is sometimes used for superior and *caudal* for inferior, corresponding to the head and tail of animals.

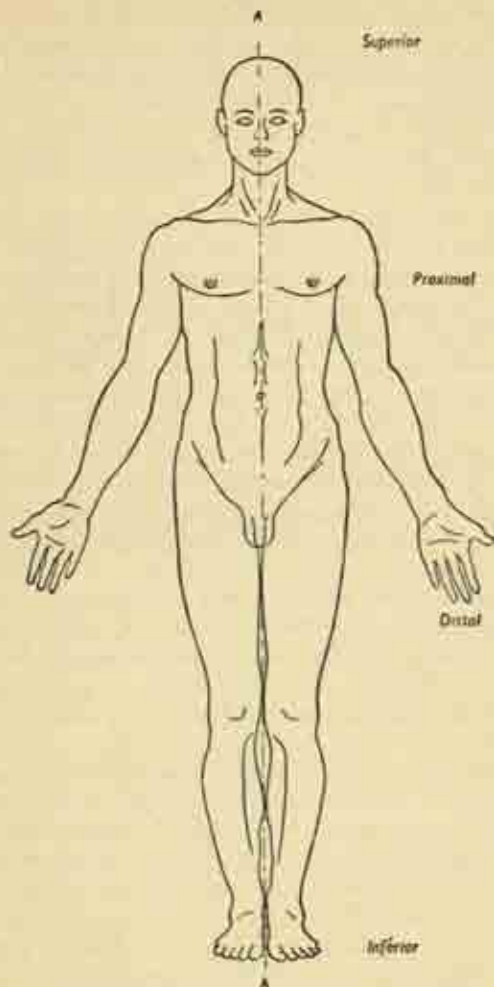


FIG. 1. The conventional view of the body from in front, showing its anterior surface. AA is the median plane.

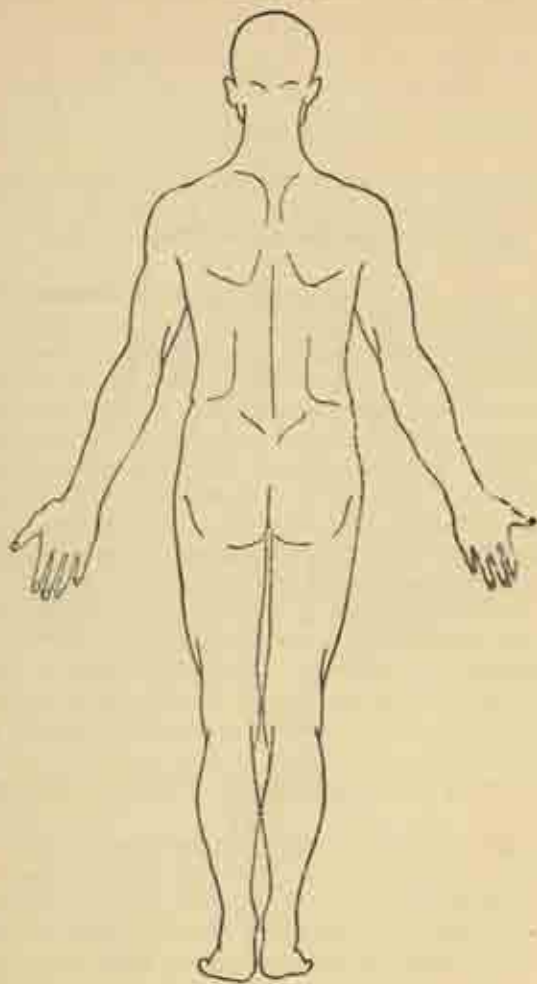


FIG. 2. The posterior surface of the body.

*Internal* and *external* are descriptive of the boundary walls of body cavities or hollow organs; thus the ribs have an external surface directed outwards and an internal surface facing towards the thoracic cavity. *Superficial* and *deep* are obvious references to relative distances from the surface, e.g., the skin is superficial to the underlying muscles.

Certain other terms are used in connexion with the limbs. Here, anterior may become *palmar* (hand) or *plantar* (sole of foot), with *dorsal* for the posterior surface or back of hand or the upper surface of foot. Also, lateral and medial may be referred to in the limbs by names derived from the corresponding paired bones of forearm and lower leg, i.e., *radial* and *ulnar*, or *fibular* and *tibial*. Points nearer the shoulder or groin are *proximal* to those *distal* ones situated nearer the fingers or toes. *Peripheral* corresponds roughly to distal, but is usually employed for the more outlying distribution of the branches of the circulatory and nervous systems.

Finally, it is often necessary to refer to sections through the body; these may be *horizontal* (transverse), *sagittal* (along or parallel to the median plane), or *coronal* (along or parallel to the coronal plane BB in fig. 3 at right angles to the median plane. All the terms given above must be mastered before proceeding; they are the cardinal points of the anatomical compass, without which the exploring student will become hopelessly lost.

**Nomenclature.** It is equally important to have an agreed system of names for parts of the body; a standard nomenclature is therefore used throughout the world, based on the original Latin terminology and revised at intervals. These revisions are, however, infrequent, and since different generations of students may be brought up under different systems, there is inevitably some overlapping. Surgeons particularly tend to retain the older

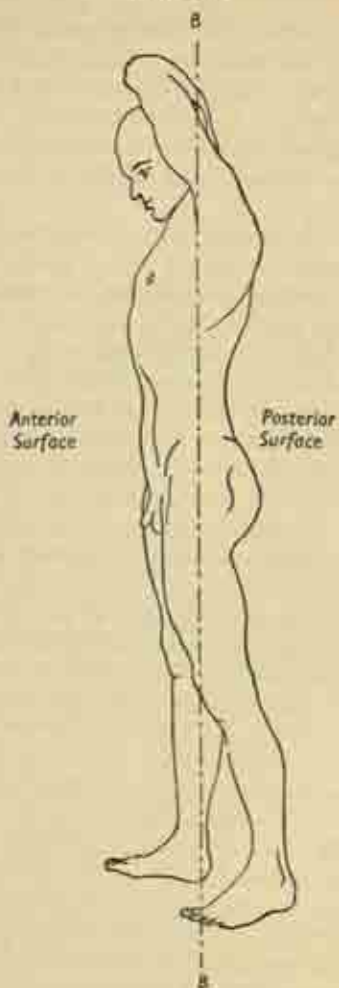


FIG. 3. The body in side view.  
BB is the coronal plane.



names, and in some cases two or more terms may be colloquially used for the same structure.

In this book no attempt has been made to adhere to any particular scheme, and the names will be introduced naturally in the course of description.

**Symmetry and Segmentation.** The two halves of the body on each side of the median plane are very largely similar, with corresponding right and left limbs, right and left kidney, and so on; i.e., many structures are *symmetrical*. This symmetry is far from perfect, however, as some internal organs are mainly one-sided (the liver), or entirely so (the spleen); and even the opposite limbs or the two halves of the brain are never exactly the same.

The human body repeats, in very modified form, the primitive arrangement of *segmentation*; this is widespread in the animal kingdom and well exemplified in the earthworm, which is made up of a number of identical segments, each containing the same organs and to a certain extent independent, though the gut traverses them in common. Integrated as he is, man still retains many features of this segmentation, though it is more clearly seen in the embryo than in the adult state. It is displayed in the arrangement of the vertebral column, in the series of paired ribs, and in the segments of the spinal cord, each of which gives off a pair of spinal nerves to the appropriate body-segment, distorted though these have become by reason of the emergence of the limbs.

### The Body Systems

These are :

The skeletal system—the bones.	} Together constituting the locomotor system.
The joints or articulations.	
The muscles.	



The respiratory system.	}	Together constituting the visceral organs.
The digestive system.		
The urogenital system.		
The vascular system—heart, blood vessels, lymphatics.		
The nervous system, and the sense-organs.		

Before proceeding further, it will be useful to get some idea of the general lie of the land by examining briefly four of these systems.

**Digestive System.** Food passing through the mouth enters an expanded cavity behind, the pharynx, which is also common to the air-passage at this level. It then travels down the gullet (oesophagus) to the stomach, thence to the coils, first of the small, and then of the large intestine. The waste matter of the food, or faeces, then enters the lowest part of the large bowel—the rectum—and is expelled through a short anal canal. At various points along the digestive tract certain glands are situated and discharge their secretions into it. These are the three pairs of salivary glands around the mouth; the pancreas, below the stomach; and the liver, which overlies the stomach.

**Respiratory system.** Air inhaled through the nose or mouth enters the pharynx behind and travels down through the air-passage proper below. The first part of this is the larynx, which is also the organ of voice; and this leads on to the trachea or windpipe, which divides in the upper part of the chest into a right and left bronchus for the right and left lung. Each bronchus subdivides within the lung to form numerous branching bronchioles which end in clusters of tiny air sacs.

**Urinary system.** The urine is secreted in the two kidneys, lying at the back of the abdominal cavity. From each kidney a tube, the ureter, carries the urine down to the bladder in the pelvis, the space between the hip bones; and it is discharged from there into the urethra. In the female this is a short channel, soon opening

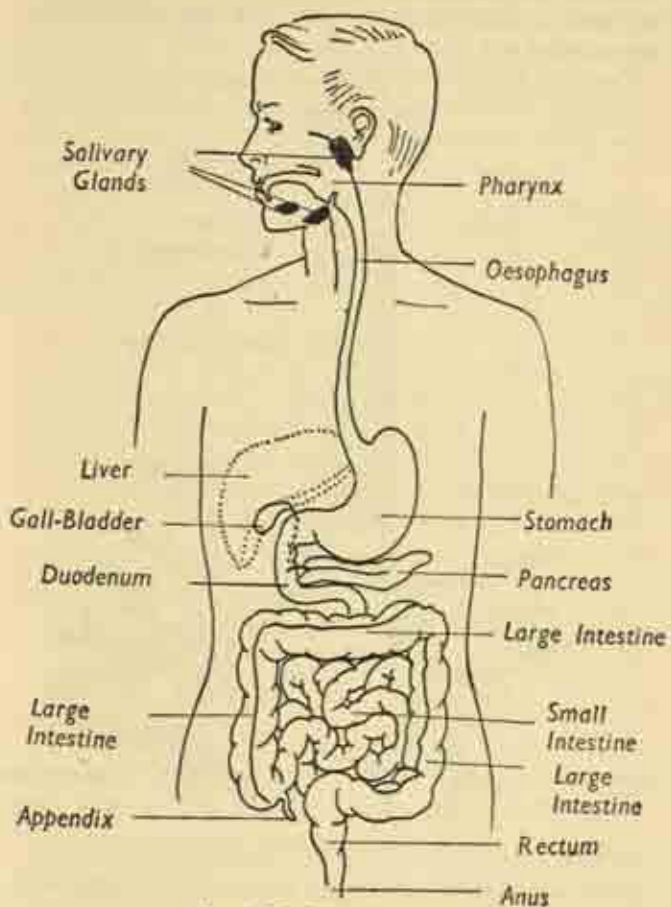


FIG. 4. The Digestive System.

externally; in the male it is a long curved pathway traversing the prostate gland, and then running through the penis, which is also used for performing the reproductive act.

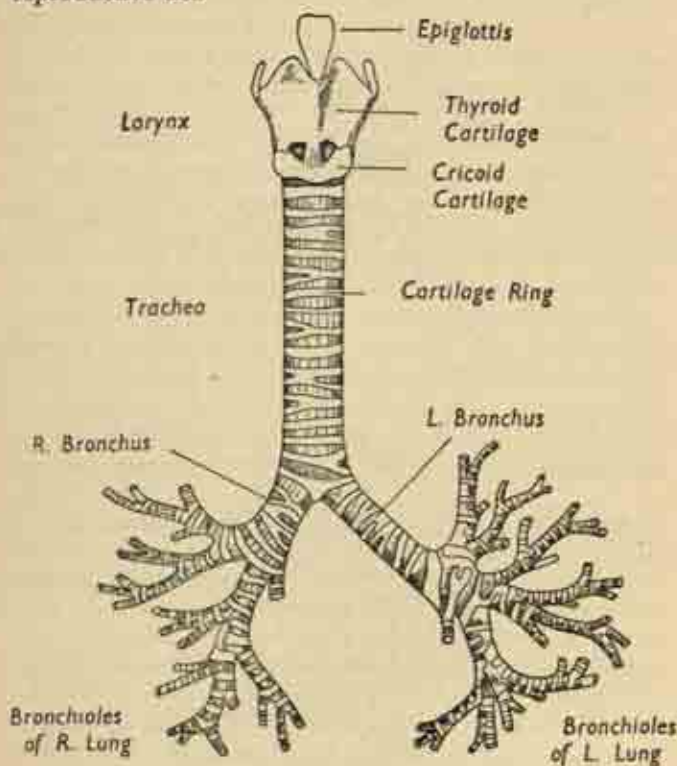


FIG. 5. The respiratory passages.

The associated genital or sex organs will be considered later (p. 281).

**Vascular system.** The circulatory system is essentially a closed circle round which the blood is propelled by the

contractions of the muscular heart. Blood is driven into the arteries, thick elastic tubes which aid by their recoil the distribution of blood to all parts. The arteries divide into smaller branches in their course to the organs and limbs, and finally break up into a meshwork of fine capillaries, microscopic thin-walled vessels which permeate every tissue of the body except the cornea of the eye and the outer layer of the skin.

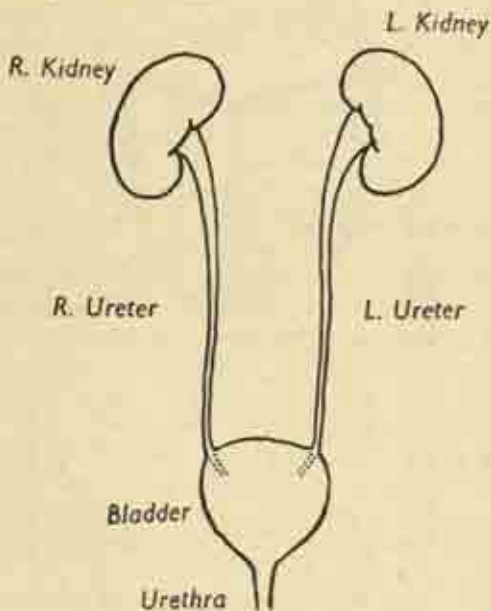


FIG. 6. The Urinary System.

The blood contained in the capillaries discharges oxygen and food materials to the tissue cells, and takes up carbon dioxide and wastes in return. The network reforms to form small veins, which become large venous trunks as they travel centrally towards the heart. These are thin-

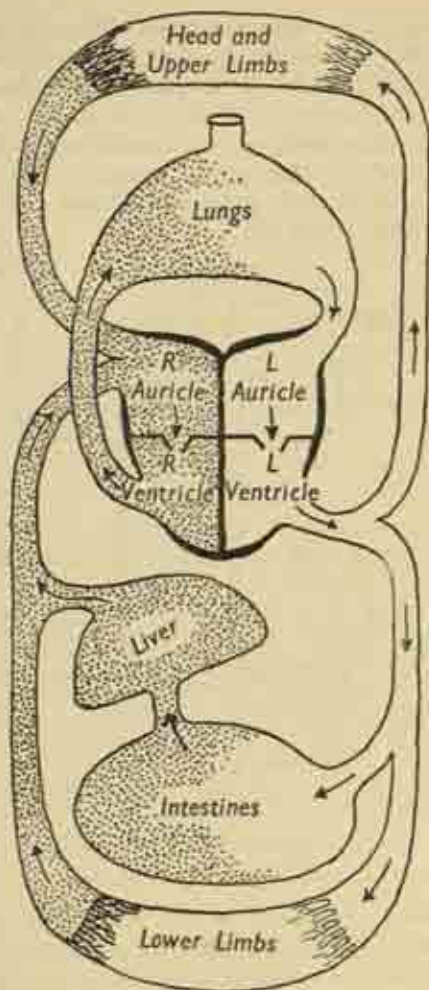


FIG. 7. A diagram of the Circulation of the Blood.

walled, have no pulse, and contain valves to prevent any backward flow of blood.

Now there are, in fact, two separate circulations; a *systemic*, concerned with the body as a whole and driven by the left side of the heart; and a *pulmonary*, concerned with the passage of blood through the lungs and driven by the right side of the heart.

The heart has a right and left side which are quite shut off from one another; and each side has an upper chamber or atrium<sup>1</sup> receiving blood from the great veins, and a lower chamber or ventricle discharging blood into the great arteries. Stale venous blood from the body enters the right atrium, passes to the right ventricle, and is expelled through the pulmonary artery to traverse the capillaries of the lungs. Here, it becomes aerated, receiving fresh oxygen from the air in the air-sacs and giving up carbon dioxide to be breathed out or expired. The fresh blood returns from the lungs in the pulmonary veins to the left atrium of the heart, then down to the left ventricle, and is discharged into the great artery of the body, the aorta, which supplies the head, trunk and limbs through its branches.

In the body tissues the blood is rendered dark and venous, and is ultimately collected up into great veins, the superior vena cava draining the head and arms, and the inferior vena cava draining the trunk and legs. Note that, whereas the arteries of the body contain bright red blood and the veins dark blood, the reverse is inevitably the case for the pulmonary arteries and veins; for the lungs are concerned with reversing the chemical states of the blood.

There is a special arrangement of the abdominal vessels which must also be noted. Whereas the veins leaving most structures pass directly to the heart, those from

<sup>1</sup> Sometimes called the *auricle*.

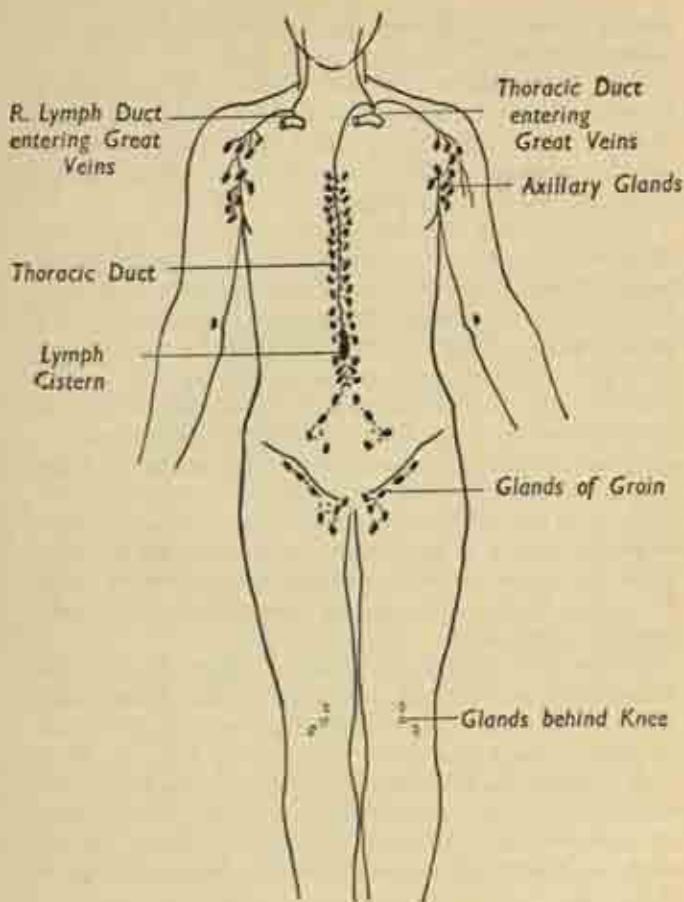


FIG. 8. The Lymphatic System.  
(The glands of the head and neck are not shown.)



the stomach and intestines enter another organ, the liver, where they break up into a second set of capillaries so that the blood is filtered through the liver before reaching the heart via the veins of the liver itself. This is to secure that the liver utilizes and stores the dissolved food substances carried by the blood from the bowel; the arrangement is known as the portal circulation.

**Lymphatic system.** This is a sort of accessory to the main vascular system. Not all the fluid portion of the blood which exudes into the tissues from the capillaries returns to these vessels, with the result that there is an accumulation of tissue fluids. This excess is removed by a separate set of fine channels, the lymphatics, which begin as clefts and crevices between the cells, and join up to form a plexus draining the various organs.

These vessels pass up the limbs and trunk and are interrupted at certain points by a number of gland-stations or filters which lie at the elbow and knee, armpit and groin, and in the trunk along the great blood vessels.

The lymphatics of the trunk join to form a wider vessel known as the thoracic duct, of matchstick thickness, which runs up in the chest to the left side of the neck; there it gathers the lymphatics of the left arm and the left side of head and neck, and discharges into the great veins. On the right side, the vessels of the arm, head and neck discharge directly into the veins.

One of the main functions of this system is the absorption of digested fat via the lymphatics of the bowel; and the lymph glands deal with any infection brought to them by the lymphatics.



## CHAPTER III

### CELLS AND TISSUES

#### Cells.

THE individual microscopic *cell* is the basis of life. The body is composed of different *tissues* which are aggregations of the same kind of cell, together with a considerable amount of intercellular substance. There is also much material produced by cellular activity but no longer living, e.g., the mineral content of bone, and the nails. The essential parts of the cell are its bounding membrane, the protoplasmic substance, and the central nucleus. All cells have sprung from the division of the female germ cell (ovum) after fertilization by the male germ cell (spermatozoon); and it is in order to ensure that the factors of inheritance, the genes, which control the behaviour of the cell in particular and the life of the body in general, should be shared out equally to new cells as they are formed that ordinary cell division is an extremely complicated process. It is called *mitosis*, and in it the essential elements of the nucleus, the chromosomes, split up to be divided between the two daughter cells. Each chromosome carries in it the genes, which are the determining factors in the inheritance of cell behaviour. Occasionally a cell and its nucleus just break into two, but this is uncommon.

The cells of different tissues may be greatly modified for their specialized functions, e.g., the red cell of the blood which has lost its nucleus, the white cell of the blood with a multilobular nucleus, the nerve cell with its enormously elongated axon-process or nerve fibre for

carrying stimuli, the striated or striped muscle (figs. 9, 11); but in each the essential components remain recognizable.

### Tissues.

There are only four essential *tissues*—epithelium, connective, muscular and nervous. These may be modified further in various ways but together they make up the body. They differ on the one hand in the nature of

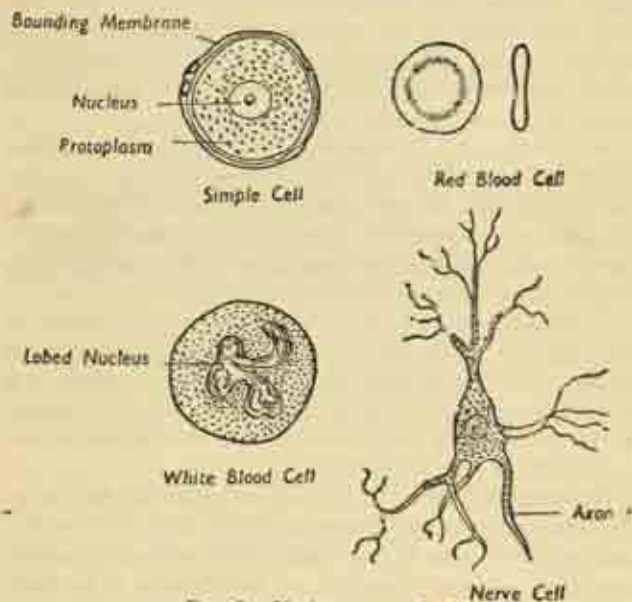


FIG. 9. Various types of cell.

their component cells, and on the other in the particular kind of secreted intercellular substance, the cell background or *matrix*.

**Epithelium.** This tissue covers all free body surfaces: not only the external surface of the skin but also the

internal surfaces, the linings of the body cavities, the glands opening into them, the vessels, and the respiratory, digestive, and genito-urinary tracts. It is important to realize that both internal and external surfaces of the body possess this intact "epithelial envelope" which is normally unbreached and stands as a barrier between the outside world (including paradoxically, the contents of the bowel and internal hollow organs) and the deeper muscular connective and nervous substance of the body. These internal and external linings become continuous with each other at the external orifices of the various cavities—at the lips, nose, anal and urethral openings—where the lining of the digestive, respiratory and urinary tracts become continuous with the skin.

An internal epithelium is called (i) a *serous lining* where it forms the smooth sheet-like boundary of a great body cavity (like the peritoneum, pleura or pericardium); (ii) a *mucous membrane* when it is a secreting glandular layer lining the bowel, mouth, glands, etc.; and (iii) an *endothelium* where it lines blood vessels.

Epithelium is typically very cellular and simple in arrangement, with little intercellular material and no blood vessels of its own, the cells being arranged in a single-layered mosaic, or in row on row (stratified epithelium). Most of the body pigment is formed in this tissue, e.g., in the skin, iris and retina.

**Connective tissue.** In its various forms this makes up the main supporting framework of the body as a whole, and of each organ in particular. It is characterized by the large amount of matrix or intercellular substance; and the exact nature of a connective tissue depends on the particular kind of matrix and of the fibres it may contain.

Thus in simple *areolar* tissue, the loose web-like packing in body clefts and spaces, between muscle and organs, and separating skin from deep structures, there is a semi-

fluid matrix containing both white (unyielding) and yellow (elastic) fibres; an arrangement allowing free gliding of part on part (fig. 10).

In *adipose* or fatty tissue the cells are modified to carry fat globules; it is found everywhere except within the skull cavity, but is most conspicuous beneath the skin and in the membranes within the abdominal cavity.

A predominance of fibres produces either ordinary fibrous tissue, with strong white fibres in parallel columns,

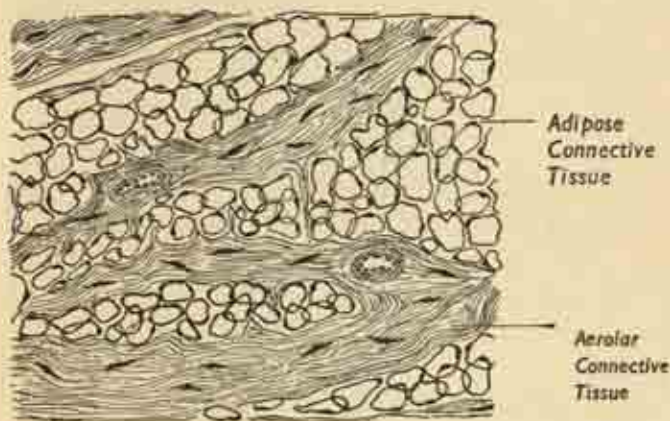


FIG. 10. A simple connective tissue.

as in tendons and ligaments; or elastic tissue, containing the resilient yellow fibres, important in such structures as the spinal ligaments and the walls of arteries.

In cartilage and bone the matrix has become solid and impregnated with mineral salts; they are described later. And in blood and lymph the matrix is completely fluid, while the cells have become modified, some to carry dissolved respiratory gases and nutrient substances, others to deal with invading micro-organisms.

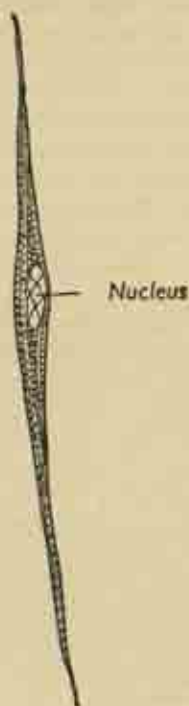


FIG. 11 (a). A smooth muscle fibre.

**Muscular tissue.** This is almost entirely composed of reddish muscle fibres arranged in bundles which are separated by areolar tissue. The fibres are highly specialized cells characterized by their great power of contraction on stimulation, an exaggeration of a property present to some extent in all protoplasm. There are three types, having rather different minute structure and fulfilling differing functions (fig. 11):—

- (i) *Smooth or plain muscle* (unstriated, involuntary or

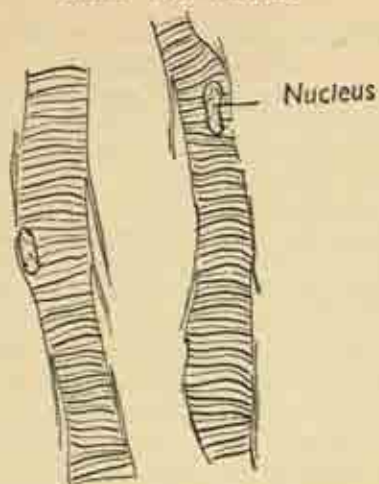
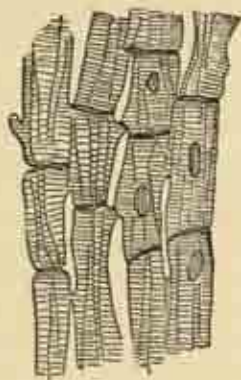

FIG. 11 (b). Striped muscle fibres. (After Gray).



*Cardiac Muscle*

FIG. 11 (c).



visceral) is the contractile material in blood-vessels and hollow internal muscular organs like the uterus, bowel and bladder; structures which must work automatically, beyond the conscious control of the central nervous system and regulated by the semi-independent autonomic or vegetative nervous system.

(ii) *In striped muscle* (skeletal, voluntary), the fibres are more intricate and are cross-striated under the microscope. They make up the muscles of locomotion and skeletal movement, and are under direct control by the conscious voluntary action of the central nervous system.

(iii) *Cardiac muscle* occupies an intermediate position, inasmuch as its fibres are striped although the action of the heart is not under voluntary control.

**Nervous tissue.** This is marked by the sensitivity of its cells to stimuli and the great conductivity of the fibres arising from these cells. Each cell has a number of small branching processes or dendrites which interlock with those of neighbouring cells; and one of these is elongated (often enormously, when traversing the length of a limb or the extent of the spinal cord) as the main axon for the transmission of stimuli. Cell, dendrites and axon make up the nerve unit or *neurone*, and the nervous system is built up of millions of these units in complex interrelation. Nerve fibres are grouped in bundles, both within the brain and spinal cord, and inside the main nerve trunks. They are of two kinds. The larger white or *medullated* fibres have an insulating fatty sheath and are found in the cranial and spinal nerve of the voluntary nervous system; the finer grey fibres are unsheathed or *non-medullated* and are found in the autonomic system. Damage to nerve tissue is irreparable in as much as the cells are incapable of reproduction, though injured fibres may grow again; but the functions of destroyed areas in the cortex of the brain may sometimes be assumed by the cells of other parts of the brain.



### **Body wall and body cavities ; somatic and visceral structures**

The body wall or *parietes* encloses the great cavities, abdomen and thorax, which are also named after their lining membranes as the peritoneal and pleural spaces. Essentially, the body wall is composed of the skeleton with its attached muscles and connective tissues and the overlying skin and fat : the parietal or somatic structures.

The *cavities*, with their smooth serous linings, contain the internal, visceral or splanchnic organs : the lungs and heart in the chest, intestines and other organs in the abdomen. The viscera have developed in the embryo from the posterior body wall and still retain this attachment in the adult, the lungs by their roots, the intestine by its double-layered, fat-laden, supporting mesentery. And we have already noted that the parietal skeletal muscles are under the control of the will, while those of the viscera function unconsciously and are largely independent of the central nervous system.

### **The body covering : skin and fasciae**

#### **Skin.**

The skin covers the body and is continuous with the linings of the internal canals at their various orifices. It is highly elastic, and mobile on the deeper structures except where tightly bound down on the scalp, ears, palms and soles. On its surface open the hair follicles, sweat and sebaceous glands; and its brown melanin pigment is most developed on exposed sites and at the genital and nipple areas. It contains the peripheral endings of sensory nerves, acts as an excretory agent through its glands, and helps to regulate body temperature through the rate of water loss by evaporation. It is also protective, and is modified at certain sites to form the hair and nails.

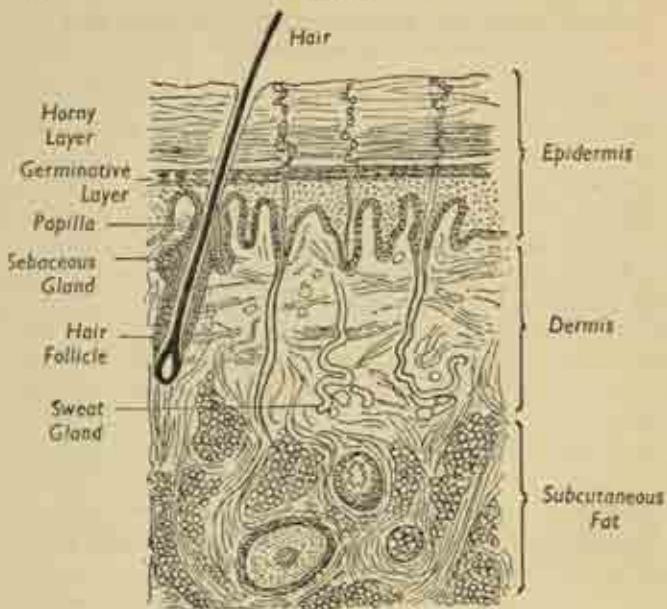


FIG. 12. Section through the skin to show its layers.

Microscopically, the skin has two main zones. (i) The superficial *epidermis*, which varies in thickness, greatest in the palms and soles, and is permanently creased opposite the flexures of joints. It has an outer horny layer of dead or dying flattened cells being continually shed as scales by friction, and is continually renewed by the growth of the *germinative layer*.

(ii) The deeper *dermis*, or true skin, is a layer of tough elastic and fibrous connective tissue intervening between the epidermis and the subcutaneous fat; it is this layer in animals which is converted into leather. Unlike the epidermis it is highly vascular, and projects into the deep aspect of the latter in little bays or papillæ which contain the terminal capillary loops, and the end-bulbs of

the sensory nerves which carry impressions of touch, pain, heat and cold from the overlying surface. Although the hair follicles, sweat and sebaceous glands actually lie in the dermis, they have developed by ingrowth from the epidermis; so that the hair-shafts and the ducts of the sweat glands traverse the latter to reach the surface. The sebaceous glands open alongside the hairs to ensure their lubrication.

The elastic tissue of the dermis is so arranged as to produce definite planes of cleavage, varying in direction in different parts of the body. Thus, in the anterior abdominal wall the natural skin cleavage is roughly transverse so that an operative incision in this line is under little tension and gapes only slightly; while a longitudinal incision at right angles to this is pulled open by skin tension and is much more difficult to close.

### **Fasciae.**

Intervening between the skin and the muscles which clothe the bones of the skeleton are two important layers of connective tissue, the superficial and the deep fascia.

The *superficial fascia*, the ordinary subcutaneous fat, is a continuous sheet over the whole body and is everywhere fatty, save at the eyelids and over the male genitals. In one or two sites it contains muscle fibres such as the muscles of facial expression and the dartos muscle which corrugates the scrotum. Fat is more developed in the abdomen, breast and buttocks, and thicker in women than in men. It insulates the body, so retaining warmth; and it also contains the cutaneous nerves and vessels on their way to and from the skin.

Internal to the superficial fascia is the *deep fascia*, a tough white fibrous sheet of membrane covering and partitioning the various muscles, and in close relation to bones and ligaments, with attachment to the subcutaneous bony prominences. From its deep surface other

sheets or septa extend inwards between the muscle groups, forming sheaths for nerves and vessels and compartments for the viscera. In various situations it is modified as restraining bands or *retinacula* to hold down tendons; as *synovial sheaths* to facilitate the smooth gliding of tendons; and as *bursæ*—simple closed synovial sacs over points of friction and compression, as between skin and bony points, and between tendon and bone.

The general arrangement of fasciæ is seen most clearly in the cross section of a limb (fig. 50). Here we have in succession, from without inwards: the skin; superficial fascia; and the deep fascia enclosing the muscle masses of the limb in a continuous restraining envelope, and sending between them intermuscular septa which separate the various groups and reach the bone.

### Muscles, tendons, aponeuroses

We have already noted the three main types of muscle tissue—voluntary, involuntary and cardiac. Here we deal only with the voluntary or skeletal muscle, the flesh of the body, making up some 40 per cent. of its weight; and divided into the *axial* muscles connected with trunk, head and neck, and the *appendicular* muscles of the limbs. The separate fibres are bound in bundles by connective tissue, and these in turn are bound into larger bundles to compose the individual muscle, with its sheath derived from the deep fascia.

**Attachments.** Muscles are usually attached to bone or cartilage, sometimes to ligaments or skin, and these attachments are either directly by muscle fibres or by an intervening tendon, a sinew or "leader," a tough inelastic cord-like structure of white fibrous tissue. Most muscles have a tendon at one or both ends; and wide flat muscles have broad sheet-like tendon expansions or aponeuroses, e.g., those of the flank abdominal muscles, which extend from lower rib to pelvis. When a muscle contracts



one attachment remains fixed—the *origin*—and the other, the *insertion*, is moved towards it; and generally, in the limbs, the origin is proximal and the insertion distal, while in the trunk the origin is medial and the insertion lateral. But origin and insertion are sometimes interchangeable with circumstances. Thus, the normal action of the pectoralis major, inserted into the humerus, is to approximate (adduct) the arm to the side of the chest. But, if the arm is fixed by gripping a table, the same muscle can be used to pull on the ribs at its origin, expanding the thoracic cavity as an accessory muscle of respiration, an action commonly performed in asthmatic attacks, when breathing becomes difficult.

Attachments are usually just distal to the joint moved, e.g., the biceps into the upper radius just beyond the elbow, an arrangement rather inefficient mechanically but allowing great speed of action. A muscle may have two or even three heads of origin (cf. the biceps and triceps in the arm), but its insertion is nearly always single. Tendinous attachments to bone produce a local ridged elevation of bony substance, while direct muscular insertion leaves the bone quite smooth. Occasionally muscles are attached to each other, usually a symmetrical arrangement between a pair on opposite sides of the midline; thus the fibres of the mylohyoids under the chin criss-cross at a line of junction (called the median raphe) while the aponeurotic fibres of the abdominal muscles interlace in herring-bone fashion at the mid-line of the abdominal wall. A few muscles have two separate bellies connected by an intermediate tendon, the object being a redirection of pull secured by the binding down of the tendon to a neighbouring bone by a band of deep fascia.

The *form* of a muscle depends on the arrangement of its fibres. When these have a direct pull, the muscle may be fusiform (with a definite belly tapering above and below), strap-like, quadrilateral or triangular (fig. 13).

But more power is obtainable when the fibres are inserted indirectly into tendinous prolongations within the muscle substance, for then a greater concentration of short efficient fibres is possible, as in the unipennate, bipennate and multipennate arrangements shown.

Muscles are *named* mainly after their attachments and actions, e.g., the flexor pollicis longus—the long flexor of

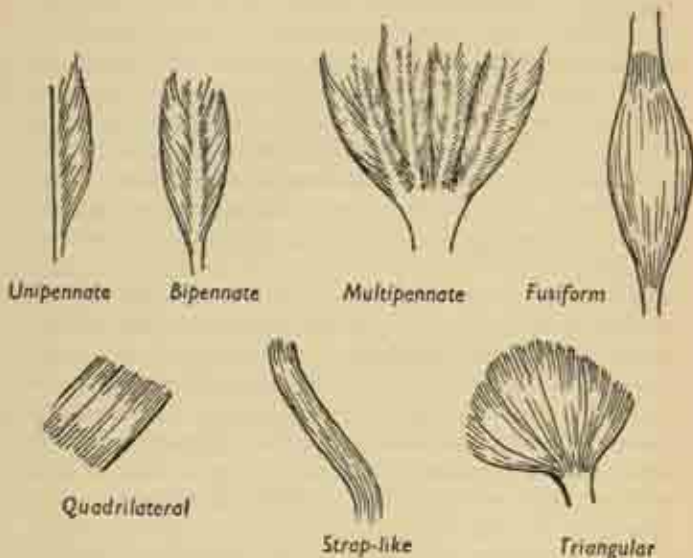


FIG. 13. Variations in the form of muscles and the arrangement of their fibres.

the thumb; occasionally by shape, e.g., pronator quadratus, the square muscle pronating the forearm; or by some other features, e.g., the quadriceps with four heads of origin. Muscles show considerable variation in their exact anatomical arrangement, often having additional slips of origin or being altogether absent. Their blood supply is extremely rich, owing to the greatly increased

demands for oxygen made during contraction; and they receive branches from one or more nerves carrying two kinds of nerve fibre—motor, carrying the stimuli to contraction; and sensory, conveying to the brain the sense of position and the degree of contraction and tone which are essential to co-ordinated function.

### Muscle contraction, tonus, posture

An individual fibre contracts by some 50-60 per cent. of its fully-stretched length, and either contracts this maximal amount or not at all—the “all-or-none” law; but not all the fibres of a muscle necessarily act at the same time, the proportion being dependent on the actual work to be done. Muscle action moves the joint or joints lying between the origin and insertion, and this is clear enough when done against resistance or against the mere weight of the limb. But even when a movement is assisted by gravity, as when the arm is dropped to the side, there is a *controlled* relaxation, in this case of the arm-lifting muscles, which is really a continuous readjustment of their degree of contraction, i.e., “relaxation” is an active process. The ordinary contraction, which approximates origin and insertion freely, is called *isotonic* since the tension remains fairly constant throughout; if the attachments are kept separated by some resistance, the muscle cannot shorten and its tension rises greatly, an *isometric* contraction of constant length. And since most contractions are performed against some degree of resistance, they are usually at least partly isometric.

Living muscle is never completely relaxed except under deep anaesthesia, but always in slight contraction called *tonus*. The state of the fibres is best expressed by the analogy of a pianist continuously rippling over the notes of a piano; some notes are always being struck at a given moment but they are always changing. Tonus is



essential to the maintenance of posture, especially the erect posture of man, as it holds the body against the collapsing strain of its own weight, particularly the feet and legs, whose ligaments would be subject to enormous deforming stresses if it were not for the constant guarding tone of the surrounding muscles. And the spinal column is not a straight rod but a series of curves from above downwards, the general shape being maintained by the long spinal muscles which form the chords of these arcs. Essentially, postural reflexes in the erect position are devoted to the preservation of an upright, forward-looking head; and a complex reciprocal action of all the main groups of muscles in calves, thighs, buttocks, spine and neck exists to secure this end. Hence the necessity of *sensory* nerve fibres from the muscles, telegraphing the exact state of tension from moment to moment to the central nervous system.

### Muscle groups and movements

Muscles are usually associated in groups with the same nerve supply, acting to perform common or related actions. It is this movement, and not the individual muscle, that is represented in the cerebral cortex as such, and no individual muscle can be contracted by an act of will. We try to lift our arm, *not* to contract our deltoid (though this is the main muscle concerned) and a whole host of associated muscles come into play, many of them beyond the fringe of consciousness. In its relation to a particular movement an individual muscle may fill one of the following rôles:

(i) the *prime mover*, directly responsible for the actual movement;

(ii) the *antagonist*, which is capable of causing the reverse motion and therefore has to relax reciprocally as the prime mover contracts, actively paying out just as much slack as is necessary to let the latter do its job;

(iii) the *fixators*, associated muscles steadying the base or fulcrum against which the prime mover acts. Thus the head of the humerus is unstable in the shoulder joint, and the deltoid muscle can only efficiently lift up the arm if the bone is held firmly against its socket by a group of small muscles arising from the scapula;

(iv) the *synergists*, which act by controlling an intermediate joint so that the prime mover may act with maximal efficiency. Thus the flexors of the fingers can only produce a powerful grip while the wrist is bent back (dorsiflexed) by the wrist extensors acting as synergists. If this is not done, the finger flexors waste their power in bending the wrist forwards (palmarflexion) and there is less force available to move the fingers. Try this for yourself.

And, of course, in connexion with different movements the same muscle may play different parts.

## CHAPTER IV

### CARTILAGE AND BONE: THE SKELETON; JOINTS

**Cartilage** is a connective tissue whose matrix has become solidified, embedding little groups of dispersed cartilage cells. It is non-vascular, gristly and easily cut; and it is utilised where rigidity and resiliency are needed in combination, i.e., in the joint surfaces, the anterior ends of the ribs, and in the framework of trachea and bronchi, nose and ears.

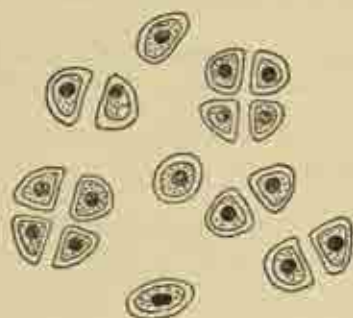


FIG. 14. Cartilage cells.

In the developing foetus the skeleton is entirely cartilaginous at one time, until this is largely replaced by bone. This ossification process is initiated by the impregnation of cartilage with calcium salts, but calcification does not normally occur in adult cartilage except in senile degeneration, when it becomes brittle. Because of its lack of blood supply, cartilage cannot repair itself as such after an injury, being replaced by fibrous scar tissue; hence the disabling effects on the smooth working of joints of an injury to their articulating surfaces.

The main types of cartilage are : (i) the smooth clear *hyaline* cartilage of joint surfaces; (ii) the tough *fibro-cartilage*, containing white fibrous tissue, found in the intervertebral discs and in the plates or menisci which project into certain joints (e.g., the semilunar cartilages of the knee); (iii) *elastic* cartilage in flapping structures like the ear and epiglottis.

### Bone

This is the hardest body tissue with the exception of the teeth, an intimate blending of organic fibro-cellular substance and inorganic mineral salts—calcium phosphate and carbonate, magnesium and fluorides. The *organic*

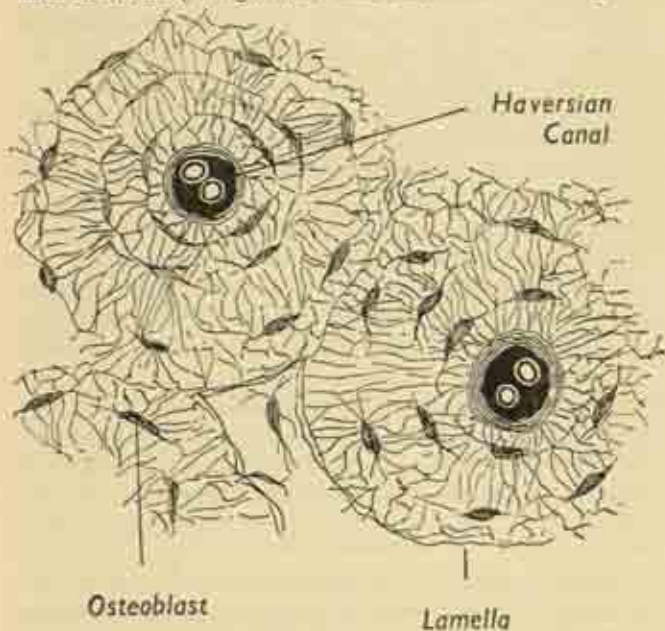


FIG. 15. Microscopic structure of bone.

part consists of fibrous tissue with numerous bone cells or corpuscles (*osteoblasts*), its ground substance impregnated with mineral matter; it can be removed by burning, leaving a brittle mineral skeleton. The *inorganic* matter is easily dissolved by acid, and the decalcified bone retains its shape but is perfectly flexible and can be bent or even tied in knots.

Microscopically, the bone substance is arranged in layers or lamellæ containing small clefts or lacunæ, occupied in life by the osteoblasts whose processes ramify around. The lamellæ are arranged concentrically around a central Haversian canal containing small vessels and nerves; and the bone as a whole is composed of very many such Haversian systems. This is modified near the surface of the shaft, where the lamellæ are parallel and there are no canals.

The *periosteum* is a tough supporting fibrous membrane surrounding the bone, and closely attached to it by deep fibres penetrating its substance. Its outer layer is purely supporting, but there are bone-forming cells on its deep aspect responsible for increase in girth of the bone during growth. Bone receives its blood-vessels via the periosteum so that its nutrition is largely dependent on the latter's integrity; if it is stripped up by the formation of pus beneath its infection, much of the bone shaft may die.

The general *functions* of bone include the framework and support of the body; protection of internal organs; attachment for tendons and muscles; and formation of the cells of the blood in the bone marrow.

### **Types of Bone**

In gross appearance, there are four main types of bone. (i) *Long bones* are those of the limbs, e.g., the humerus in the arm, femur in the thigh. They have a shaft which is roughly cylindrical, but sometimes polygonal or tri-



angular in section, and never quite straight; and two expanded ends, sometimes rounded off as a definite head, or widened into condylar masses. The bone ends are articular, take part in the adjacent joints, and covered with smooth articular cartilage to facilitate movement; the two ends concerned in forming a joint are enclosed in a common joint capsule. Thus the periosteum covering the shaft becomes continuous with the capsule at the end of the bone (fig. 16(b)). The bone surface is dotted with numerous tiny apertures (*foramina*) for its blood-vessels, with a larger nutrient foramen for the main artery near the mid-shaft. The ends receive a double blood supply, both from the main shaft and from neighbouring vessels.

Cross-section of a long bone shows the outer *cortex* of bony substance and the central *medullary cavity*. The cortex has an outer portion of dense compact bone, surrounding a looser meshwork of spongy or cancellous bone; and at the ends, where the medullary cavity stops after traversing the shaft, there is a solid mass of spongy bone within a thin compact shell (fig. 16(a)).

Fatty *yellow marrow* occupies the medullary cavity in the adult, and the interstices of the spongy bone at the ends are filled with *red marrow*, responsible for the formation of red and white blood corpuscles. At birth, and in the early years of life, red marrow occupies the whole shaft but retreats to the ends with growth; and this process can be reversed in later life if anæmia or hæmorrhage make extra demands on blood formation, so that in chronic anæmia the shafts of all the bones are permanently occupied with red marrow working overtime.

(ii) *Short long-bones* are simply long bones in miniature, and are found in the hands and feet.

(iii) *Short bones* are squat, cuboidal or irregular, composed entirely of spongy bone with a thin compact shell.

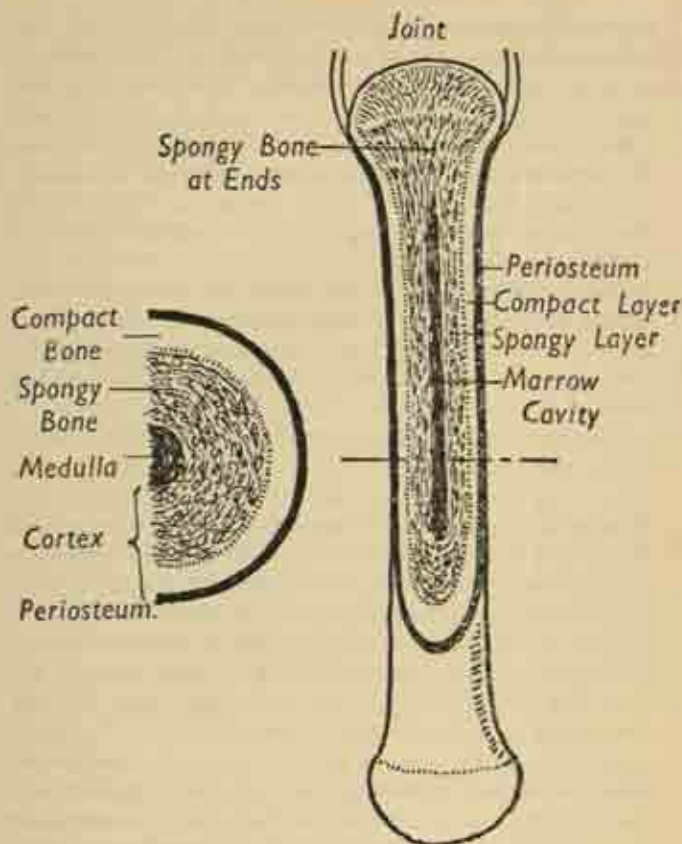


FIG. 16 (a). Cross-section of a long bone.

(b) Longitudinal section of a long bone.

They occur in the wrist (*carpus*), the corresponding part of the foot (*tarsus*) and in the vertebræ.

(iv) *Flat bones* are those of the skull, vault, ribs and scapula (shoulder blade). They consist of two plates of compact bone sandwiching a thin spongy layer; these



layers in the skull are called the inner and outer tables, with the diploë between. Certain bones of the skull are expanded by air-containing cavities replacing this spongy layer—the air sinuses.

Finally, *sesamoid bones* are tiny rounded masses found in certain tendons at points of friction; the largest is the patella at the knee (knee-cap).

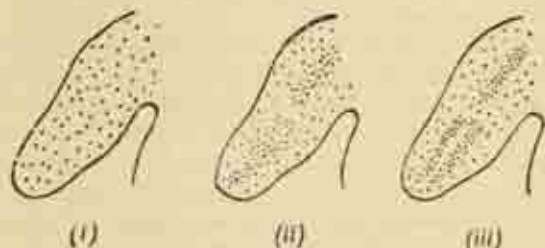


FIG. 17. Stages in demarcation of the future bones in a developing limb-bud.

### Development and growth of bone

In the developing embryo of a few weeks the central core of the primitive gelatinous connective tissue of the limb-buds becomes transformed into an axial rod of cartilage traversing the limb. This rod is absorbed at the sites of the future joints, e.g., the elbow and knee, demarcating arm from forearm and thigh from leg; and split longitudinally in two in the distal segment as the fore-runner of the paired radius and ulna, or tibia and fibula. With certain exceptions, the whole skeleton is well formed in cartilage by the 6th week, and at the 7th week a centre of ossification develops in the mid-shaft of each long bone. Bone cells appear, the matrix is impregnated with calcium salts, and ossification spreads up and down the shaft until at birth the long bones are entirely ossified except for their cartilaginous ends.

### Epiphyses.

There now develops an arrangement, peculiar to mammals, allowing continuous growth in length during the years preceding maturity. In the first years of life separate secondary centres of ossification appear in the bone-ends, which ossify completely except for a thin cartilage plate separating them from the main shaft. The rounded end is called the *epiphysis* and the cartilaginous plate the epiphyseal plate. This plate consist of longitudinal columns of cartilage cells reproducing themselves continuously on the shaft side of the plate, and as continuously turned into new bone which is pushed away into the main shaft, enabling it to grow into length. Meanwhile the epiphyseal plate retains its integrity, until at maturity the epiphysis fuses with the shaft by ossifying directly across the intervening cartilage—at 18-20 in men, 16-18 in women. During all this time, as we have seen, the periosteum has been responsible for increase in girth (fig. 18).

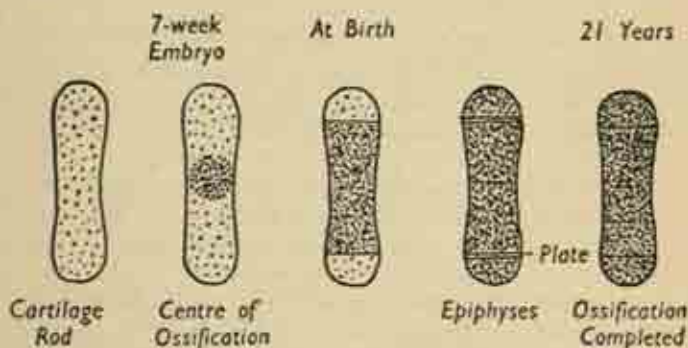


FIG. 18. Stages in the ossification of a long bone.

### Growing ends.

Though each end of a long bone is thus a growing end, one epiphysis appears earlier than the other and fuses

later, and is responsible for the main share in growth in length. In the arm, these principal "growing points" are at the shoulder end of the humerus and the wrist end of radius and ulna; in the leg, at the knee end of all three bones. It is for this reason that amputation through the thigh gives rise to no trouble in a child, whereas in the corresponding amputation through the upper arm the humerus continues to grow from the shoulder and may burst through the stump unless its epiphysis is deliberately destroyed surgically. Complete destruction of an epiphysis causes cessation of growth and corresponding stunting; partial destruction by injury or disease causes a distortion of growth in which the limb turns away from the still active side.

A few bones, mainly those of the skull vault, mandible and clavicle, are not pre-formed in cartilage as described above, but are ossified directly in primitive membranous tissue, and these membranous bones have no epiphyses.

### Factors controlling bone growth

There is an intimate control of bone growth and of its mineral metabolism by certain special glands, the endocrine glands, as well as by certain vitamins of the food. Excess secretion of the anterior lobe of the *pituitary* gland in childhood so stimulates epiphyseal growth as to cause gigantism; its action in the adult is less dramatic, but even here gross hypertrophy and thickening of the skeleton occur. In congenital deficiency of the *thyroid* gland (cretinism) the reverse is the case, and stunting accompanies the idiocy; the epiphyses are delayed in appearance and still unfused in middle age. And infantile rickets (due to lack of vitamin D) grossly distorts normal ossification and growth at the epiphyseal plates, with resultant deformity.

There is a constant interchange-equilibrium between the calcium phosphate of bone and the dissolved calcium

and phosphorus of the blood stream. This is regulated by vitamin-D intake, shortage of which causes rickets in the infant and skeletal rarefaction in the adult; and by the activity of the *parathyroid* glands, whose overaction causes general rarefaction and cyst-formation in the bones, with deformity and spontaneous fracture.

The strong hard bones of the dried skeleton obscure from us their essential plasticity during life, for they respond to normal and pathological stresses much as a tree responds slowly but surely to the deforming influence of wind and weather. The more work put on them, the more they hypertrophy, particularly in response to compression strain or muscular pull; and the internal arrangement of bone trabeculae is a purely mechanical solution to the engineering problems imposed on each bone. In view of this exact correspondence between final shape and functional needs, it is somewhat remarkable to find an inherent tendency to assume the exact adult shape, even in a bone removed from the growing embryo and left to develop alone in an artificial culture medium.

## Joins and Movements

### Types of Joint.

The articulations between the bones vary considerably in different parts of the skeleton in their mobility, and some are quite immobile. Main types of articulation are :

(i) *Fibrous*. Either as a *suture* between the skull bones, (fig. 20(b)) whose interlocking irregularities are joined by a thin fibrous strand, often obliterated by ossification in old age; or between paired bones in the form of a broad sheet of *interosseous membrane*, e.g., radius and ulna.

(ii) *Cartilaginous*. As in the thick fibro-cartilaginous cushion separating the two halves of the pelvis in the front at the pubic symphysis, or intervening as an inter-vertebral disc between the constituent vertebrae of the spinal column.

(iii) *Synovial* joints which allow free movement (fig. 19).

In synovial joints the bone ends are capped with smooth *articular cartilage* and the joint cavity is enclosed within the sleeve formed by the *capsule* attached to the two constituent bone ends. This capsule is lined by

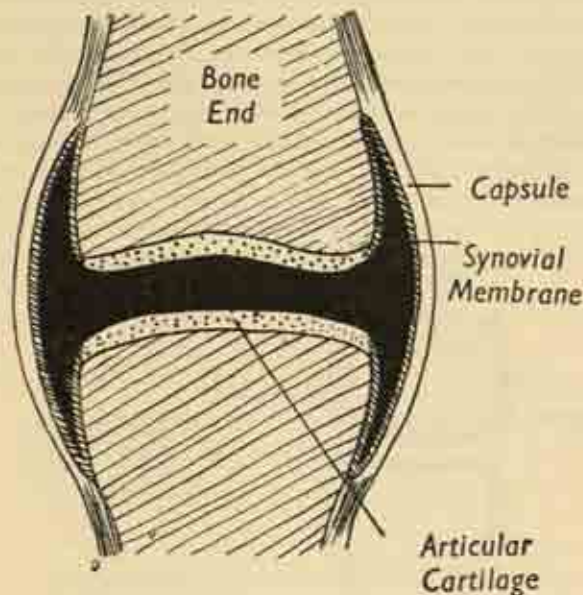


FIG. 19. A Synovial Joint.

*synovial membrane*, which is reflected on to the bones but disappears at the periphery of the articular surface. The highly vascular, fatty membrane, with its villous fringes, secretes the lubricant *synovial fluid* which covers the joint surfaces in a thin film. And any structure traversing the joint, such as a ligament or tendon passing through the capsule, carries an investing sheath of the



synovial membrane. Normally the joint space remains only potential and non-existent, as the cartilage surfaces and soft tissues lie in contact under a negative pressure; it becomes a reality when the capsule is distended by fluid effusion in inflammation, or if air is admitted by wound or operation.

*Ligaments* of strong white fibrous tissue hold the bone ends together; foremost of these is the main capsular ligament, and in addition there may be localized bands running in the capsule, and accessory ligaments traversing the joint cavity or quite outside the joint altogether. Tendons arising within a joint obviously also function as accessory ligaments, e.g., the long head of the biceps in the shoulder.

In some cases, complete or incomplete cartilage plates or discs project into the joint cavity as partitions, attached

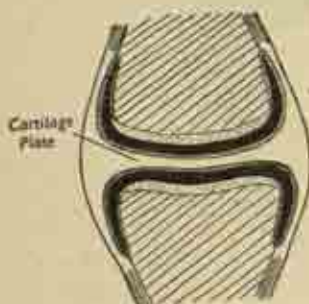


FIG. 20 (a). Synovial joint partitioned by a cartilage plate.



FIG. 20 (b). Suture.

peripherally to the capsule; these occur at either end of the clavicle, between the lower jaw and the skull (temporo-mandibular joint) and at the knee, the semilunar cartilages so often torn in footballers (fig. 20(a)).

### Stability.

The general integrity and coaptation of joints are

maintained by a number of factors, the most important being the strength of the ligaments and the tone of surrounding muscles; these are inter-related, as muscle tone normally prevents a severe strain on the ligaments being more than momentary. Great mobility is essential at the shoulder, so the capsule is lax, and the large humeral head fits poorly into the shallow glenoid fossa of the scapula; this inherent instability is overcome by having the tendons of the small rotator muscles blend freely with the capsule so that the anatomical deficiency is compensated by muscle guarding. This contrasts with the arrangements at the hip where stability is of greater importance; here the femoral head is deeply buried in the socket of the acetabulum, and an intimate blending of the neighbouring muscles with the capsule is unnecessary.

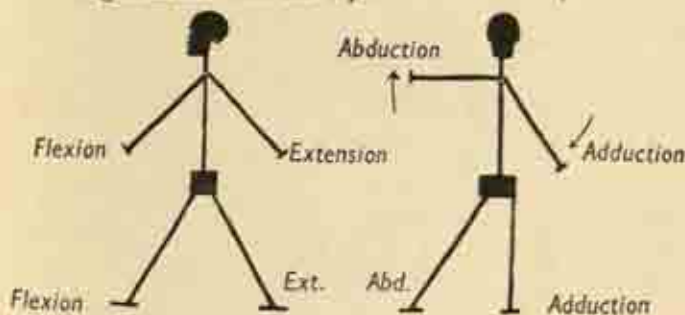


FIG. 21. Movements of the ball-and-socket joints of shoulder and hip.

Minor supportive factors are the interlocking of the bone ends, rarely very secure in itself; and the cohesion produced by outside atmospheric pressure.

### Varieties of Synovial Joints.

Synovial joints are further subdivided in virtue of the shape of their bone ends and the movements possible between them.

The simple *plane* joint between the small flat adjacent



surfaces of carpal and tarsal bones allows minor gliding motion only. The *saddle* joint is self-explanatory, with reciprocating saddle-shaped surfaces, the best example between the thumb metacarpal and the corresponding carpal bone. The *hinge* joint is a common mechanism, as in the elbow, ankle and fingers; here, one convex surface is gripped within a deep concavity and the very strong collateral ligaments on each side allow motion round a transverse axis only. On the other hand, the capsule obviously needs to be very lax in front and behind to allow full flexion and extension. The *pivot*

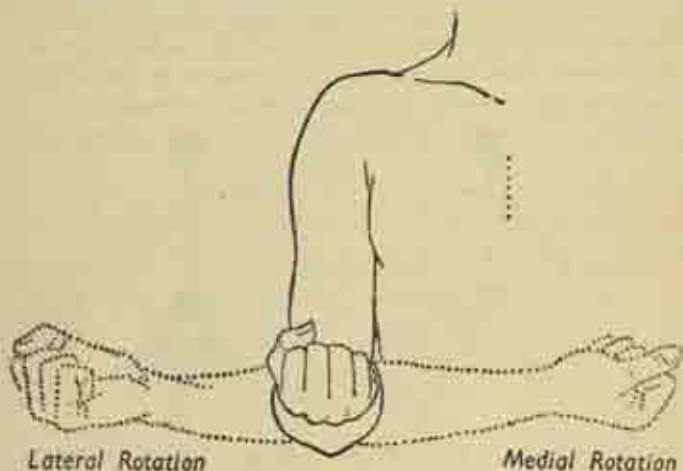


FIG. 22. Rotation at the shoulder.

joint is again obvious, with a cylindrical bone end rotating in its long axis like a hinge within its socket, e.g., the head of the radius at the superior (proximal) radio-ulnar joint in pronation and supination of the forearm.

The *ball-and-socket* joint of shoulder and hip has the most highly developed range of motion, with one spheroidal and one concave surface moving on each other

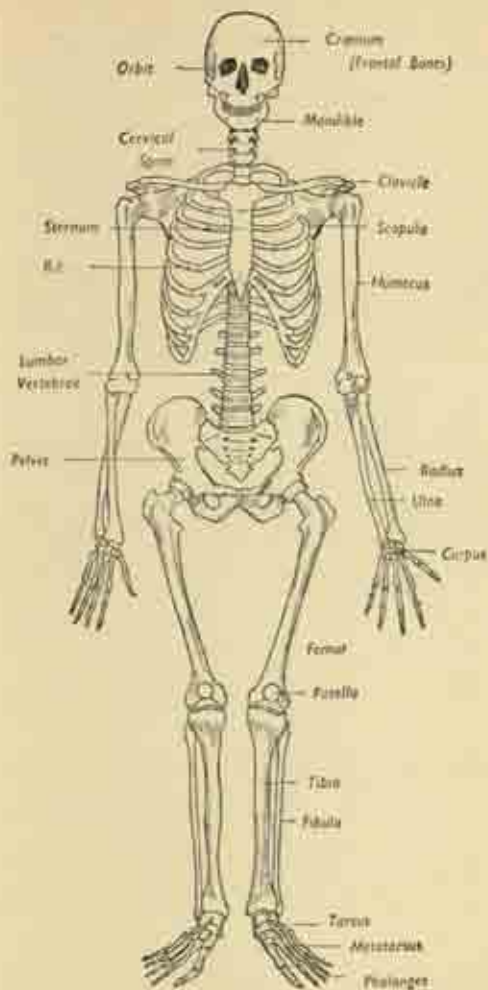


FIG. 23. The Skeleton, anterior view.

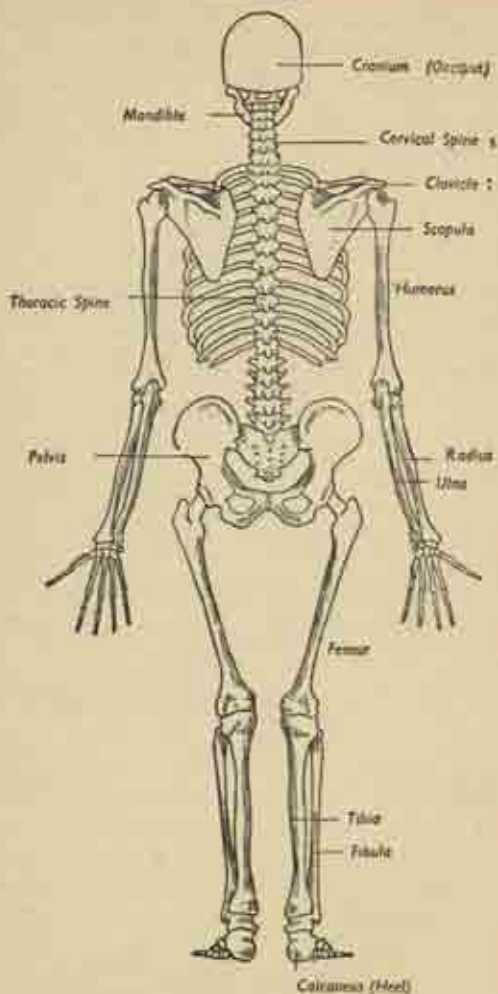


FIG. 24. The Skeleton, posterior view.

round an infinite number of possible axes. Its main movements are best shown diagrammatically:

*Flexion and extension* in an antero-posterior plane; *abduction and adduction* in a medio-lateral plane; *medial and lateral rotation* on the long axis of the limbs (not to be confused with pronation and supination of the forearm in the upper limb, where true rotation occurs only at the shoulder joint); and *circumduction* in which the limb describes the boundary of a cone, in a combination of all the above.

The movements of joints are rarely as extensive as the shape of the bone ends would seem to allow, i.e., actual locking of the bones is only exceptionally a limiting factor. It is the soft parts that are usually responsible for checking the range, as in the contact of the front of arm and forearm in flexion of the elbow, and the tension of the hamstring muscles at the back of the thigh in limiting flexion of the hip.

### Axial and appendicular skeleton: limb girdles

The skeleton as a whole is divided into the central *axial* portion of the head and trunk, and the peripheral *appendicular* portion of the limb-bones. The axial skeleton is made up of the skull, mandible (lower jaw), spine, sternum (breast-bone) and 12 pairs of ribs; and there are in addition the small hyoid bone in the upper part of the neck beneath the floor of the mouth, and three tiny ossicles in each middle-ear cavity.

**Limb Girdles.** These are encircling arrangements of bones designed to connect the shoulder and hip regions to the central axial skeleton in such a way as to provide a more or less firm basis of attachment for the corresponding limb, while allowing a certain degree of mobility. The two girdles differ somewhat in respect of these two functions. The arm does not have to bear

weight and must allow the freest use to be made of the hand; the shoulder girdle is correspondingly unstable and its main central connections are muscular rather than bony. These conditions are reversed at the hip, where stability is essential, and here the pelvic bones make up a stout complete bony ring, firmly attached to the spine behind (fig. 25).

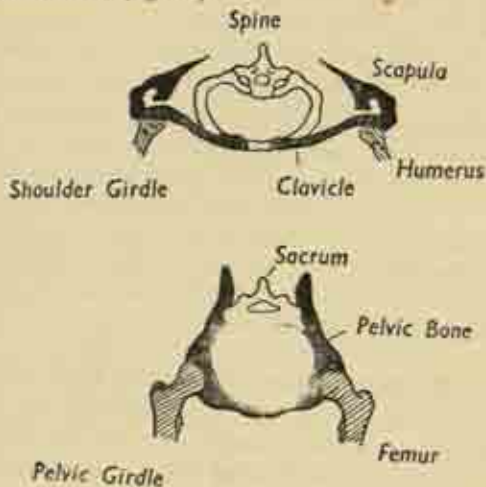


FIG. 25. The Limb Girdles.

In the diagrammatic sections of the two girdles, the following points will be noted. They are both based on a circular model but the shoulder girdle is very wide, and is left open behind where the scapulae are only attached to the spine by muscle, so that they can move freely on the trunk. Each half of the shoulder girdle is made up of two bones—scapula and clavicle—the latter a relatively slender bone joining scapula to sternum and responsible for bearing a considerable part of the burden of the hanging arm. Halfway round the girdle on each side is the

shallow glenoid fossa of the scapula, accommodating the humeral head at the shoulder joint.

In the hip girdle, the bony ring is complete in front and behind in a tight circle. Each half is composed of a single pelvic (innominate) bone carrying a very deep acetabular socket for the head of the femur at the hip joint; and posteriorly the two pelvic bones are firmly attached to the spine, in this region the sacrum, at the sacro-iliac joints. The girdle is thus integrated with the axial skeleton and does not permit of any accessory leg movements other than those taking place at the hip itself.



## CHAPTER V

### THE ARM

#### Bones of the Upper Limb

##### Shoulder.

THIS region is made up of the rounded *shoulder-cap*, the prominence formed by the head of the humerus and the overhanging acromion process of the scapula; it also includes the *scapular* region behind, over the shoulder blade, the *pectoral* region or front of the upper part of the chest below the clavicle, and the *axilla* or armpit intervening between the two. We have seen that the shoulder-girdle is made up of scapula and clavicle, articulating at the acromio-clavicular joint; and the medial end of the clavicle articulates with the sternum at the sterno-clavicular joint.

The *scapula* itself consists of the main *body* or blade, a thin triangular plate or bone carrying certain local elevations or processes. The body has superior, medial (vertebral) and lateral (axillary) *borders*, with a superior and inferior *angle* at either end of the medial border. But where the corresponding lateral angle would be expected, at the junction of lateral and superior borders, there is the expanded thickened mass of the *head* of the scapula, hollowed out on its lateral aspect to form the shallow *glenoid fossa*. The deep (anterior) surface of the bone is slightly concave and is applied to the backs of the upper ribs; the superficial (posterior) surface carries a prominent ridge, the spinous process, which runs up and out from its root on the medial border to end as a broad lozenge-shaped expansion, the *acromion process*, overlying the shoulder joint. Lastly there is the short

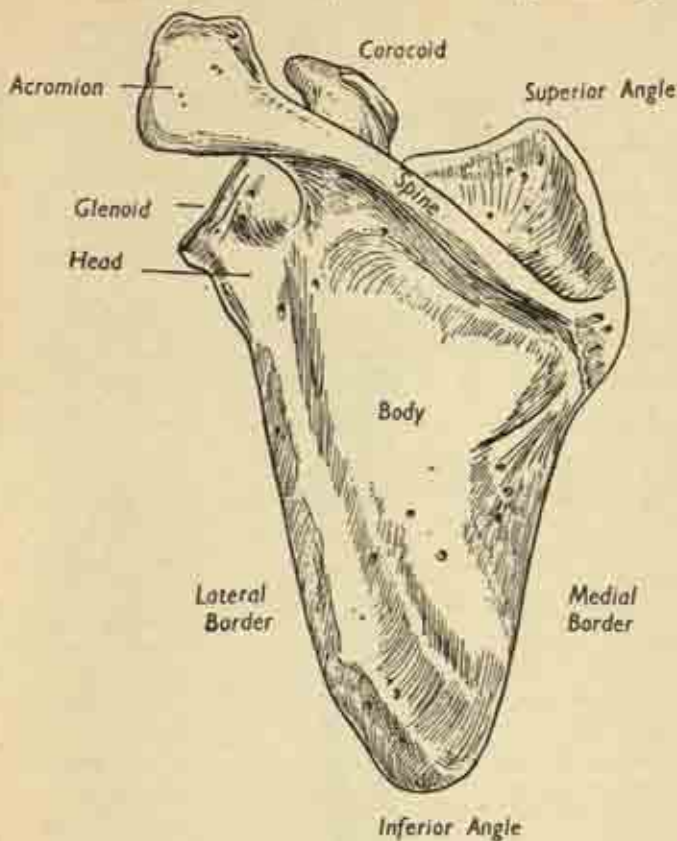


FIG. 26. Left scapula, posterior aspect.

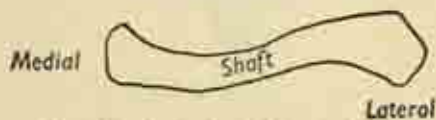


FIG. 26. Left clavicle from above.

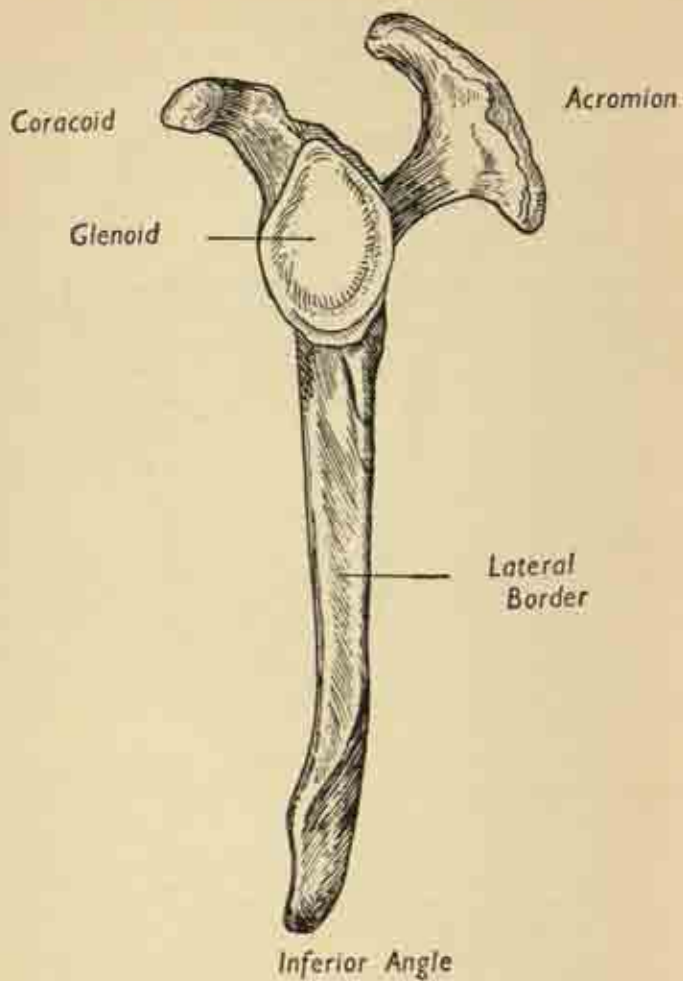


FIG. 27. Left scapula, lateral view.

stubby *coracoid process*, shaped like a crook, arising from the superior border and also overhanging the joint, but at a lower level and in front. It can be seen in fig. 27 how the acromion and coracoid together form a protective arch over the joint, the so-called secondary socket, an additional safeguard against upward displacement of the humerus.

The *clavicle* is a long slender curved rod connecting the acromion to the upper portion of the sternum, the manubrium; it lies more or less horizontally, forming the lower boundary of the neck at each side, the floor of a space called the posterior triangle. (See also fig. 130.) Its two ends are somewhat expanded; and the shaft has a rather flattened S-shaped curve, so that the medial half has a forward-bulging convexity which is reversed in the lateral portion of the bone as it sweeps away and back to reach the scapula.

### Arm.

The *humerus*, the bone of the upper arm, articulates with the scapula at the shoulder joint and with the forearm bones at the elbow; it is a long bone with a shaft and two expanded ends. The upper or proximal end carries the smooth rounded *head*, which is directed medially and upwards; on the lateral aspect of this region, opposite the head, are two prominences, the *greater* and *lesser tuberosities*, giving attachment to the small rotator muscles which intimately surround the joint. It is the greater tuberosity that forms the point of the shoulder beneath the overhanging acromion. The tuberosities are separated by the *bicipital groove* which carries the tendon of the long head of the biceps from its origin within the joint, at the upper border of the glenoid fossa, on its passage down into the arm. The true *anatomical neck* of the humerus is the narrow strip immediately encircling the head; the junction of the shaft proper with the whole mass formed

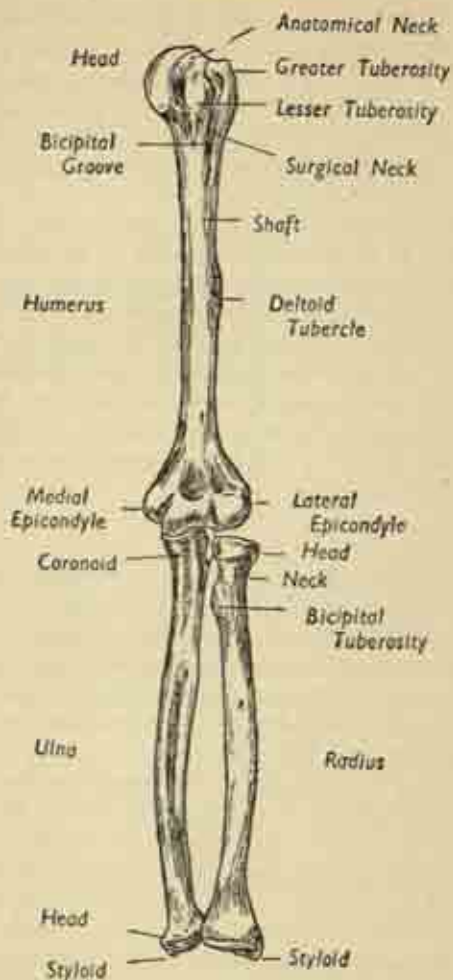


FIG. 28. Bones of the left upper limb. Anterior aspect.

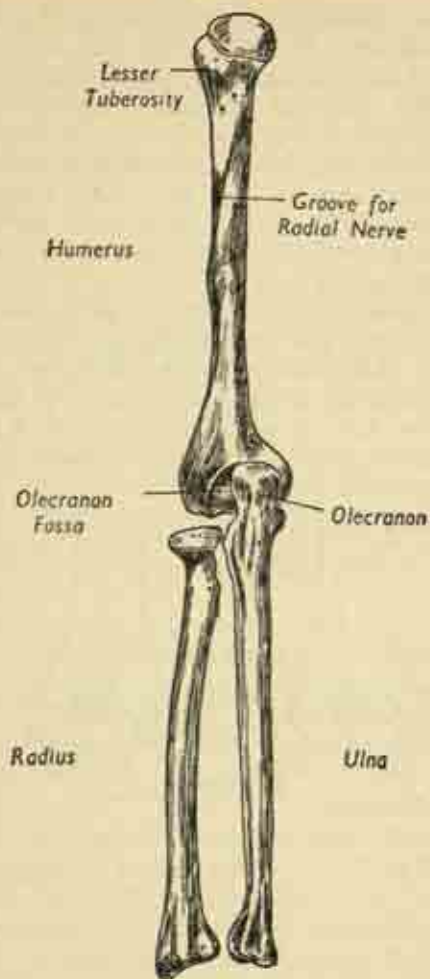


FIG. 29. Bones of the left upper limb, Posterior aspect.



by head and tuberosities is the *surgical neck*, a common site for fractures.

The *shaft* is cylindrical in its upper portion, but the lower third is triangular in section. Halfway down, its outer aspect is marked by the rough and elevated *deltoid tubercle*, the insertion of the great deltoid muscle which abducts the humerus from the side. And curving round in spiral fashion from the back of the bone, just distal to the tubercle, is the groove for the radial nerve as it passes round to the front of the arm.

At the expanded lower end, the two prominences overhanging the elbow joint on each side are the medial and lateral *epicondyles*, the former the more developed as it is the origin of the strong flexor muscles of wrist and fingers. The polished rounded projections downward from the lower end of the shaft—the lateral *capitulum*

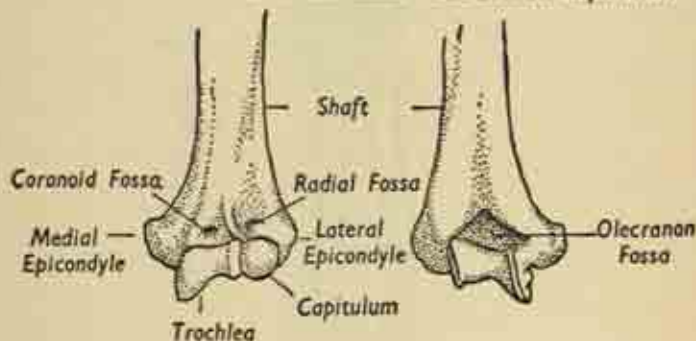


FIG. 30. Lower end of left humerus (a) anterior, (b) posterior.

and medial *trochlea*—are the parts of the humerus concerned in the elbow joint; and it will be seen that there are hollowed out depressions in the bone just above them, the *radial* and *coronoid fossa* in front and the *olecranon fossa* posteriorly, which accommodate the bones of the forearm in the extremes of flexion and extension of the joint.

**Forearm.**

The *radius* and *ulna* are the paired bones of the forearm, articulating with each other at either extremity to form the superior (proximal) and inferior (distal) radio-ulnar joints; and the lower end of the radius (but not of the ulna) forms the wrist joint with the carpal bones.

The *ulna* is the larger and lies on the medial side; its shaft has a sharp subcutaneous border which can be felt under the skin throughout the back of the forearm. The upper end carries the olecranon process behind, the point of the elbow, which fits into the olecranon fossa of the humerus; and the coronoid process in front, corresponding to the coronoid fossa. These two processes are separated by the C-shaped trochlear notch which closely embraces the trochlear process of the humerus; and just below this on the outer aspect of the ulna is a notch to accommodate the head of the radius. The head of the ulna is at its lower end, a rounded knob seen at the inner side of the back of the wrist, and carrying the small pointed styloid process.

The radius is shorter than the ulna, lying on the lateral side of the forearm, and its expanded ends are the other way round, the larger end distal and the small head proximal. The head is a smooth disc, hollowed out above to receive the capitulum of the humerus; and it fits within the circular embrace of the ring formed by the radial notch of the ulna and the annular ligament of the elbow joint. It is within this ring that the head rotates during the movements of pronation and supination (fig. 31a). The neck is a slight constriction immediately below the head, and just below this on the inner side of the upper shaft, is the bicipital tuberosity for the insertion of the biceps. The lower end of the radius is very broad and carries a styloid process which can be felt to lie rather lower than the ulnar styloid; the back of the bone

here is grooved by the passage of the extensor tendons of the wrist and fingers.

Both forearm bones have a sharp interosseous border facing each other, and connected in life by the broad sheet of interosseous membrane which lies the whole length of the forearm and separates the anterior flexor compartment from the posterior extensor compartment of the limb (fig. 31b).

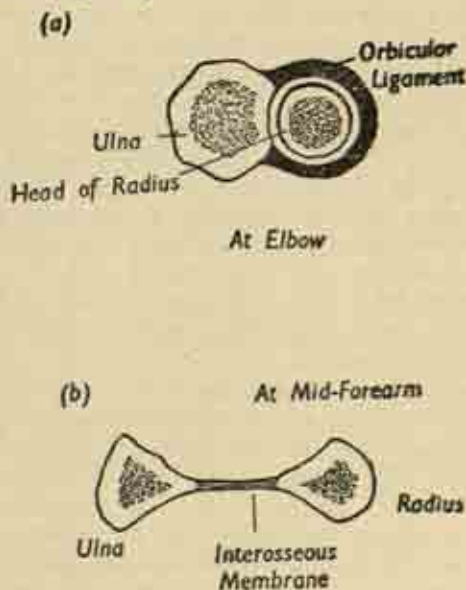


FIG. 31. Cross-section of radius and ulna at different levels, **Wrist and Hand.**

The wrist or *carpus* is composed of 8 carpal bones, small irregular cuboidal or rounded structures, arranged in two rows of four, a proximal and a distal. They are, named from medial to lateral sides: proximal row—pisiform, triquetrum, lunate, navicular; distal row—hamate,

capitate, multangulum minor, multangulum major. They interlock and are bound together by strong interosseous ligaments, so that, though the movement at the joint between any pair is small, the sum total of composite range gives the wrist its flexibility.

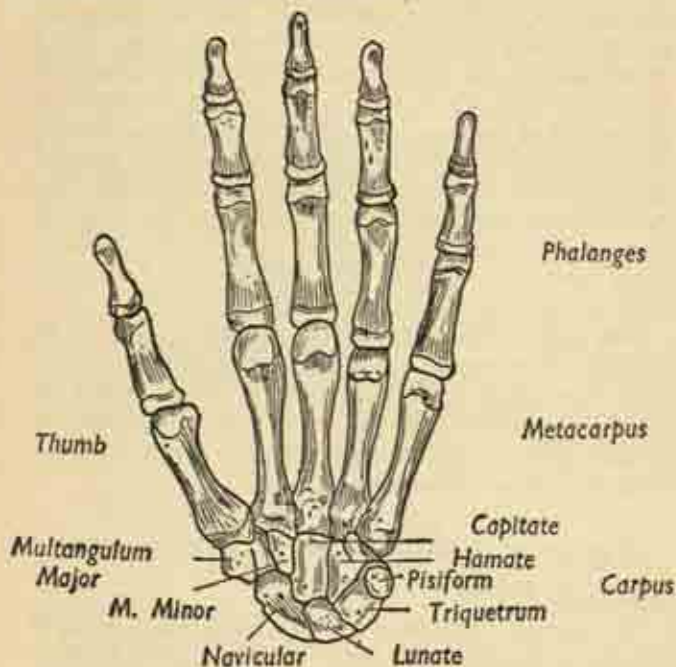


FIG. 32. Bones of left hand, anterior aspect.

The skeleton of the *hand* itself is made up of the 5 *metacarpal* bones; each is a good example of a short long bone, the miniature of a bone like the humerus, with a shaft and expanded ends. The proximal *base* of each articulates with a carpal bone at the carpo-metacarpal joint, and the rounded distal *head*, which forms the

prominence of the knuckle, makes up the metacarpophalangeal joint with the proximal phalanx of the corresponding finger.

The fingers contain three *phalanges*, articulating at the two (proximal and distal) inter-phalangeal joints. These phalanges—proximal, intermediate and terminal—are also short long bones; each has a proximal base, and a distal end formed by two rounded condyles making a hinge joint with the base of the phalanx in front. And at the end of the finger the tip of the terminal phalanx ends in an expanded bony tuft which supports the nail and nail-bed. It should be noted that the phalanges are rather concave on their anterior (palmar) surfaces; this is because they form the floor of a tunnel roofed by fibrous tissue through which the flexor tendons of the fingers glide in their synovial sheaths.

The *thumb* is considerably specialized, so that its skeleton differs considerably from that of the other digits. The metacarpal is short and slight and does not lie parallel to the others, but set freely away from the hand so that it can be opened to the fingers. And there are only two broad phalanges.

## The joints of the Arm and their movements

### Clavicular Joints.

The *acromio-clavicular* and *sterno-clavicular* joints at either end of the clavicle are simple plane joints allowing only a limited range of gliding movement; they each contain in their synovial cavity a projecting fibrocartilage disc or meniscus. And they are important mainly as accessories to the complete range of shoulder movement, which they complement. The inner is much more stable than the outer, which is easily dislocated by a fall on the arm, the outer end of the clavicle riding up over the upper surface of the acromion.



### Shoulder Joint.

This, as we have seen, is designed for mobility at the expense of stability, and the articulating surfaces are far from congruous. The large rounded humeral head, about half of a spherical surface, does not fit well into the

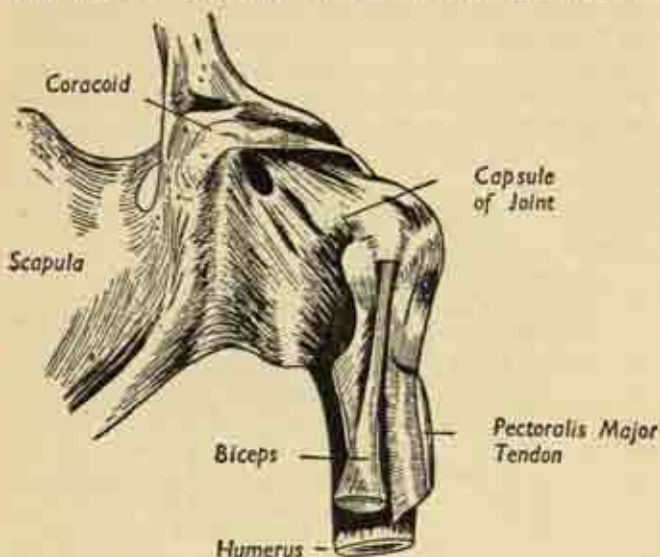


FIG. 33. Left shoulder joint, seen from in front. Note the loose capsule and the emerging tendon of the long head of biceps.

shallow glenoid fossa of the scapula, only one ninth of a sphere. But in life the socket is deepened by a fibro-cartilaginous rim, the *glenoid labrum*. The joint capsule is attached round the margins of the glenoid and the humeral head as a rather lax sleeve hanging down in a fold on the inferior aspect of the joint; this laxity is necessary if enough slack is to be present to allow the arm to be lifted freely from the side.

The essential instability is compensated in various



ways. Several thickened bands running in the substance of the capsule form accessory ligaments; and the tendon of the long head of the biceps originates within the joint from the upper pole of the glenoid fossa, traversing the cavity through a synovial sheath to emerge in the upper part of the bicipital groove between the two tuberosities. In its passage it functions as a ligament. But the main supporting factor is the intimate blending with the capsule of the tendons of the four small rotator muscles arising from the scapula, as they pass to their insertion

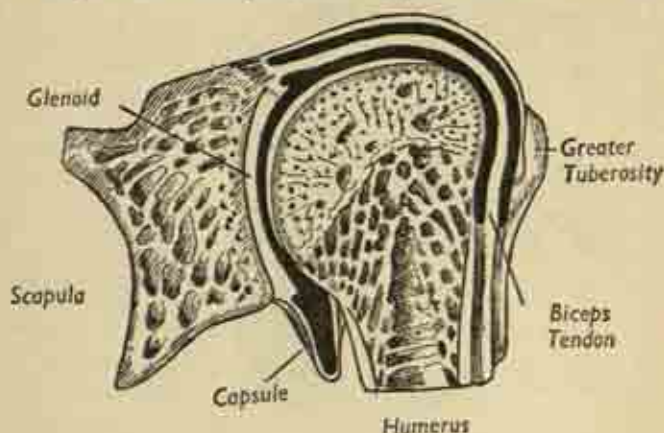


FIG. 34. The shoulder joint, longitudinal section. Note the dependent fold of capsule below, and the biceps tendon traversing the joint cavity.

on the tuberosities. These muscles are the supraspinatus, infraspinatus, teres minor and subscapularis. And these muscles which actually move the joint are therefore, at the same time, guarding against displacement by tightening up the capsule and holding the humeral head firmly against the glenoid. Even so, dislocation is common, the head passing off the glenoid to lie anteriorly under

the coracoid process. This is the common sub-coracoid dislocation; but the head may be displaced vertically downward below the glenoid, or backward beneath the spine of the scapula.

*The movements of the shoulder are :*

(i) *Abduction and adduction.* In *abduction*, the arm is lifted away from the side in the coronal plane by the deltoid muscle; the reverse movement of *adduction* is effected by gravity, or actively by the pectoralis major muscle in front of the chest, and by the latissimus dorsi and teres major behind (fig. 21).

(ii) *Flexion and extension*, which occur in the sagittal plane, through a combination of muscles (fig. 21).

(iii) *Rotation*, produced by the small rotators, arising from the scapula (fig. 22); it is lateral or medial.

(iv) Finally, *circumduction*—a combination of all these, a swinging motion of the outstretched arm.

What makes these movements more complex, particularly abduction, is that they do not occur alone but in association with movement of the scapula, for this bone can be rotated on the trunk by the large flat triangular trapezius muscle of the back, arising from the spine. The arm can be abducted through  $180^{\circ}$  but only half of this is true shoulder motion, the rest being produced by scapular rotation. Both movements occur in simultaneous co-ordination from the outset, and at the same time the outer end of the clavicle rises and there is gliding movement at both clavicular joints (fig. 35).

#### **Elbow Joint.**

This comprises three articulations: the true elbow hinge joint between the trochlear process of the humerus and the corresponding notch of the ulna; the shallow articulation of the radial head and the humeral capitulum; and, inferiorly, the proximal radio-ulnar joint whose synovial cavity is continuous with that of the others.

As in all hinge joints, the collateral ligaments at the

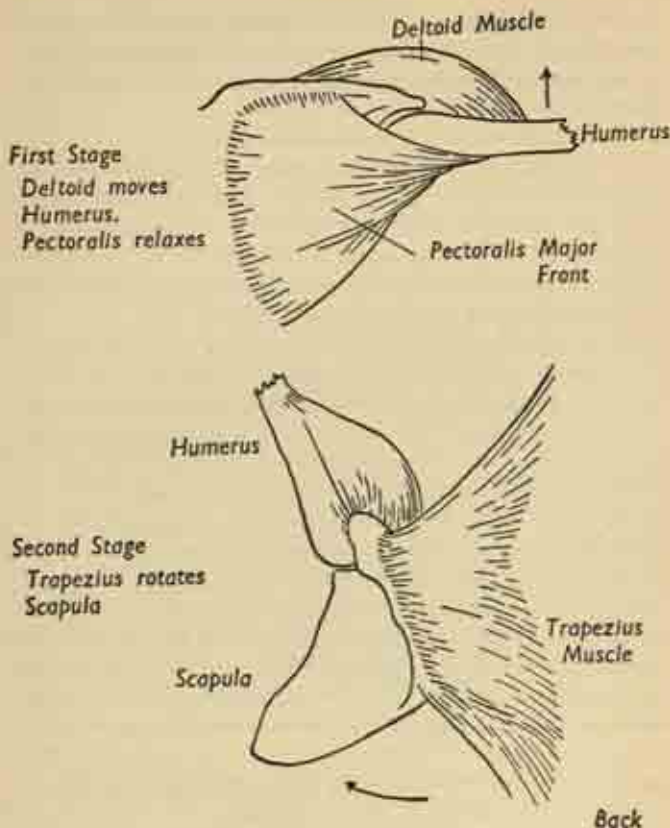


FIG. 35. Stages in abduction of the left shoulder joint. (a) anterior, (b) posterior. These stages are not as distinct as the figures suggest, for humerus and scapula both move from the outset, the former more at the beginning and the latter more at the end of movement.

sides are very strong and these, with the deep interlocking of humeral and ulnar surfaces, allow only flexion and extension to occur. To facilitate these the anterior and

posterior portions of the capsule are so lax as to be easily stretched in the full extremes of range. When the elbow is fully extended, arm and forearm are not in line but at an angle of  $5-10^{\circ}$ , the carrying angle, larger in women than in men, which disappears as the joint is flexed. *Flexion* is produced by the biceps and brachialis muscles,

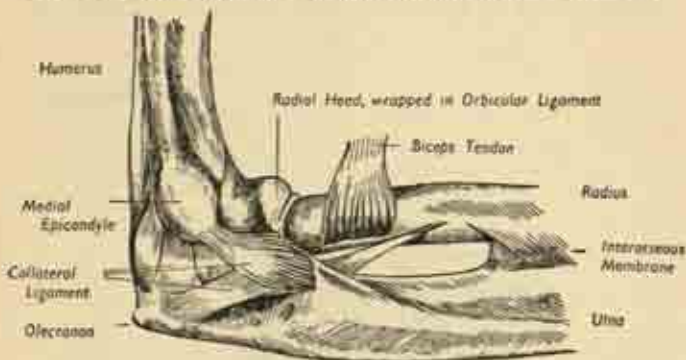


FIG. 36. Medial aspect of left elbow joint. (After Gray).

the superficial and deep muscles of the anterior compartment of the arm; it is checked by the contact of the soft tissues of arm and forearm before the coronoid process of the ulna has settled very far into the corresponding fossa of the humerus. *Extension*, which usually goes a few degrees beyond the straight position, is produced by the triceps at the back of the arm, and checked by the fitting of the olecranon process into its humeral fossa. The triceps tendon blends closely with, and strengthens, the back of the elbow joint capsule.

We have seen that the *proximal radio-ulnar joint* is formed by the round head of the radius rotating like a pivot in the circular embrace formed by the radial notch of the ulna and the annular ligament of the joint (figs. 31, 36). Although its movements are distinct, its synovial cavity is freely continuous with that of the elbow

joint proper and infectious processes spread easily from one to the other.

*Pronation and supination* are the names of the rotary movements of the forearm responsible for twisting the palm of the hand forwards and backwards. In this movement the ulna remains stationary while the radius rotates round it, moving at both radio-ulnar joints and

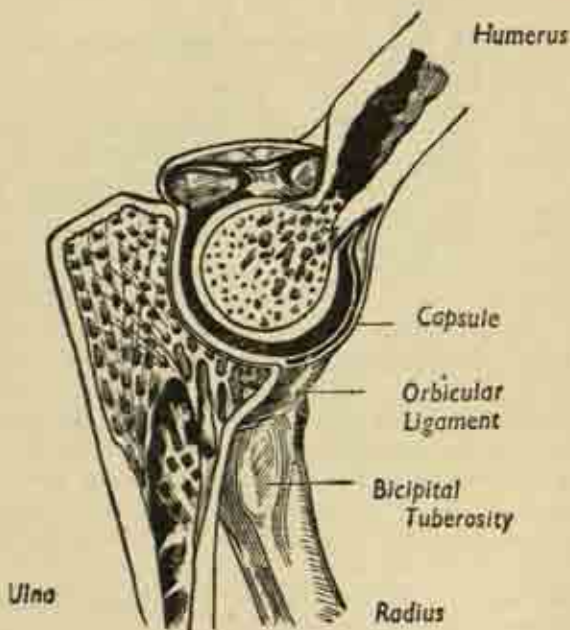


FIG. 37. Elbow joint, longitudinal section. (After Gray).

along the axis of the interosseous membrane connecting the two bones. At the inferior radio-ulnar joint the relations of the two bones are just the opposite of the condition at their upper ends, the small rounded ulnar

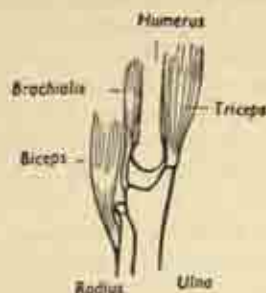

FIG. 38. Muscles responsible for flexion and extension of the elbow.

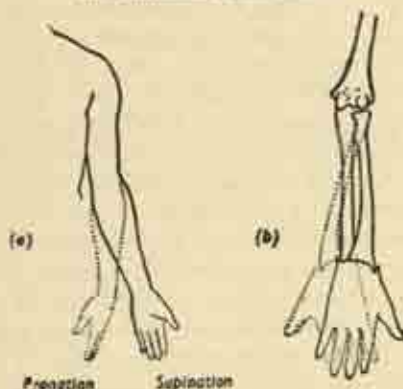


FIG. 39. Pronation and supination.  
(a) Note the "carrying angle" in the supine position. (b) The movement of the radius.

head fitting into an ulnar notch on the broad radial expansion. In addition, the bones are connected by a triangular cartilage plate with its apex fixed to the ulnar styloid process. The apex of this triangle is the lower end of the axis of pronation-supination, the upper being the centre of the head of the radius; and the disc completely



shuts off the lower end of the ulna from the wrist joint proper, the radio-carpal articulation.

### **Joints of Wrist and Hand.**

The *wrist-joint* is formed between the proximal row of carpal bones (navicular, lunate, triquetrum) and the composite surface made up by the distal end of the radius plus its cartilage plate fixed to the ulna. It is a modified hinge joint with strong ulnar and radial collateral ligaments, whose main movements are flexion (*palmar-flexion*) and extension (*dorsi-flexion*). But in addition there is movement of the whole wrist and hand to either side, *abduction* and *adduction*—ulnar and radial deviation—and the normal position for a strong grip is in slight adduction, not in exact line with the forearm.

There are numerous small *carpal joints* between the individual bones of the carpus, which are bound together by short interosseous ligaments, the whole forming a complicated synovial cavity continuous with the wrist-joint proximally and the *carpo-metacarpal joints* distally, where the metacarpal bases articulate with the distal row of carpal bones. Little motion occurs at these latter joints, except at the specialized saddle joint between the thumb metacarpal and the multangulum major. Here motion is very free and its principal components are :

- (i) *adduction* to the side of the hand and *abduction* away from it, in the plane of the palm;
- (ii) movement in a plane at right angles to the palm, *palmar abduction* and *adduction*;
- (iii) the characteristic human movement of *opposition* in which the thumb is carried across the palm and its tip opposed to that of another digit in grasping.

Note that this is a complex motion in which the metacarpal rotates on its long axis so that the thumbnail faces forwards instead of outwards (fig. 40).

The *metacarpo-phalangeal joints* between the heads of the metacarpals and the bases of the phalanges are again

modified hinge joints with strong collateral ligaments on each side and only a loose dorsal and palmar capsule. The main movements are flexion into the palm, and extension backwards, and usually there is some  $10-15^{\circ}$

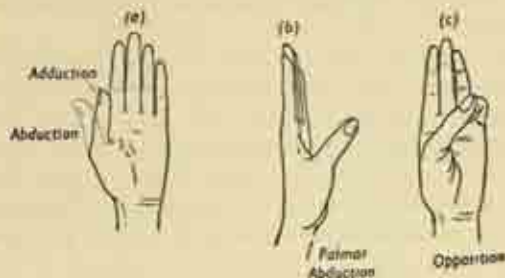


FIG. 40. Movements of the thumb.

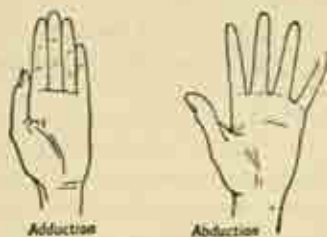


FIG. 41. Abduction and adduction of the fingers.

of hyperextension behind the plane of the palm. In addition, there are side-to-side movements known as adduction and abduction, based on the relation to the axis through the middle finger, abduction being away from this centre and adduction towards it. The middle finger itself is abducted whether it moves laterally or medially.

The small inter-phalangeal joints allow flexion and extension only.

### Surface anatomy of the Arm.

Now that the bony framework of the limb has been reviewed, some aspects of the surface anatomy may be considered. Inspecting and palpating the *anterior aspect* of the arm, the following features are noted from above downwards.

At the *shoulder*, the clavicle is seen under the skin, the acromion process and the upper end of the humerus give the general rounded contour, and the coracoid process can be felt by deep pressure in the hollow under the outer end of the clavicle. The great bulge of the deltoid muscle is obvious, clothing the lateral aspect of the joint; and the pectoral muscles appear when the arm is adducted against resistance.

In the *arm*, there is the bulge of the biceps.

At the *elbow*, the prominences of the medial and lateral epicondyles are visible and palpable on either side, particularly the former, and the biceps belly fades away into its tendon which can be felt as it crosses the elbow hollow, the *ante-cubital fossa*.

In the *forearm*, the general muscular bulge of the flexors of the wrist and fingers fades into the visible or palpable tendons of these muscles just above the wrist; and on each side of the latter joint are felt the styloid processes of radius and ulna, the former at a slightly lower level.

In the *hand*, the anterior (palmar) aspect consists of the central palm proper with a muscular eminence on either side. The larger lateral *thenar* eminence, the ball of the thumb, is made up of the short muscles of that digit, and the shallower *hypothenar* eminence on the medial side covers the corresponding muscles of the little finger. The three main palmar creases are fairly constant, and it should be noted that the line of the webs between the fingers as seen from the front is not opposite the metacarpo-phalangeal joints, i.e., the knuckles behind, but lies a good inch more distally.

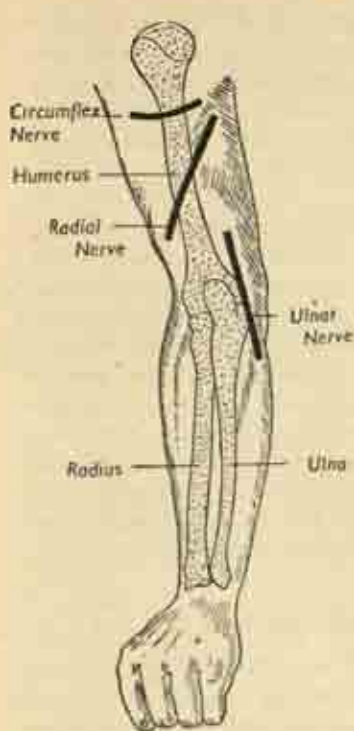


FIG. 42. Surface markings of important vessels and nerves of the left arm. Posterior.

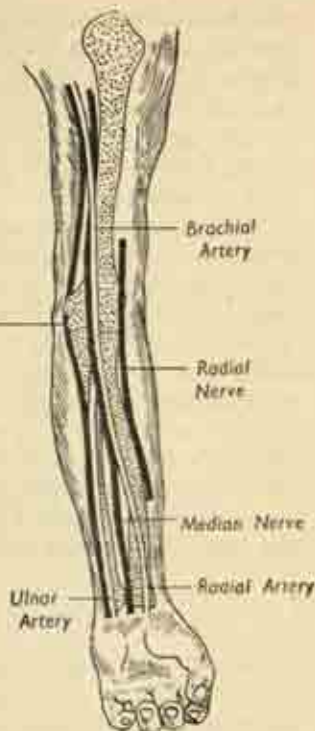


FIG. 43. The same. Anterior.

Running down the *posterior aspect* of the limb in the same way, we note at the *shoulder* the subcutaneous spine of the scapula ending in the overhanging acromion process, and again the bulge of the deltoid. The muscle mass at the back of the *arm* is the triceps; and the same bony points are noted at the elbow, with the addition of the olecranon process of the ulna forming the point of

the elbow midway between the epicondyles. In the *fore-arm* the bellies of various extensor muscles of wrist and fingers can be seen or felt; and at the *wrist* the head of the ulna is prominent on the medial side of the *dorsum*. On the back of the *hand* the knuckles mark the metacarpal heads, and the extensor tendons are seen when their muscles contract.

The surface markings of certain underlying nerves and vessels are indicated in figs. 42 and 43. The only nerves which are really superficial and easily felt are the ulnar nerve in its groove behind the medial humeral epicondyle at the elbow and can be rolled to give the familiar tingling in forearm and little finger; and the median nerve at the front of the wrist. Both are very vulnerable to penetrating injury at these sites. The main arteries are also fairly deep except at the wrist, where the radial and ulnar vessels can be felt pulsating on either side under the skin; and it is often possible to see the beating of the superficial arterial arch in the palm.

### The subcutaneous structures of the Arm

Fig. 44 shows the flayed arm, divested of skin and superficial fascia. They demonstrate how the deep fascia forms a continuous sheath for the deep structures of the limb, and it can be seen that a network of veins and cutaneous nerves ramifies between skin and deep fascia, branches which all ultimately penetrate the fascia to join their parent vessels or nerves. The venous network in hand and forearm is complex but is gathered up in two main channels in the arm, the cephalic vein running up the lateral side of the biceps to the shoulder, and the basilic vein on the medial side piercing the fascia halfway up the arm to run alongside the brachial artery.

There is a subcutaneous *bursa* over the olecranon process, separating it from the skin.

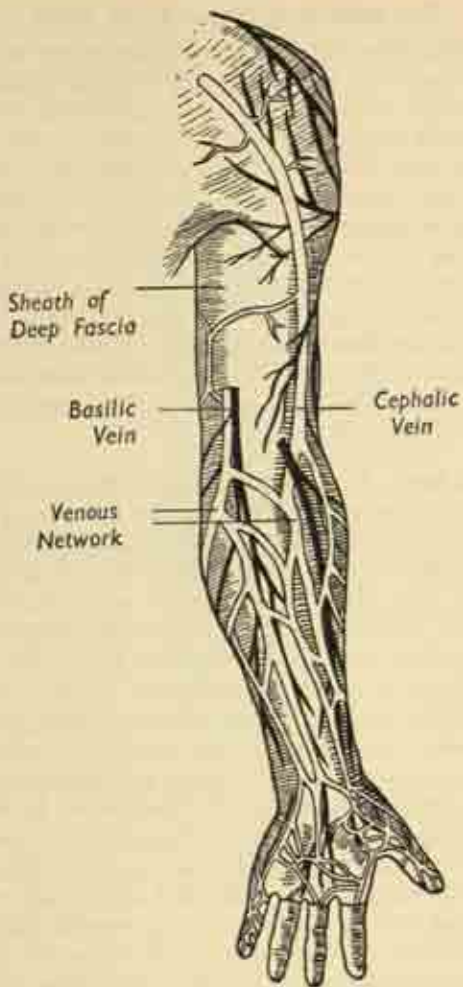


FIG. 44. The flayed arm, showing the subcutaneous structures. Anterior.



### The muscle groups of the Arm

**Shoulder.** The *deltoid* muscle on the outer side overlaps the front and back of the limb, lying in the same plane as the *pectoralis major* which passes from the clavicle and upper ribs to its insertion in the upper humerus. The deltoid abducts the arm, the pectoralis adducts it to the side; and adduction is also performed by the *teres major* and *latissimus dorsi* posteriorly, the latter being one of the great muscles of the back which arises from the spinal column (fig. 115). Lying very deeply, and arising from the scapula, are the short rotators of the humerus, inserted into the tuberosities under cover of the deltoid; their actions in rotating the bone laterally or medially are sufficiently clearly demonstrated in figs. 47-49.

**Upper Arm.** This is seen in cross-section to be divided into anterior and posterior muscular compartments by the humerus itself, with a lateral and medial intermuscular septum of deep fascia attached to each side of the bone (fig. 50). The anterior (*flexor*) compartment contains those muscles flexing the elbow, the biceps superficially and the brachialis nearer the bone. The *biceps* has two heads of origin, a long tendon arising within the shoulder joint and a short one from the tip of the coracoid process; they join to form the main belly, from which the tendon of insertion issues just above the elbow to reach the bicipital tuberosity of the radius. In addition to its flexing action, the biceps is also the most powerful supinator muscle of the forearm owing to the fact that it is inserted near the back of the radius and can rotate it on its long axis; it is essential in powerful supinating actions like the use of a corkscrew or screw-driver. The underlying *brachialis* arises from, and clothes, the front of the humerus and is a simple elbow flexor, inserted into the coronoid process of the ulna.

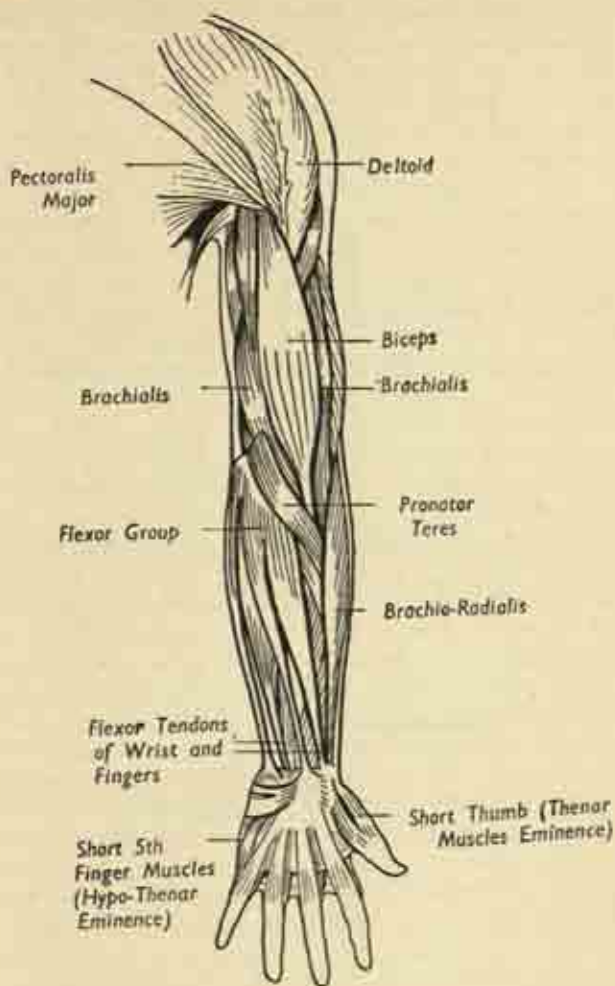


FIG. 45. Muscles of the left upper limb. Anterior aspect.

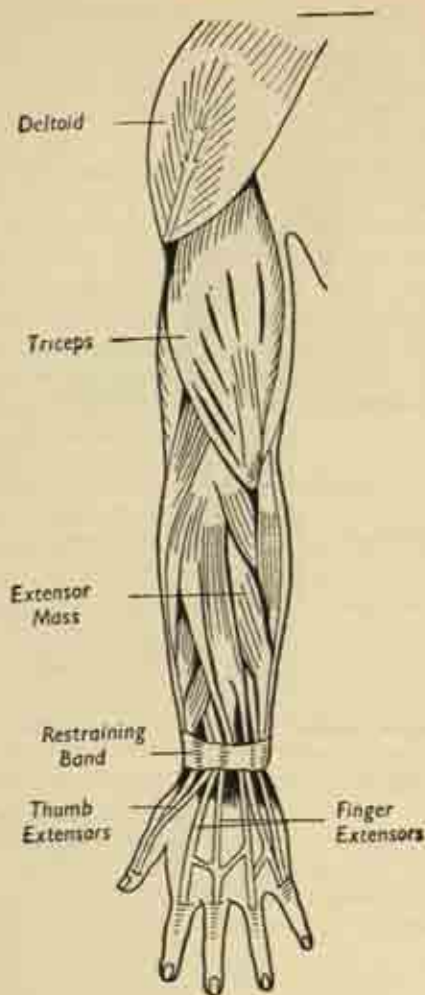


FIG. 46. Muscles of the left upper limb. Posterior aspect.

At the back of the arm, in the *extensor* compartment, the *triceps* arises by three muscular heads, two from the humerus and one from the scapula below the glenoid. The tendon of insertion goes into the olecranon process of the ulna, but some fibres are also attached to the back of the joint capsule, and by pulling it out of the way save it from being nipped as the joint is extended.

**Forearm.** This is similarly divided into flexor and extensor compartments by means of the interosseous membrane between radius and ulna, and each compartment contains a complex group of muscles with an associated nerve-trunk.

In the *flexor* compartment are a superficial and a deep group of muscles lying in two planes, with the median nerve, which supplies them, running between the layers. The *superficial* group arises from a common flexor origin on the medial humeral epicondyle. It includes the pronator teres, the main pronator muscle of the forearm, inserted into the middle of the radius; the superficial flexors of the fingers; and the flexors of the wrist joint. The *deep* group arises from the forearm bones and interosseous membrane and includes the deep flexors of the fingers and the long flexor of the thumb. And the lateral muscular boundary of the front of the forearm is the brachioradialis, which passes from the lateral humeral epicondyle to be inserted into the lower radius, acting alternately as pronator and supinator. All these flexor bellies become tendinous an inch or two above the wrist, and those tendons destined for the fingers pass into the hand in company with the median nerve under a transverse ligament spanning the arch of the carpal bones, an arrangement known as the carpal tunnel (fig. 52). It will be seen that each finger, but not the thumb, has two long flexor tendons, a superficial and a deep; and the arrangement of these in the hand will be studied later.

The *extensor* forearm compartment is again arranged

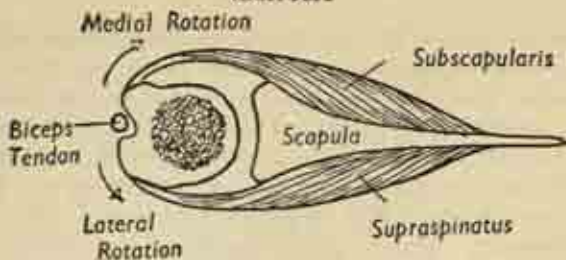
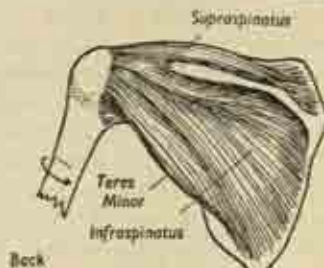


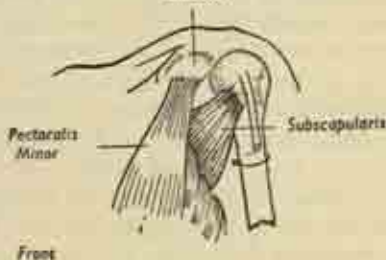
FIG. 47. Cross-section of scapula and head of humerus to show action of short rotator muscles.



Outward Rotation by the Group of  
Short Rotator Muscles

FIG. 48.

Caracoid



Inward Rotation by the  
Subscapularis Muscle

FIG. 49.

in superficial and deep layers of muscles; and, just as the superficial flexor group arises from the front of the medial epicondyle, so the superficial extensor group arises from the back of the lateral epicondyle. And just as the principal nerve of the flexor compartment is the median,

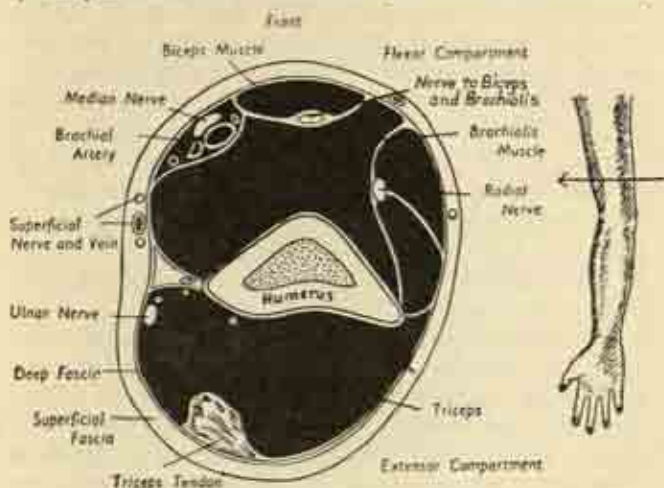


FIG. 50. Cross-section of the upper arm near the elbow.

so the main nerve at the back is the radial. The main groups of extensor muscles are :

- (i) the extensors of the wrist joint;
- (ii) the extensors of the fingers (only one tendon to each finger, except the index and fifth, which have two);
- (iii) the extensors of the joints of the thumb.

All these tendons are bound down by a restraining band of deep fascia at the wrist to prevent them from bowstringing backwards when their muscles contract.

#### The blood vessels of the Arm.

The main artery to the upper limb begins in the neck as the subclavian. On the right this is a branch from the great innominate artery. On the left it arises directly



from the arch of the aorta in the chest. (Plates 9, 10.)

As the vessel passes out through the axilla to reach the arm, it is known as the *axillary* artery, and in the upper arm proper as the *brachial*. Here it lies on the medial side of the biceps with its companion vein, in close relation to the median and ulnar nerves. At the elbow the brachial divides into radial and ulnar branches which course down the corresponding sides of the forearm; at the wrist the ulnar artery continues into the palm, while the radial turns round on to the back of the carpus. In the palm there are two *arterial arches* or *arcades* formed between branches of the two vessels; from these arches the digital arteries to the fingers are given off. A less important *dorsal arterial arch* is formed on the back of the carpus by the radial vessel alone, with twigs to the fingers. (Plate 2.)

The *veins* are less clear-cut in their peripheral arrangement than the arteries, forming a diffuse subcutaneous network in hand and forearm; but the main lateral (cephalic) and medial (basilic) channels emerge at the elbow. The cephalic runs up to the shoulder before it dives under the clavicle to join the subclavian vein; the basilic vein runs alongside the brachial artery to the axilla, where it continues as the axillary vein and ultimately as the subclavian in the neck (fig. 44).

The fine *lymphatic* vessels are arranged in a superficial network corresponding to the venous pattern; and the main lymphatic trunks of the limb are gathered up to run with the brachial artery, entering the main group of lymph glands of the arm in the axillary space. There is a small gland-station halfway up the arm, just in front of the medial epicondyle, the epitrochlear gland (fig. 8).  
**The nerves of the Arm.** (Figs. 42, 43. Plates 1, 10.)

The nerves of the limb are the ultimate branches of a complex *brachial plexus* of spinal nerve-roots situated in the lower neck, behind the clavicle, and in the axilla

From this plexus emerge the main nerve trunks of the arm—median, radial and ulnar—which are grouped closely around the axillary vessels in the lower part of the axilla.

The *radial* nerve soon runs round to the back of the upper arm, passing spirally round the humerus close to the bone in its radial groove, to re-emerge anteriorly just above the elbow in the fold between the biceps and the brachio-radialis muscles. It then winds back round the neck of the radius to become the main nerve of the

*Flexor Compartment, Front*

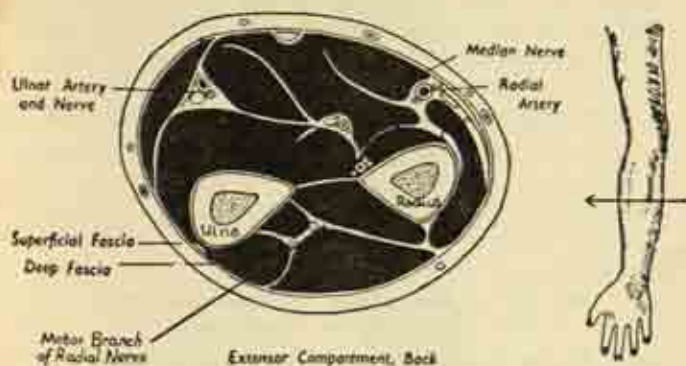


FIG. 51. Cross-section of right forearm, viewed from above.

extensor compartment of the forearm. It is mainly a motor nerve, supplying the triceps, brachioradialis, and extensors of wrist, thumb and fingers; but it has a small sensory supply to the skin on the back of the hand between thumb and index, and to the outer side of the forearm, and this superficial branch runs with the radial artery in the flexor compartment.

The *median* nerve passes down the arm in company with the brachial artery, and lies in the forearm between the superficial and deep planes of flexor muscles in the

anterior compartment. It supplies most of the forearm flexor group; and enters the palm by passing under the transverse carpal ligament with the flexor tendons of the fingers. In the hand it gives an important branch to the small thumb muscles in the thenar eminence, and sensory branches which accompany the digital arteries to the fingers, supplying the skin of the thumb, index, middle and lateral half of the ring finger on their anterior aspects. (Plate 2.)

The *ulnar nerve* also runs with the brachial artery in the arm, but enters the forearm separately by passing behind the medial epicondyle in the ulnar groove. It runs on the inner side of the flexor compartment with the ulnar artery, enters the hand superficial to the transverse carpal ligament, and supplies all the small intrinsic hand muscles responsible for the fine co-ordinated move-

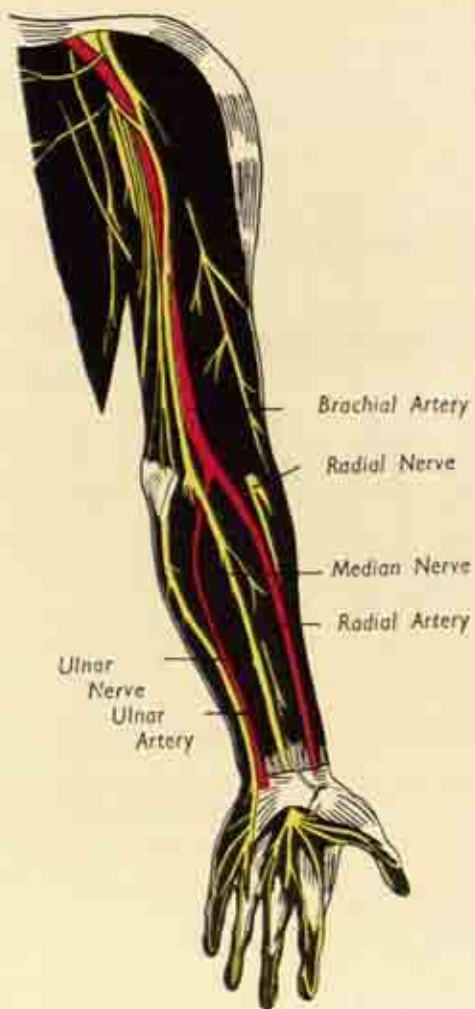


FIG. 52. Cross-section of wrist to show the flexor tendons in the carpal tunnel.

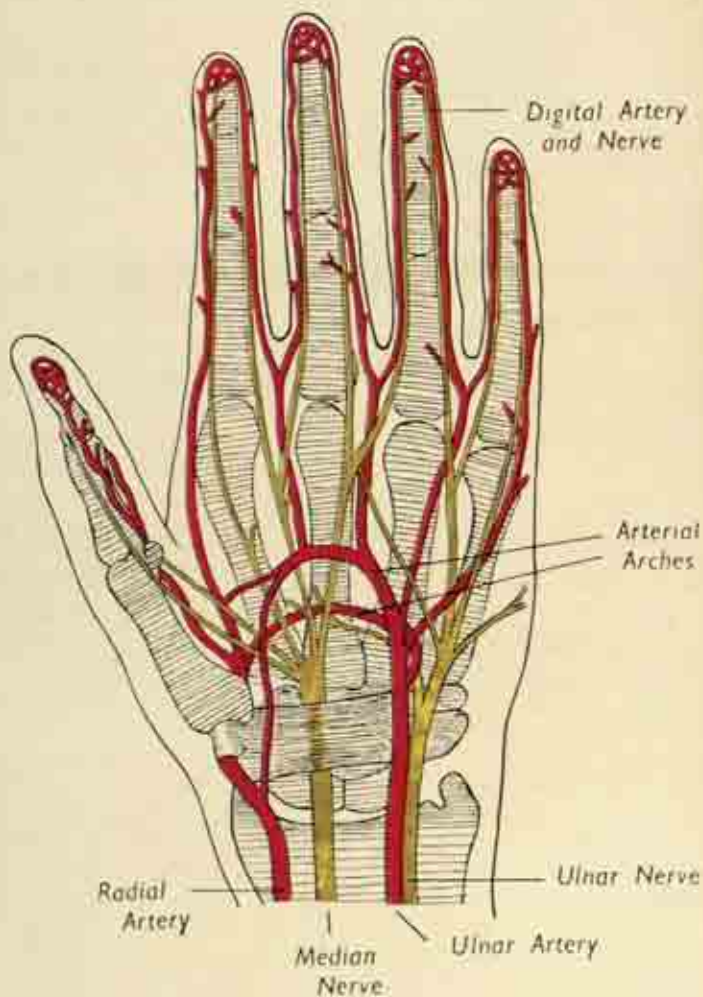
ments of the fingers. It also supplies sensation to the fifth and inner half of the ring fingers, on front and back.

### The Hand.

The main *palmar space* of the hand is bounded by the thenar and hypothenar eminences on each side; its floor is the skin of the palm, and its roof the metacarpal bones. Through it pass the flexor tendons on their way to the fingers; and in it lie the arterial arches of the ulnar artery with their digital branches to the fingers, and the accompanying digital branches of the median and ulnar nerves. Lying between the metacarpals and arising from them are the *interossei*, the small intrinsic muscles of the hand;



Plan of the main nerves and vessels of the upper limb.



Nerves and vessels in the hand.

(After Bruce and Walmisley.)

PLATE 2

their tendons wind round the metacarpal necks to be inserted into the extensor tendon expansion on the back of the proximal phalanges, and they abduct and adduct the fingers as well as performing certain characteristically human movements described below.

The *dorsum* of the hand is considerably simpler, a shallow space between the skin and the backs of the metacarpals traversed by the extensor tendons of the fingers.

In the *fingers*, the arrangement of the flexor tendons

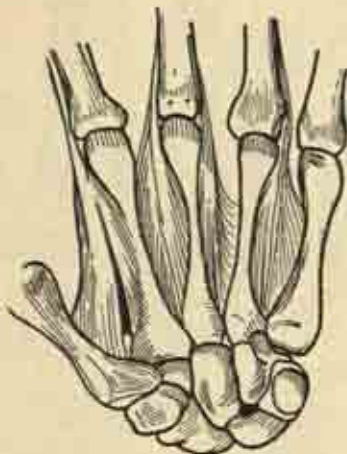

FIG. 53. The interosseous muscles of the hand.

is complex. Each digit, save the thumb, has two flexors, superficial and deep, which are inserted into the phalanges as shown in fig. 54, the deep tendon on its way to the terminal phalanx splitting the other in two. The tendons are facilitated in their gliding by being enclosed in a smooth, double-layered, *synovial sheath*; and each sheath in turn is enclosed in a fibrous tunnel which is attached to the phalanges on each side. The general arrangements



of these sheaths is shown in fig. 55, and it will be seen that each is separate except that of the little finger, which runs down into the palm to expand into a general sheath for all the tendons passing through the carpal tunnel. Because of this connexion, infections of the little finger are more dangerous than those of other digits, as they may spread along the sheath into the hand and forearm instead of remaining confined to the finger.

On the dorsum, the arrangement of extensor tendons is

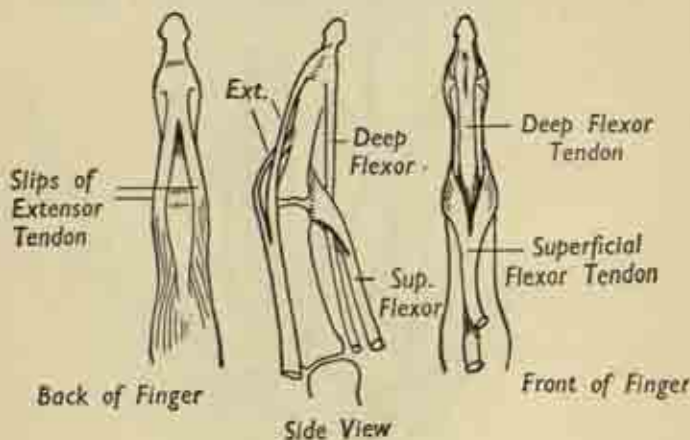


FIG. 54. Tendon arrangements in an individual finger.

much simpler; there is a common synovial sheath as they pass over the wrist, but the individual tendons of the fingers are without sheaths. Fig. 54 indicates how the tendon of each finger splits up as it is inserted; note the broad extensor expansion which strengthens the back of the capsule of the metacarpo-phalangeal joint, the expansion which is also the insertion of the intrinsic muscles.

The main features of the *nails* are sufficiently indicated in fig. 57.

### Function of the Hand.

In the lower animals the digits are used purely for the crudest of gripping purposes, the important muscles being the long flexors and extensors which alternately contract and relax their hold on an object (fig. 58(a) (b)).

Man retains this power, but has also developed a fine co-ordinated action of the fingers in themselves as distinct

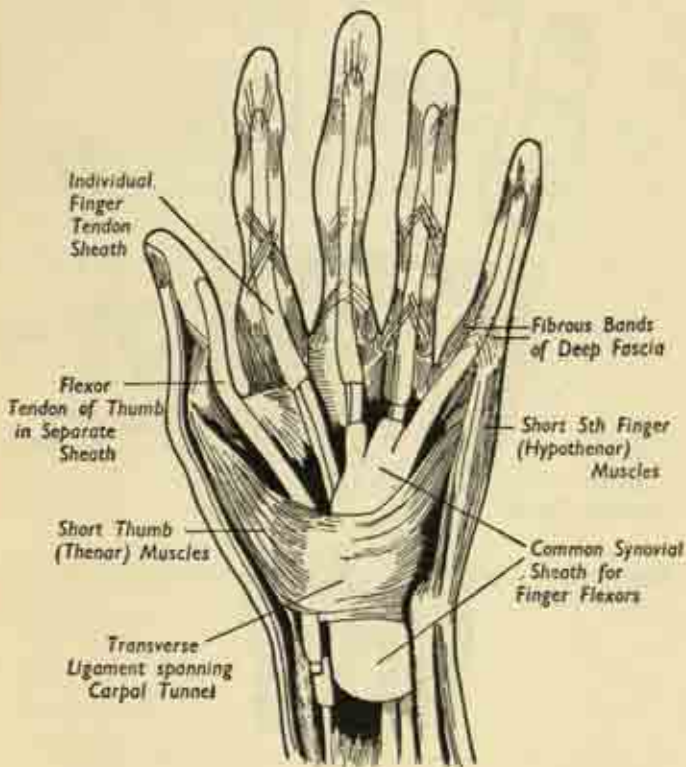


FIG. 55. Flexor tendons and their sheaths in wrist and hand.  
(After Gray).

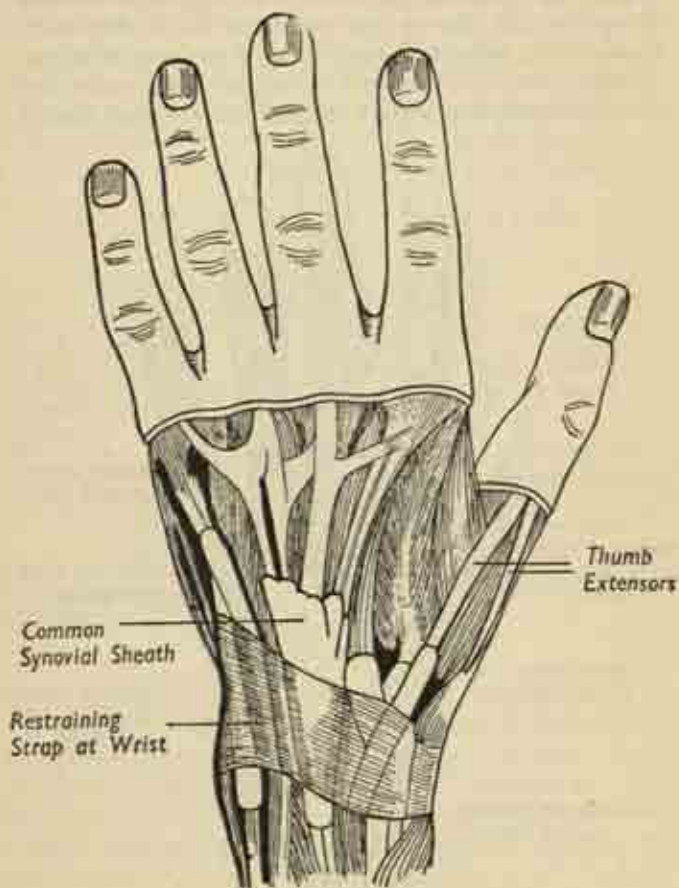


FIG. 56. Extensor tendons and their sheaths in wrist and hand.  
(After Gray).

from the forearm muscles. This activity has been developed by the evolution of the local intrinsic muscles, confined to the hand, which are required for writing and the use of delicate tools. Their essential action is the adoption of the writing position in the fingers and of the



FIG. 57. The fingernail grows forward from the nail-bed at its root.

opposition of the thumb to them in a fine grip. This the small muscles achieve by flexing the metacarpophalangeal joints and then extending the inter-phalangeal joints by pulling on the distal stub of the long extensor tendons (fig. 58(c)).



FIG. 58. (a) and (b) crude movements, and (c) fine use of the fingers.

## CHAPTER VI

### THE LEG

#### Bones of the Lower Limb

##### **Innominate Bone.**

THE general arrangement of the pelvic girdle has already been indicated at p. 61. Each half of the pelvic ring is made up of one innominate or hip-bone. The two bones articulate with each other in the midline anteriorly at the pubic symphysis, the bony prominence felt just above the external genitalia. Behind, each innominate bone articulates with the sacral portion of the spine at the sacro-iliac joint, a strong irregular junction allowing very little motion.

The innominate bone itself combines the functions of a proximal support for the limbs and an attachment for the limb-muscles, with those of a bony container for the pelvic organs; the latter aspect is considered in Chapter VII. Here, we need only note that it consists of three main portions—ilium, ischium and pubis—all centred on the acetabulum, the socket for the femoral head.

The *ilium* is a broad, flaring sheet of bone, whose upper border is the iliac crest which is felt in putting the hand on the hip; and this crest has an anterior and a posterior spine at either end.

The *pubis* has a superior and an inferior strut or ramus, the two rami enclosing a large gap in the bone, the obturator foramen; on the superior ramus is a little knob, the pubic tubercle, which can be felt at the inner end of the fold of the groin.

The *ischium* is the dependent portion of the pelvis,

carrying the broad ischial tuberosity which takes the body-weight in sitting.

The *acetabular socket* of the hip joint is a deep cavity in the centre of the external aspect of the bone, with an encircling upstanding rim shaped like a horse-shoe, deficient at the acetabular notch in front and below.

In life there are important ligamentous and muscular attachments to the innominate bone. The anterior spine of the ilium and the pubic tubercle are spanned in a

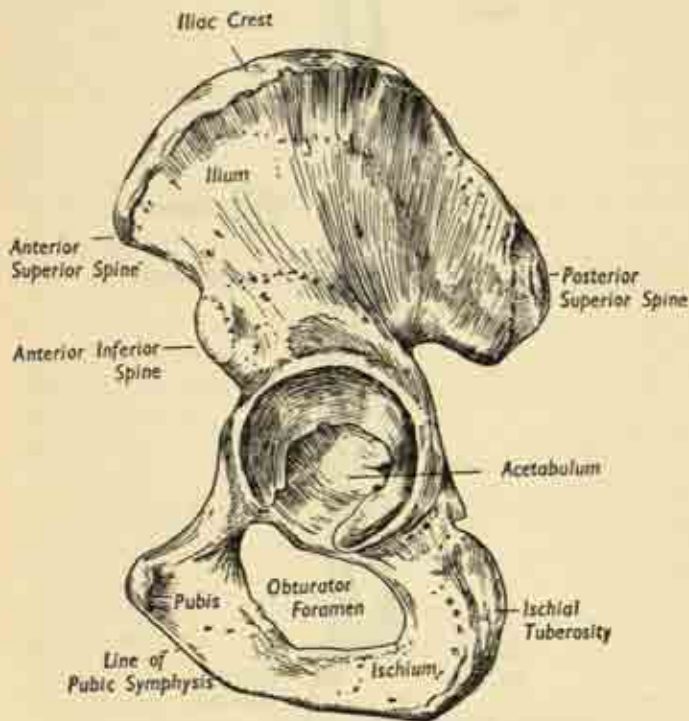


FIG. 59. Left innominate bone, outer aspect.



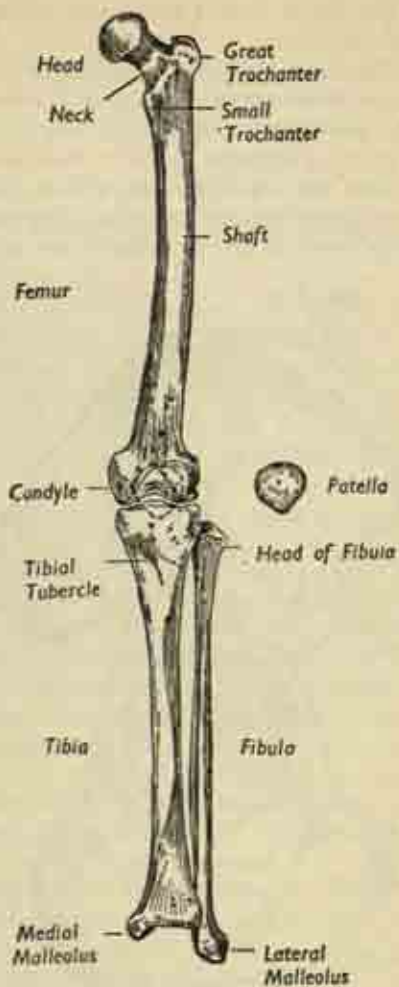


FIG. 60. Bones of left lower limb. Anterior aspect.

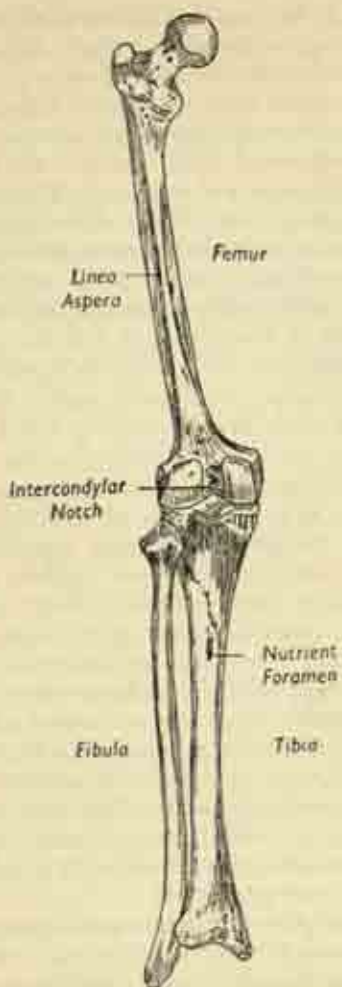


FIG. 61. Bones of the left lower limb. Posterior aspect.

straight line by the *inguinal ligament* of the groin, an important structure separating thigh from abdomen, under which the great vessels and nerves pass into the limb from the trunk. The obturator foramen is bridged across by the *obturator membrane*, pierced by nerve-twigs and small vessels; and the acetabular notch is crossed by the *transverse ligament*. The broad outer surface of the ilium is the origin of the gluteal muscles of the buttock; the ischium, of the hamstring muscles of the back of the thigh; and the pubis, of the adductor muscles which bring the leg in towards the midline.

### Femur.

This bone has a long cylindrical shaft, with a normal slight outward and forward bowing which is grossly exaggerated by the effect of body weight in diseases which soften the skeleton. At its upper end the well-rounded *head*, some two-thirds of a complete sphere, is set well off the shaft at a fairly constant angle of some  $130^{\circ}$  by the long stout *neck*. And at the base of the neck are the two *trochanters*, both rather more obvious on the posterior aspect of the bone, the great trochanter laterally, the small trochanter medially. The neck acts as a lever for the muscles attached at its base; so that the relative restriction of motion which is the price of security at the hip as compared with the shoulder is compensated by an increase in the mechanical advantage of its surrounding muscles. The neck itself is at a constant mechanical disadvantage under the stress of body weight, and its angle with the shaft is diminished by softening disease or by fractures.

The shaft is thickly clothed by muscles, many of which gain an attachment to the great bony ridge running down the length of its posterior aspect—the *linea aspera*; not far below the neck, the posterior surface is marked by the gluteal tuberosity, the insertion of the great gluteus

maximus muscle of the buttock. A few inches above the knee, the shaft expands in triangular fashion, ending in two massive condyles, lateral and medial, separated by a deep intercondylar notch; the medial is the more prominent and is set at a slight angle to the line of the shaft, as seen from below (fig. 62). The lower end of the femur has a smooth surface above the condyles in front for articulation with the patella; and a broad trigone or popliteal surface posteriorly facing back into the *popliteal fossa*, the hollow at the back of the knee. There is a small epicondyle on the free surface of each condyle; and the adductor tubercle at the summit of the medial condyle is the lowest attachment of the adductor group of muscles.

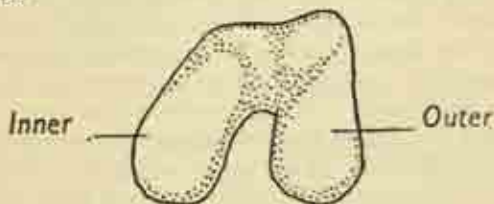


FIG. 62. Condyles of left femur, end-on view.

The *patella* or knee-cap is a sesamoid bone, i.e., one situated entirely within tendon, in this case the tendon of the great quadriceps muscle which lies in front of the thigh and extends the knee joint. The bone is roughly triangular, apex downwards, has an upper and lower pole and anterior and posterior surfaces. The posterior surface articulates with the smooth surface of the femur just above the origin of the condyles. The quadriceps tendon is inserted into the upper pole, and the muscle pull is transmitted to the patellar ligament which connects the lower pole to the tubercle of the tibia.

**Tibia and Fibula.** These are the paired bones of the leg, on the medial and lateral sides of the limb respectively.

They articulate with each other at the superior (proximal) and inferior (distal) tibio-fibular joints; and the tibia articulates with the femur at the knee, and with the talus bone of the tarsus at the ankle. The fibula also participates in the ankle, but is excluded from the knee joint. Each bone has an opposing interosseous border, sharp margins connected by the interosseous membrane in life.

The *tibia* has a long shaft, triangular in cross-section; with medial, lateral and posterior surfaces, and medial, lateral and anterior borders. The anterior border is the sharp subcutaneous crest which can be felt as the shin from knee to ankle; and the flat medial surface is directly beneath the skin on the inner side of the leg. The upper end of the bone is expanded as two broad flat masses, the medial and lateral condyles, which articulate with those of the femur (the semilunar cartilages intervening, (see page 114). Looking down on this upper aspect of the bone, the smooth condylar surfaces are seen to be separated by a rough intercondylar area carrying the projecting tibial spine. At the upper end of the tibial crest, just below the condyles, is the prominent tibial tubercle, the ultimate insertion of the extensor apparatus of the knee joint. The lower end of the tibia is broadened to a much smaller degree than the upper; and has a downwardly projecting process, the medial malleolus, overhanging the inner aspect of the ankle.

The slender *fibula* transmits little, if any, of the body weight. Its shaft is polygonal in section, with numerous ridges for muscle attachments, and the head at the upper end articulates with the side of the outer tibial condyle. The head carries at its apex a pointed styloid process, the insertion of the biceps muscle of the thigh and the attachment of the lateral ligament of the knee. The lower end of the bone forms the lateral malleolus which overhangs the outer side of the ankle at a considerably lower level than the medial malleolus of the tibia.

**Foot.**

The bones of the foot fall into three groups corresponding with those of the hand; the *tarsals*, the *metatarsals*, and the *phalanges* of the toes. But in general, and particularly in the tarsus, they are much stronger and thicker than those of the upper limb. The *talus* lies immediately beneath the long bones, articulating with them at the ankle; and itself rests on the *calcaneus* or

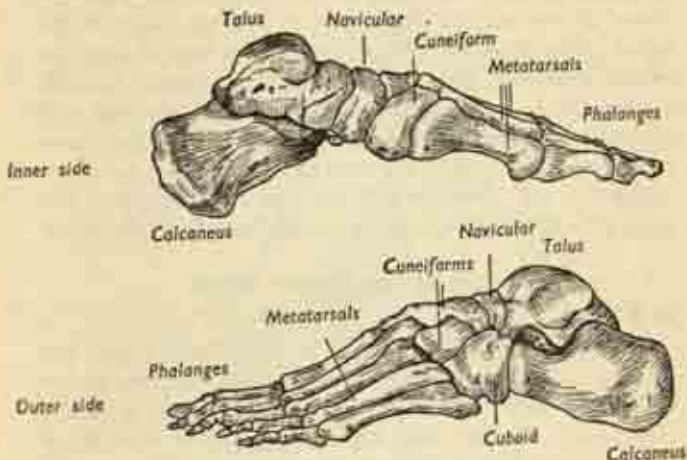


FIG. 63. The bones of the left foot.

heel bone. But the talus so inclines downwards and medially to the inner side of the foot that the anterior ends of talus and calcaneus lie almost side by side, forming the proximal row of the tarsus. The distal row consists of three *cuneiforms* on the inner side of the foot and the *cuboid* laterally; and sandwiched between the two rows on the inner side of the foot is the *navicular*, separating talus from cuneiforms.

These bones need not be discussed in great detail. The *talus* has a *body* with a rounded superior surface facing upwards at the ankle articulation; and a *neck* carrying



the globular *head*, which fits into the socket of the navicular. The *calcaneus* has a broad projecting posterior tuberosity, the prominence of the heel, set at an angle to the main body of the bone. It articulates anteriorly with the back of the cuboid. Talus and calcaneus are connected by a very strong interosseous ligament.

The *cuboid* and *cuneiforms* are irregular bony masses articulating with the bases of the metatarsals. And the latter are essentially similar to the metacarpals of the hand except that, because of the relative lack of mobility of the great toe, the first metatarsal lies closely parallel to the others. It is considerably stouter than the rest, and its head is supported underneath by a pair of tiny sesamoid bones. Note that the long axis of the foot, to which adduction and abduction of the toes are referred, is the second metatarsal and not the middle bone, as in the hand.

### Joints of the Lower Limb

#### Hip Joint.

The deeply-embedded head of the femur forms the hip joint by articulation with the acetabulum, the socket in the lateral surface of the innominate bone; as in the case of the shoulder, this socket is deepened by a fibro-cartilaginous rim or *labrum* round its periphery. And the acetabulum is so deep that its most central portion is actually out of contact with the femoral head and is not lined with cartilage but filled in by a fatty pad. In the centre of the spherical femoral head is a small crater-like depression, the *fovea centralis*, opposed to this non-articulating region of the acetabulum; and from the fovea a round cord, the *ligamentum teres*, runs to be attached to the margins of the acetabular notch; it carries blood-vessels which help nourish the head of the femur.

The capsule of the hip is extremely strong and thick, a blending of bands from each portion of the innominate bone—ilio-femoral, pubo-femoral, and ischio-femoral

ligaments. It is attached proximally around the acetabular margin; and distally it reaches right down to the base of the femoral neck in the trochanteric region, i.e., the whole of the neck is inside the capsule. The synovial membrane lining the deep aspect of the capsule is reflected upwards at the base of the neck, clothing the latter as far as the margins of the head.

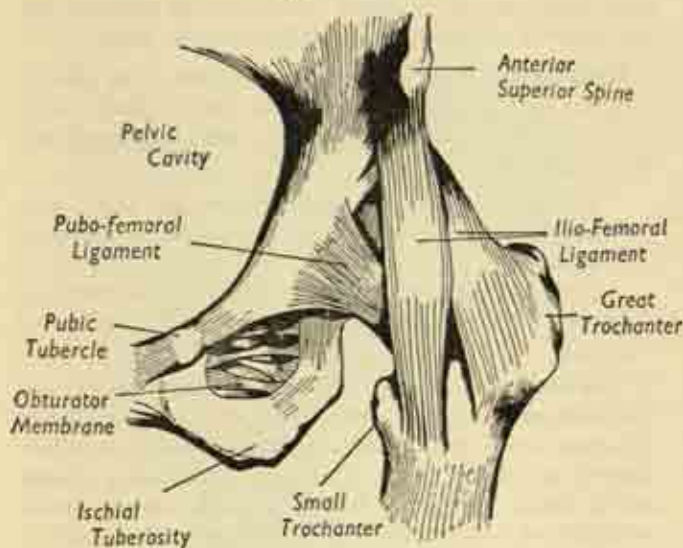


FIG. 64. Left hip joint, anterior aspect.

Movements at the hip have already been outlined at p. 57, and correspond to those of the shoulder. They are:

- (i) *abduction* and *adduction* in the coronal plane away from and towards the midline;
- (ii) *flexion* and *extension* in the sagittal plane, in front of and behind the trunk; and
- (iii) *lateral* and *medial rotation*, a rolling movement of the thigh on its long axis.

The joint is liberally supplied with nerves, some of which also serve the knee; and it is for this reason that pain from hip disease is often referred to the knee and thought to be arising from that joint. The common "fracture of the hip" in the elderly, still too often a crippling affection, is a fracture through the femoral neck; and its bad reputation for healing is due to the poor blood supply reaching the fractured surfaces via the synovial reflections and the ligamentum teres.

**Knee Joint.** This joint is very complex, with several communicating compartments; note that the fibula plays no part in the articulation, unlike the radius at the elbow. The main parts are :

- (i) the *tibio-femoral* joint between the tibial and femoral condyle of each side, a semi-lunar cartilage intervening;
- (ii) the secondary *patello-femoral* articulation between back of patella and trochlear surface of femur.

The knee is essentially a hinge joint with flexion and extension as its principal movements, the strong collateral ligaments resisting any sideways strain. But in addition there is a small element of rotation, a screwing motion which locks the joint home as it is being finally straightened out; so that in the fully-extended position in standing it is very stable compared with the tendency to "give" when flexed only a few degrees. One important feature is the manner in which the loose and extensive anterior portion of the capsule is strengthened by the expansion of the tendon of insertion of the quadriceps muscle of the thigh as it passes down in front of the joint of the tibial tubercle. There is an intimate blending of tendon and capsule, with the result that the tonus of the muscle is responsible for guarding the joint against strain, keeping the capsule taut and preventing the accumulation

of any effusion in the joint which would distend the capsule. To a much lesser extent the hamstring muscles posteriorly serve the same purpose.

This muscle-joint interrelation is of the greatest importance, as muscle wasting leads to instability; and *vice versa*, any internal derangement of the knee such as a torn semilunar cartilage causes a reflex wasting of the

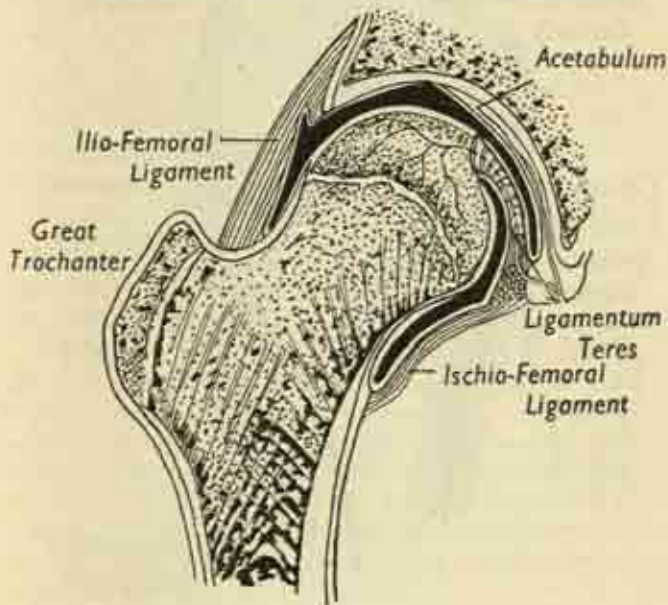


FIG. 65. Hip joint, longitudinal section. (After Gray).

thigh which predisposes to still further derangement. This vicious circle must always be broken by exercises to re-educate the quadriceps in bracing the joint straight before any improvement can be expected.

The collateral ligaments and the posterior capsule are fairly taut; but the anterior capsule is loose and extensive,

especially where it spreads up, around, and above the patella as the supra-patellar recess in front of the lower part of the femur, a pouch which is necessarily baggy to allow freedom in full flexion of the joint. When the knee is fully extended the patella articulates with the femur

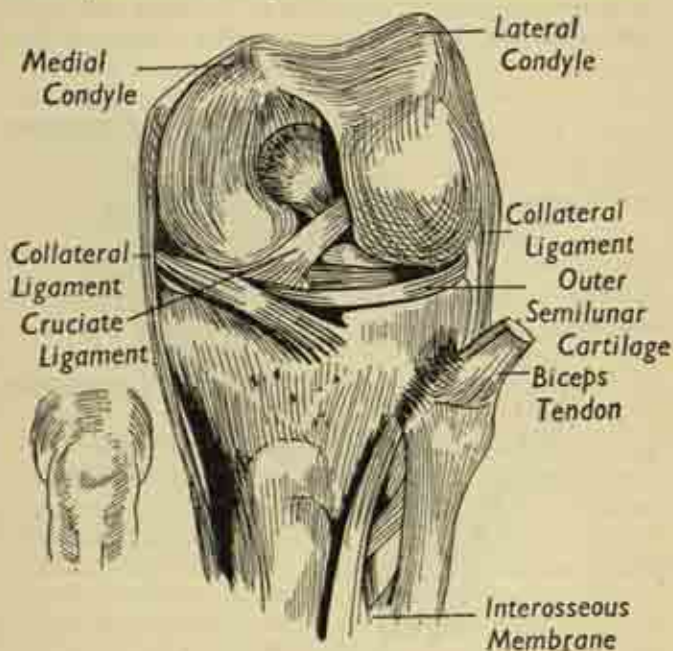


FIG. 66. Left knee joint, anterior aspect. The joint is bent at a right angle, and the front of the capsule has been removed. (After Gray).

above the condyles; in increasing flexion it lies against portions of both condyles, and corresponding facets are marked out on the back of the bone.

The *synovial cavity* of the knee is obviously complex, and includes:



(i) the *patello-femoral space*, with the supra-patellar recess in the highest part of the anterior compartment;

(ii) the main *anterior joint-cavity* between tibia and femur on each side;

(iii) the *intercondylar portion*, the tunnel between the femoral condyles, traversed by the X-like crossing of the cruciate ligaments which tie each femoral condyle to the tibia (fig. 66);

(iv) and the *post-condylar space* on each side, a loose synovial pouch behind each femoral condyle.

The *semilunar cartilages* are concentric discs intervening between the tibial and femoral condyles, and fixed to the deep aspect of the capsule (fig. 68). They are wedge-shaped in cross-section, projecting for one half to three-quarters of an inch into the centre of the joint, with a thin free edge. Their front and back ends are called the anterior and posterior horns; those of the more elliptical medial cartilage embrace those of the circular lateral disc. The two cartilages cushion the contact of the bony surfaces, and are firmly bound down at their outer margins to the upper surface of the tibia, with which they move and rotate. Nevertheless, they also have, via the capsule, an attachment to the femur, and this double fixation is responsible for the ease with which a cartilage, usually the medial, is torn or dislocated when the joint is under stress and its bony components are being distracted.

The *tibio-fibular joints* include :

(i) the superior tibio-fibular articulation, a simple plane joint formed by the fibular head abutting against the side of the lateral tibial condyle;

(ii) the connection of the shafts by means of the interosseous membrane;

(iii) the inferior tibio-fibular joint, a firm fibrous union.



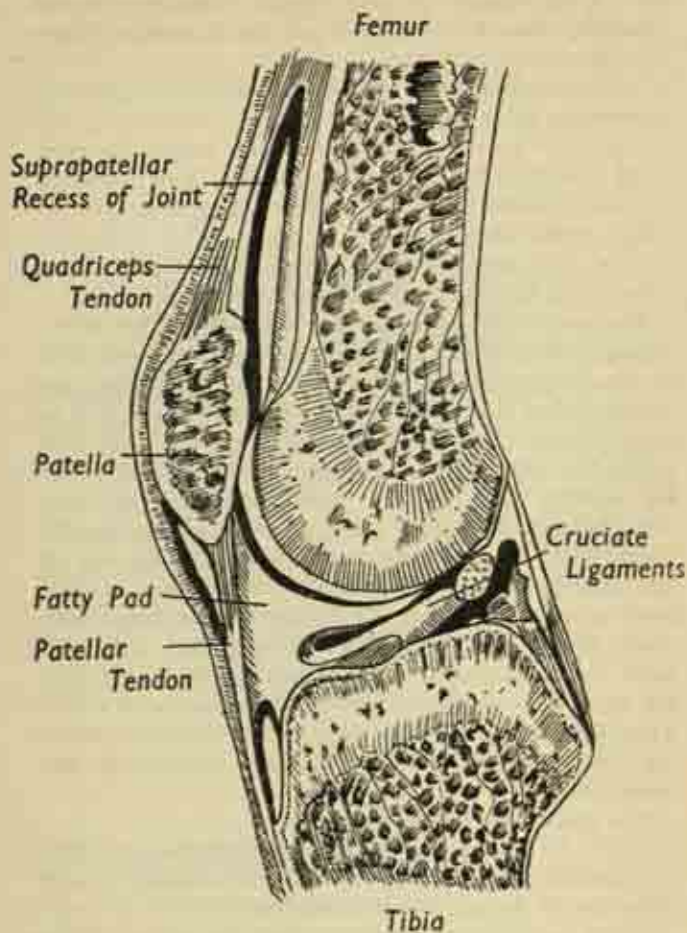


FIG. 67. The knee joint, longitudinal section. (After Gray)

Little or no motion occurs at any of these; the fibula hardly moves on the tibia and is almost entirely by-passed in the transmission of body weight, which is taken mainly in the line of the tibia.

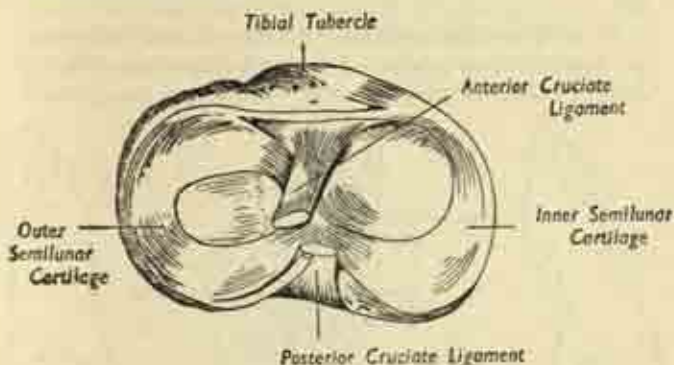


FIG. 68. Semilunar cartilages and cruciate ligaments of the knee joint. The view is of the upper surface of the left tibia, the femur having been removed.

**Ankle Joint.** This is formed between the upper surface of the talus and the lower ends of tibia and fibula; note that the latter bone is not excluded from the ankle as the ulna is from the wrist. The malleoli overhanging the talus on each side form a deep mortice in which that small bone is deeply wedged; there are strong collateral ligaments, and the only movements are those of plantar-flexion (flexion) and dorsiflexion (extension), with a neutral position at right angles.

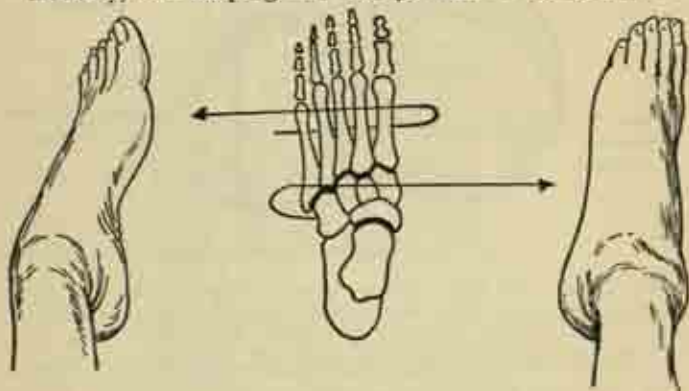
The *tarsal joints* form a complex system of inter-connecting articulations which is best considered from the point of view of the movements which actually take place.

#### Movements of the Foot.

The foot as a whole may be *inverted* or *everted*, i.e., the sole turned inwards or outwards; and this movement

is best understood by considering it as a bony block moving *en masse* at the subtaloid joint (the joint between talus and calcaneus) and the talo-navicular ball-and-socket, with the talus acting as a stationary pivot (fig. 69).

In addition, the forefoot—metatarsals and toes—may be *adducted* or *abducted*, i.e., deviated medially or laterally, but keeping the sole parallel to the ground:



#### Inversion

#### Eversion

FIG. 69. Inversion and eversion of the foot. The arrows merely indicate the direction of motion; both movements occur at the same system of joints.

this occurs at the mid-tarsal joint which traverses the foot and is made up of the talo-navicular and the calcaneo-cuboid articulations (fig. 70).

In actual practice, it is not possible to separate all these movements; inversion of the sole is always accompanied by some adduction of the forefoot, and eversion by some abduction, the movements of the subtaloid and the mid-tarsal joints being reciprocal. And it is difficult at first to realize that none of these rotary movements is occurring at the ankle; inversion in particular appears to be

taking place at ankle level. In fact they all occur well below the level of the ankle, which is capable of simple up and down movement only.

The remaining tarsal joints are small plane articulations of an accessory nature, and the joints of the toes are similar to those of the fingers; with the slight difference that the central axis of reference for abduction and adduction is the second metatarsal and toe and not the third as in the hand.

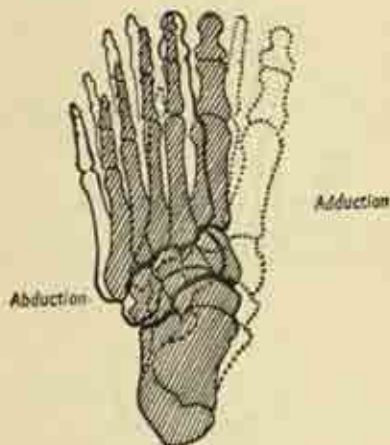

FIG. 70. Abduction and adduction of the fore-foot. The shaded position is neutral, the outlines indicate the extremes of range.

### The arches of the Foot.

These are longitudinal and transverse. The *longitudinal arches* lie in the long axis of the foot, with a higher medial long arch and a lower lateral long arch, both having a common posterior pillar in the calcaneus. But they diverge anteriorly. The line of the medial arch is calcaneus-talus-navicular-cuneiforms-inner three metatarsals. The line of the outer is calcaneus-cuboid-outer two metatarsals, this arch being much the flatter. The

talus thus lies at the summit of the long arches of the foot, so that the body weight transmitted to it down the leg is constantly tending to flatten them out, and would do so were it not for the supporting ligaments and muscles.

The *transverse arch* is the natural downward side-to-side concavity seen in cross-section, and is most marked in the region of the bases of the metatarsals.

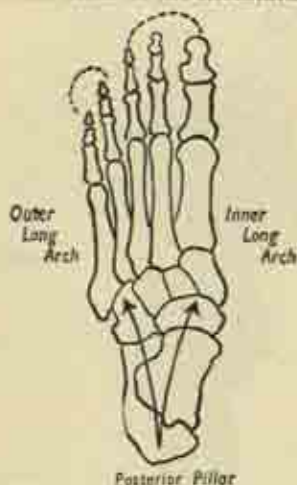


FIG. 71. Longitudinal arches of the foot.

The long arches are not present at birth but develop with activity in the first 18 months; the transverse arch is already present in the foetus. A great deal has been written in the past about the importance of the arches to the efficient functioning of the foot which is no longer altogether accepted. "Flat foot" in itself is of little importance; what matters is that the foot should be supple, and capable of assuming the arched position voluntarily when relieved of body weight. This is the state of affairs in children and ballet dancers, who have

excellent function although their feet may be very flat. It is rigidity that is painful and disabling, whether in the arched or the flat position; and some of the most troublesome feet are the very highly arched variety which are just beginning to break down.

What are the supports of these arches? They are two, the binding ligaments and the tone of certain muscles

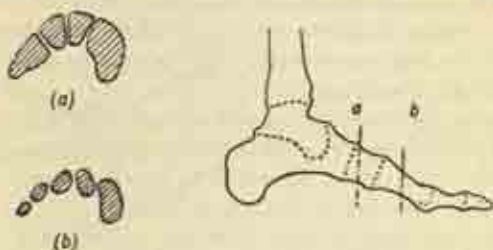


FIG. 72. Cross-section of the transverse arch of the foot, (a) in the tarsal, (b) in the metatarsal region.

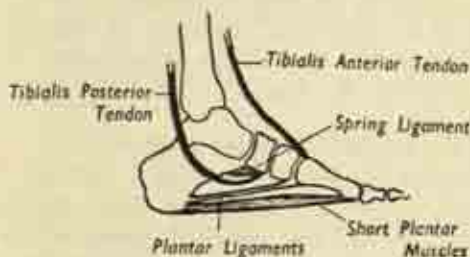


FIG. 73. Ligaments and tendons supporting the longitudinal arches of the foot.

of the calf and the sole; and the latter is the more important. To a certain extent also, the actual shape of the bones contributes to the maintenance of a normal arch. The *ligaments* of greatest importance are of course those on the concave underside of the foot, the ties of the arches—either short bonds between individual bones, or



longer structures running from one pillar of the arch to the other.

The tendon of the *tibialis anterior* muscle runs down from the front of the leg to pull on the medial cuneiform and thus actively maintain the long arch; the tendon of the *tibialis posterior* of the calf curves round behind the ankle, and sustains the head of the talus from below as it passes to its insertion in the navicular. And the *peroneus longus* tendon from the outer side of the leg crosses the sole of the foot transversely from lateral to medial side, bracing the transverse arch.

Finally, the muscular mass of the sole, the short plantar muscles which are attached behind to the underside of the calcaneus and spread forwards to the toes, exert a constant tonic support for both long arches.

It is important to note that the ligaments are never intended to take the entire strain of body weight, except perhaps momentarily; they are themselves guarded by the tone of those calf muscles whose tendons have been mentioned above as supports for the arches. If this tonus is weakened by fatigue or paralysis the ligaments are overstretched and an acute foot strain results, the first stage of a chronic flat foot.

### **Gait and the mechanism of the Foot.**

The arches are springlike structures, yielding slightly under body weight in walking and then exhibiting an elastic recoil; indeed the principal ligament, the short plantar band between calcaneus and navicular which directly supports the head of the talus, is known as the spring ligament. In taking a step, the weight is first planted on the heel, then transmitted rapidly along the outer border of the foot, and finally across the transverse arch to be borne by the first metatarsal head; and flexion of the metatarso-phalangeal joints gives a propulsive kick-off on to the other foot. The remarks on p. 100

about primitive and fine movements of the fingers apply, though with less force, to the toes also. In walking on rough pebbly ground, particularly with naked feet, the long flexors of the toes act as powerful gripping agents to steady the balance. But on smooth pavements and in stout shoes it is necessary to bring the toes flat down on the bearing surface to give an efficient thrust, and this is

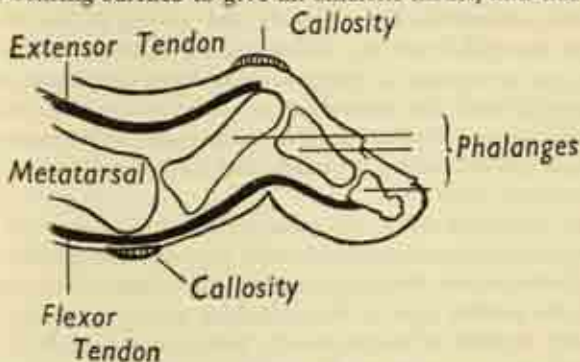


FIG. 74. The clawed toe resulting from loss of intrinsic control, accomplished by the intrinsic muscles. Should this intrinsic control be lost, the unopposed long flexors and extensors produce clawing of the toes, which are hyperextended at the metatarso-phalangeal, and flexed at the interphalangeal, joints. This exposes the metatarsal heads in the sole; walking gives the painful sensation of treading on stones; and callosities form both in the sole and on the dorsum of the toes over the prominences (fig. 74).

### Surface anatomy of the Leg.

Bearing in mind the underlying bony structures, we can now review the surface anatomy of the lower limb.

#### Anterior aspect.

The deep fold of the groin marks the transition between abdominal wall and thigh; pressure in this fold

reveals the resistance of the underlying inguinal ligament, which can be traced laterally to the anterior superior spine of the ilium and medially to the small knobby pubic tubercle; the latter is often obscured in men by the overlying spermatic cord running down to the testicle.

Immediately distal to the ligament is the *inguinal region*, which the main vessels and nerves of the limb have entered from the abdomen; the pulsation of the femoral artery can be felt just below the midpoint of the ligament, and the femoral nerve rolled under the finger a little more laterally. In this region also are numerous lymph glands, often enlarged and felt as soft rounded structures. (Plate 7.)

In the *thigh* itself the main anterior muscle bulge is formed by the quadriceps femoris, tapering down towards its insertion into the upper pole of the patella. The mass on the medial side is the adductor group of muscles, whose tendons of origin can be felt running up to their attachment to the pubic bone, just lateral to the external genital organs. When the knee is braced straight, a very firm resistance is felt under the skin on the outer aspect of the thigh, extending from hip to knee; this is the ilio-tibial band of the deep fascia which is kept taut by certain of the buttock muscles and helps in maintenance of the erect posture.

At the front of the *knee*, the patella is seen and in line with it, a couple of inches below, the tibial tubercle; the patellar tendon connecting the two and transmitting the quadriceps pull becomes obvious when the knee is extended, and a hollow on either side of the tendon indicates where the anterior joint compartment lies immediately beneath the skin. The tibial condyles are easily seen or felt, and the head of the fibula on the outer aspect; just below the head, the peroneal nerve winds round the neck of the fibula, over which it can be

rolled, giving rise to a tingling sensation in the outer side of the calf.

The *tibial crest*, its anterior border or shin, is subcutaneous from tibial tubercle to ankle, curving slightly inwards as it passes down, with the flat subcutaneous medial surface on its inner side. On the outer side of the crest is the bulge of the muscles in the anterior compartment of the leg, and more laterally still the peroneal muscles obscure the underlying fibula, which emerges under the skin a few inches above the ankle.

At the *ankle* the two malleoli stand out on either side, the medial malleolus at a higher level; and an inch behind the latter can be felt the pulsation of the posterior tibial artery.

The *navicular* often makes a prominence on the medial border of the foot, as does the base of the fifth metatarsal on the outer side; and the joint between the medial cuneiform and the base of the first metatarsal is often a troublesome dorsal prominence under the shoe.

### Posterior aspect.

The great muscle masses at the back of the limb are, from above downward: the gluteal muscles of the buttock; the hamstrings in the thigh; and the calf muscles of the leg.

The *buttock* has a rounded *gluteal fold* below, marking its junction with the thigh, and as this is followed round to its lateral extremity there is felt under the skin the resistance of the great trochanter. Deep in the lowest point of the buttock is felt the apex of the ischial tuberosity.

At the back of the *knee*, the tendons of the hamstrings diverge; they can be seen or felt as the biceps passes down and out to the head of the fibula, the semimembranosus and semitendinosus down and in to the tibia. These tendons make the upper boundaries of the diamond-

shaped space behind the knee joint, the *popliteal fossa*, in which lie the great vessels which have travelled round from the front of the thigh in its lower third, as well as the sciatic nerve and its divisions. It may be possible to feel these structures by deep palpation, though the course of the sciatic nerve in the thigh itself is entirely protected by the overlying muscle.

The bulk of the *calf* is made up of the triceps, i.e., the gastrocnemius and soleus muscles, which taper down as they joint to form the Achilles tendon or heel-cord passing down the back of the ankle to the tuberosity of the calcaneus.

The surface markings of the main vessels and nerves are indicated in Plates 3 and 4. Note the spiral course of the femoral artery and vein round the inside of the femur to reach the back of the limb in the popliteal fossa; and the straight course of the sciatic nerve down the middle of the back of the thigh to divide in two a few inches above the knee, the lateral peroneal division winding round the neck of the fibula to reach the front of the leg.

### **Subcutaneous structures of the leg.**

Fig. 75 displays the flayed limb, with the superficial structures which intervene between the skin and the envelope of deep fascia. The *venous network* is gathered up into two main channels. The *great saphenous vein* runs upwards in front of the medial malleolus, along the medial border of the leg and thigh, and finally turns round to the front of the inguinal region where it passes through an oval window in the deep fascia to join the main *femoral vein*. The *small saphenous vein* is formed on the lateral side of the foot, passes upwards behind the lateral malleolus, and travels up the midline of the back of the calf as far as the knee, where it pierces the deep fascia to join the *popliteal vein*.



Both veins are accompanied by lymphatic vessels; there are a few small popliteal lymph glands at the termination of the small saphenous vein, and numerous

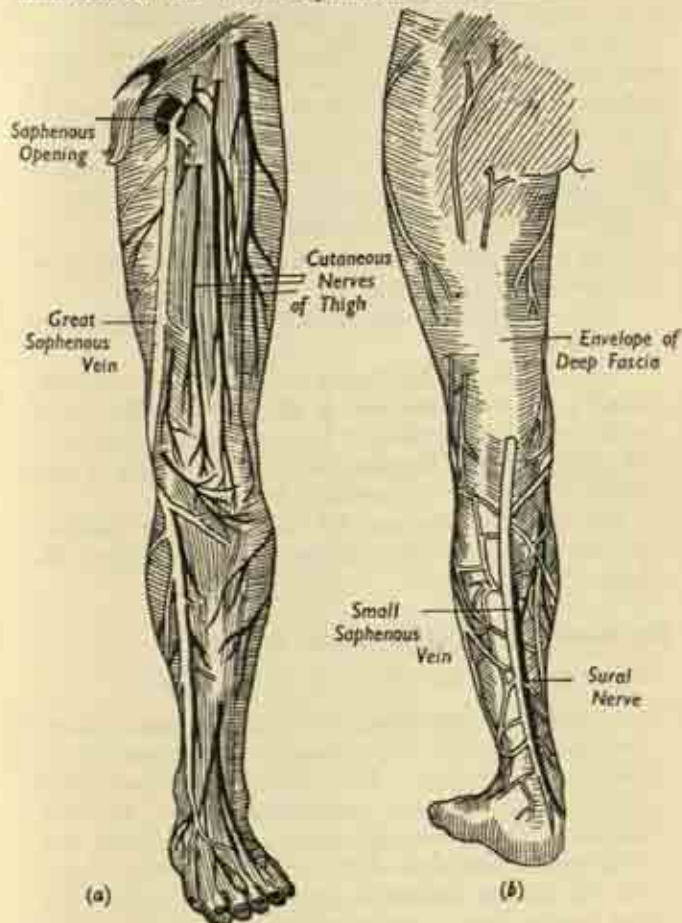


FIG. 75. The flayed lower limb (a) anterior, (b) posterior.



large inguinal glands surrounding the upper part of the main saphenous trunk at the groin.

The *cutaneous nerves* of the limb are many. The front of the thigh is supplied by lateral, intermediate and medial branches from the *femoral nerve*; the back by a small sciatic branch of the main *sciatic trunk*. The *saphenous* branch of the femoral nerve runs the whole length of the limb in company with the great saphenous vein; and the *sural* branch of the sciatic accompanies the small saphenous vein to the outer side of the foot.

The main subcutaneous *bursæ* in the leg are:

(i) a bursa between skin and ischial tuberosity to relieve pressure in sitting;

(ii) a bursa over the lateral aspect of the great trochanter;

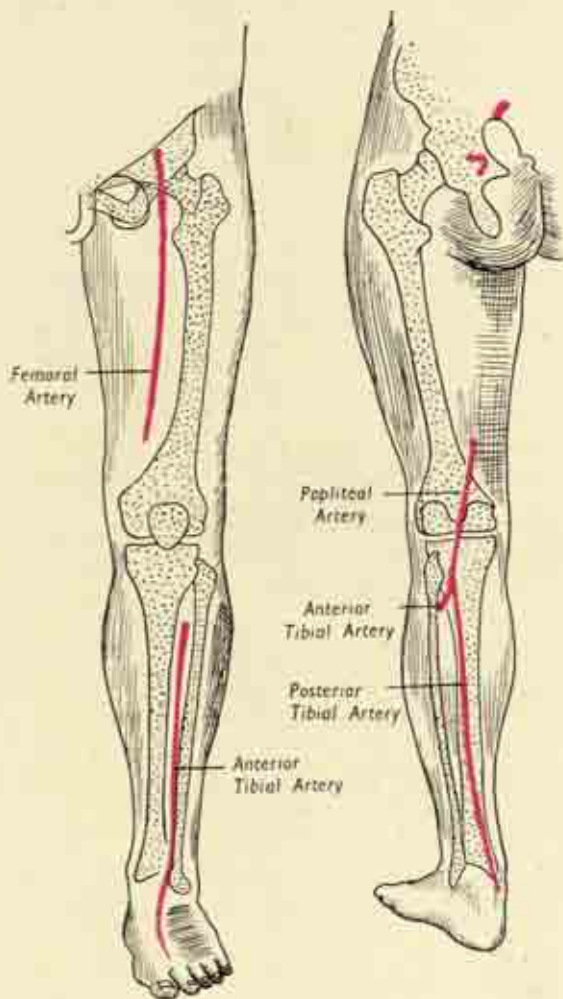
(iii) the pre-patellar bursa in front of the patellar tendon and the lower half of the patella. This is not a part of the knee joint, it takes a considerable share of the weight in kneeling, and its distension is the cause of ordinary "housemaid's knee";

(iv) a bursa between the skin and the Achilles tendon—when the shoe has been rubbing against the heel.

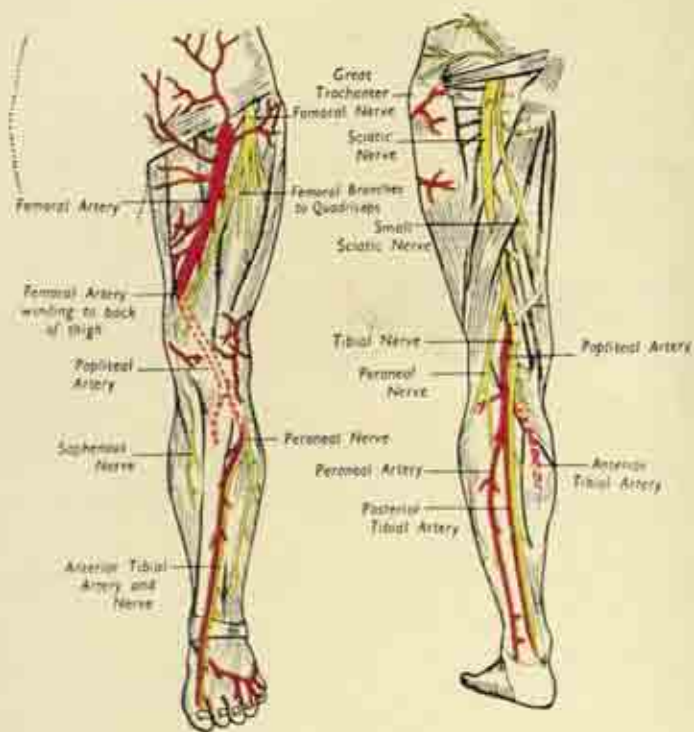
### The muscles of the upper part of the leg.

These consist of the following main groups:

(i) *Muscles connecting trunk and femur*: *iliacus* and *psoas* (fig. 78). These muscles are responsible for flexing the hipjoint. The *iliacus* is a broad sheet arising from the inner (pelvic) surface of the iliac portion of the innominate bone; while the *psoas* is a long belly at the back of the abdominal cavity alongside the lumbar vertebrae, from which it arises. The two muscles form a conjoined *ilio-psoas tendon* which enters the thigh by passing under the inguinal liga-



Surface marking of the arteries of the lower limb,



Plan of the main nerves and vessels of the lower limb.

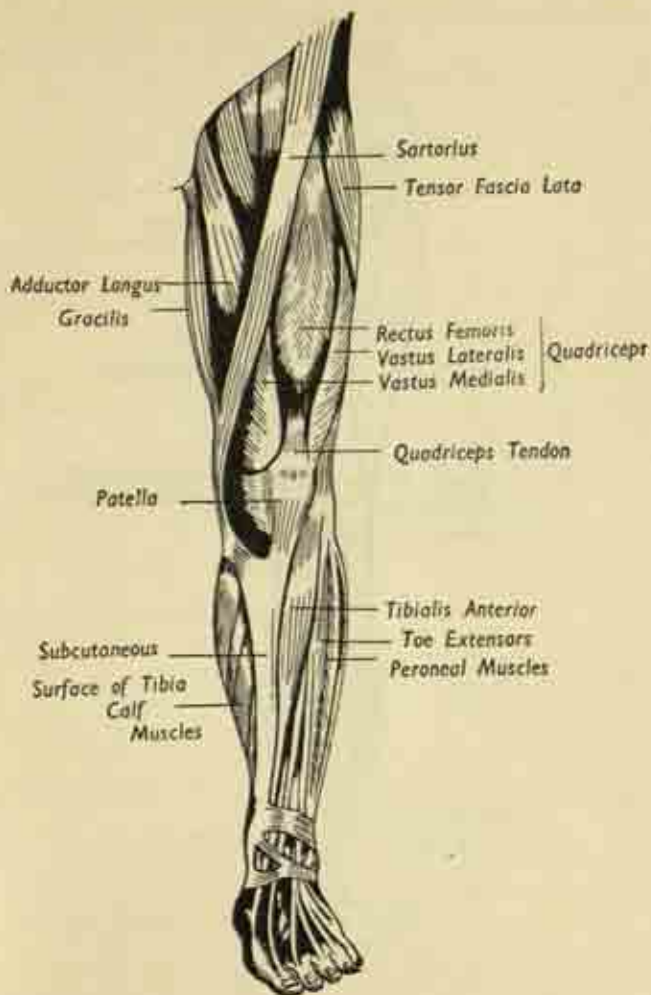


FIG. 76. Muscles of the left lower limb. Anterior.

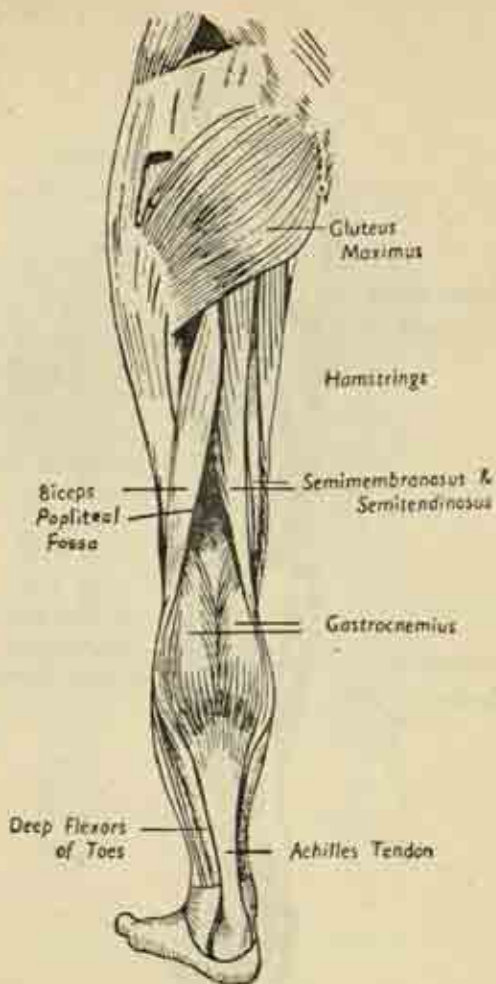


FIG. 77. Muscles of the left lower limb. Posterior aspect.

ment lateral to the femoral vessels, and so to its insertion at the lesser trochanter.

(ii) *Muscles connecting pelvis and femur.* There are two main groups here, the gluteals and the adductors.

The *gluteal* muscles of the buttock arise from the outer surface of the ilium and from the back of the sacrum. The most superficial, covering all the others,

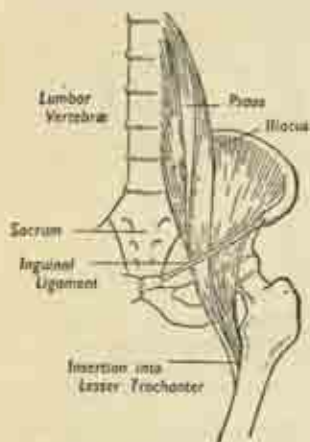


FIG. 78. Ilio-psoas group of muscles, left side.

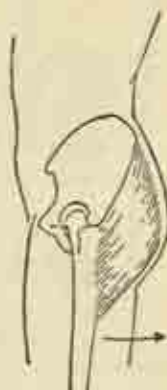

FIG. 79. Action of gluteus maximus.

is the great *gluteus maximus*, the rump, which is inserted partly into the gluteal tuberosity of the femur and partly into the ilio-tibial band of deep fascia. It is one of the most important postural muscles, for it extends the hip, carries the leg backwards in walking, and braces the whole limb by tightening up the deep fascia.

Under cover of it are the smaller *gluteus medius* and *minimus*, which are the main abductors of the hip away from the midline. These are again of the highest postural importance in that they make it possible to



stand on one leg by pulling the pelvis over in line with the weight-bearing limb, and they resist the tendency of the trunk to fall to the other side. They thus make walking possible, for this is no more than an alternate standing on either leg (fig. 80).

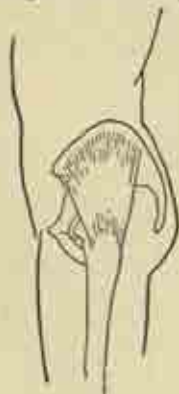

FIG. 80 (a). The gluteus medius.

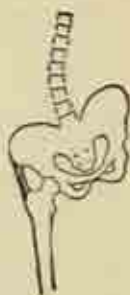

FIG. 80 (b). The stabilizing action of the gluteus medius in standing on one leg.

The *adductors*—*longus*, *brevis* and *magnus*—lie on the inner side of the thigh. They arise by tendons from the pubic tubercle, pubis and ischium, running downwards and out to be inserted into the shaft of the femur as far down as the adductor tubercle. And their action is clearly to adduct the femur to the mid-line. The three muscles are arranged in layers from before backwards as named, and are supplied by the *obturator nerve* which enters this region of the thigh from within the pelvis after piercing the obturator membrane. One strap-like member of this group, the *gracilis*, reaches as far as the tibia.

(iii) *The short rotators of the hip*, analogous to those of the shoulder, are situated very deeply in the buttock, in close relation with the sciatic nerve, and

are seen only after removal of all the overlying gluteal muscles. They arise from the sacrum and obturator membrane, insert into the base of the femoral neck, and laterally rotate the hip.

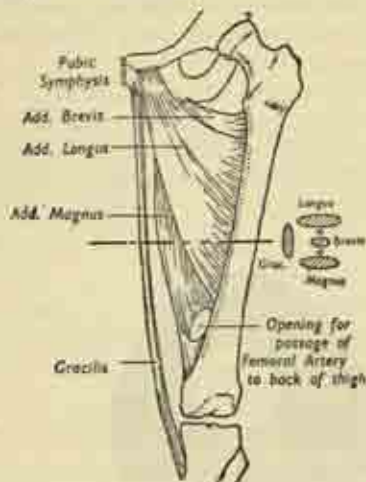


FIG. 81. Adductor muscles of the left thigh. Their disposition is also shown in cross-section, with the two branches of the obturator nerve sandwiched between the layers.

(iv) The *quadriceps femoris* is the great mass on the front of the thigh responsible for extension of the knee. Three heads arise from the femur—the *vastus lateralis*, *intermedius* and *medialis*—and the fourth is the *rectus femoris* from the ilium just above the acetabulum. We have seen that there is a common quadriceps tendon emerging in the lower thigh and inserted into the upper pole of the patella; its expansions on either side of the patella blend with, and greatly strengthen, the capsule of the knee joint.

(v) The *sartorius* is a long strap-like muscle arising

from the anterior superior spine of the ilium and traversing the length of the front of the thigh very superficially in a downwards and inwards direction to its insertion in the upper tibia on its subcutaneous aspect. It helps to flex both hip and knee, and to produce the movement of sitting with crossed legs, the "tailor's position" after which it is named.

(vi) The *hamstrings* are the bulk of the back of the thigh, a powerful group arising from the ischial tuberosity and destined to flex the knee by inserting into the tibia and fibula. These muscles are the *semi-mem-*

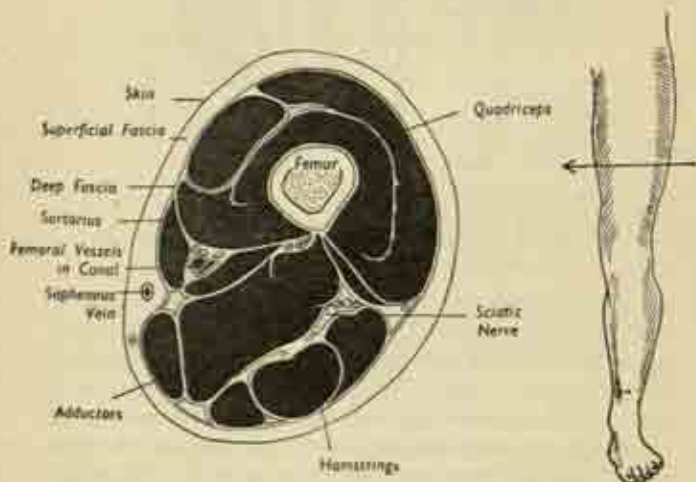


FIG. 82. Cross-section of left thigh, viewed from below, to show the muscle masses.

*branosus*, *semi-tendinosus* and the *biceps*, which diverge in their passage down the thigh; the first two pass inwards to the upper tibia, while the biceps, which acquires an additional head from the back of the femur, is inserted on the outside of the knee into the head of the fibula. This  $\Delta$ -shaped arrangement of

the tendons produces the upper boundary of the diamond shaped popliteal fossa at the back of the knee, the lower sides of the diamond being the two heads of the gastrocnemius muscle. The sciatic nerve, which lies in the thigh under cover of the hamstrings, emerges between the fork of their tendons to lie comparatively

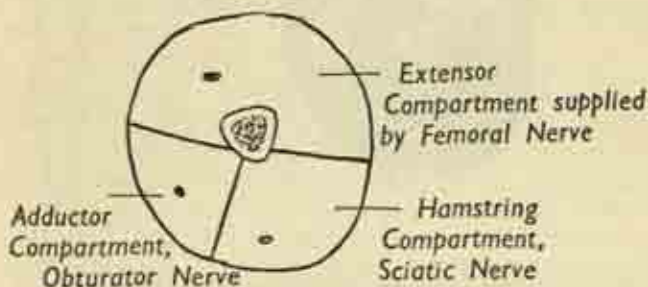


Fig. 83. Key to fig. 82.

The three compartments of the thigh, with their nerves.

superficially at the apex of the popliteal region. The space is roofed over by deep fascia and has the popliteal surface of the femur as its bony floor.

The disposition of all these muscle groups in the thigh is clearly shown in cross-section (figs. 82, 83). The inter-muscular septa of deep fascia mark off three compartments, each containing a muscle group with its supplying nerve, which also innervates the overlying skin. The anterior or extensor compartment contains the *quadriceps*, supplied by the femoral nerve; the medial contain the *adductors*, supplied by the obturator nerve; and the posterior the *hamstrings*, supplied by the sciatic.

Note how the sartorius in its diagonal course is so applied to the side of the vastus medialis as to produce a tunnel-like space; this is *Hunter's canal*, and through it pass the femoral vessels on their journey round the femur

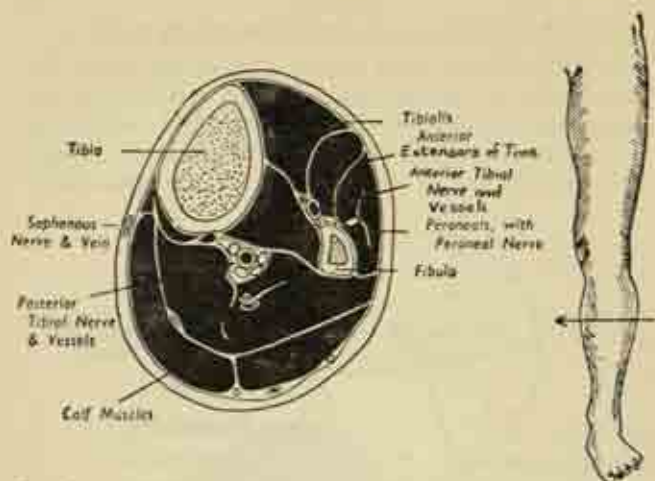


FIG. 84. Cross-section of left lower leg, seen from below, showing the main muscle masses.

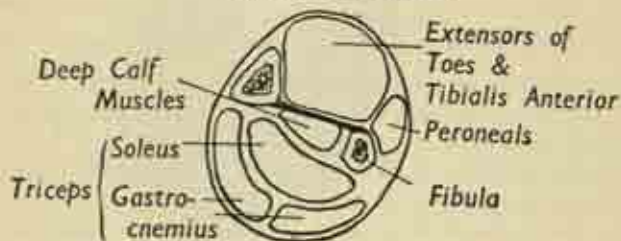


FIG. 85. Key to fig. 84. Compartments of the lower leg. to emerge in the popliteal fossa behind, where they are then called the popliteal artery and vein.

### The muscles of the lower leg.

Cross-section of the leg reveals the main compartments and muscle groups as follows. The interosseous membrane between the bones separates a main *anterior compartment*, containing the muscles which extend the ankle and toes, from the *posterior compartment* for the

calf muscles; and there is a small separate *lateral compartment* on the outer side of the fibula for the peroneal muscles which evert the foot. Finally, the main posterior compartment is subdivided into a *superficial* portion for the gastrocnemius and soleus (together forming the triceps); and a *deep* portion for the long flexors of the toes and the tibialis posterior which inverts the foot.

**The anterior group:** *tibialis anterior, extensor hallucis longus, extensor digitorum longus*. These are all extensor muscles supplied by the anterior tibial division of the peroneal nerve. Their tendons run down in front of the ankle, where they are bound down by the retinacular bands of deep fascia. The tibialis anterior, on the medial side, is inserted into the first metatarso-cuneiform junction, where it helps to maintain the inner long arch (fig. 73) and dorsiflexes the foot. The extensors of the toes and of the great toe (hallux) traverse the dorsum of the foot to be inserted in the same way as the corresponding tendons in the hand. With this difference, that in the foot there is a duplicate set of extensor tendons arising from a short extensor muscle situated on the dorsum of the foot itself.

The *peroneal* muscles, longus and brevis, evert the foot and act incidentally as dorsiflexors of the ankle; they are supplied by the peroneal nerve. P. brevis has a short course to the base of the fifth metatarsal (the styloid process of that bone); whereas p. longus dives into the sole at that point and runs transversely to reach the base of the first metatarsal, so helping to maintain the transverse arch. Both tendons pass round the back of the lateral malleolus to reach the foot, and they have a constant tendency to slip forward round the edge of that bone which is resisted by a special peroneal retinaculum.

**The posterior group:** (i) *Superficial layer: triceps*.

The triceps is the great calf muscle acting to flex



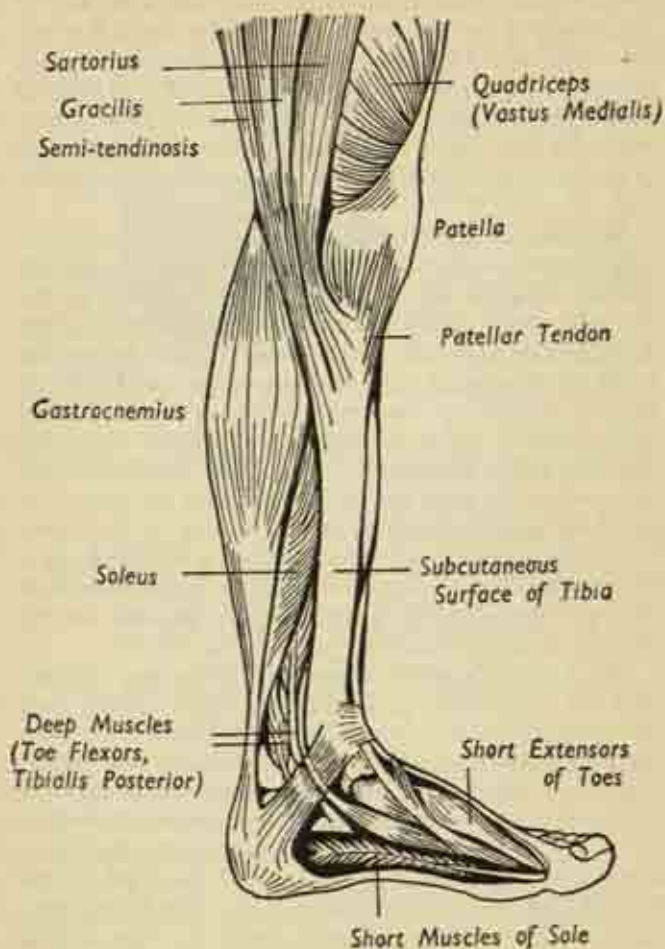


FIG. 86. Muscles of left lower leg and foot, inner aspect.

(plantarflex) the foot through its insertion, via the Achilles tendon, into the tuberosity of the calcaneus. It comprises the superficial *gastrocnemius*, with a head arising from the back of each femoral condyle and forming the lower V-shaped boundary of the popliteal fossa; and the underlying *soleus* arising from the back of the upper tibia and fibula. These form the Achilles tendon halfway down the calf, and the tendon is separated from the upper part of the back of the calcaneus by a deep bursa.

(ii) *Deep layer. tibialis posterior, long flexors of the toes.* These arise from the back of the tibia and fibula and the connecting interosseous membrane. The emerging tendons enter the sole of the foot by passing behind the ankle joint and the medial malleolus. The long flexors are attached to the toes, as in the case of the similar flexor digitorum profundus in the arm. But whereas the fingers have two sets of flexor tendons, both arising in the forearm, those of the calf correspond only to the profundus and the duplicate tendons are supplied by a short flexor muscle which is confined to the sole of the foot. The tibialis posterior is inserted into the navicular and sustains the inner long arch,

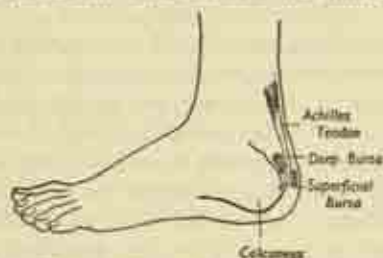


FIG. 87. Achilles tendon and related bursae.

taking some weight off the spring ligament by supporting the head of the talus; it is a powerful inverter of the foot as well as a plantarflexor of the ankle.

**The Foot.** The general arrangement of the foot and toes, the flexor and extensor tendons and their synovial sheaths, etc., resembles that of the hand, but with local differences due to the complete duplication of the long flexor and extensor tendons by short extensors and flexors situated in the dorsum and sole of the foot itself, and arising from the upper- and under-surfaces of the calcaneus.

The deep plantar fascia of the sole is very dense, and covers a complex pattern of small plantar muscles arranged in layers.

**The blood-vessels of the lower limb.** (Plates 3, 4, 7.)

The femoral artery and vein are the downward continuation of the external iliac vessels from within the pelvis. They enter the thigh by passing beneath the inguinal ligament, carrying with them a femoral sheath prolonged from the deep fascia of the abdomen, and lie in the groin with the vein medial to the artery. Their course in the thigh lies in three parts: in the upper third, in the inguinal region; in the middle third, in Hunter's canal, under the sartorius muscle; and in the lower third, they pass round the back of the femur close to the bone, to enter the popliteal fossa as the popliteal vessels. In the thigh, the artery has a number of branches which encircle the femur and supply the muscle masses; and it divides in the lower part of the popliteal fossa into an anterior and posterior tibial division. The *posterior tibial* continues the main line of the vessel down into the calf, where it lies close to the back of the interosseous membrane, enters the sole behind the medial malleolus in company with the flexor tendons, and supplies digital arteries to the toes via an arch similar to the one we have seen in the hand. The *anterior tibial* passes forward from the popliteal fossa, through the interosseous membrane, into the anterior compartment

of the lower leg; runs down the front of the membrane, emerging on the dorsum of the foot with the extensor tendons to give branches to the toes.

The main branches of the venous trunk are similar, save that the venous pattern to the toes is much more superficial and inconstant in arrangement.

### The nerves of the leg.

(Plates 4, 7.) The *femoral* and *sciatic* nerves are the two great anterior and posterior trunks, and these, with the *obturator* and certain other twigs, are derived from the *lumbo-sacral plexus* of spinal nerve roots situated within the abdomen and pelvis.

The *femoral nerve* enters the thigh beneath the inguinal ligament to the lateral side of the femoral vessels, and very soon breaks up into the following branches :

- (i) the lateral, intermediate, and medial cutaneous nerves of the thigh;
- (ii) muscular branches to the quadriceps femoris;
- (iii) twigs to the hip and knee joints.

The *obturator nerve* enters the medial adductor compartment of the thigh from within the pelvis by piercing the obturator membrane; it supplies the adductors, the overlying skin, and the knee joint.

The *sciatic nerve* is formed within the pelvis, on the deep aspect of the sacrum; emerges into the buttock, where it lies deeply among the small rotator muscles under cover of the glutei; and runs vertically down the limb to the popliteal fossa, where it divides into medial (*tibial*) and lateral (*peroneal*) branches. In the upper part of the thigh it lies midway between ischial tuberosity and great trochanter; is covered over by the hamstrings in the midthigh; and is revealed more superficially where the hamstring tendons diverge to their insertions.

The *tibial nerve* continues the straight course of the sciatic from the upper angle of the popliteal fossa to the

lower, lying fairly superficially under the deep fascia and crossing diagonally over the deeper popliteal vessels; it supplies the calf muscles, forming a common neuro-vascular bundle with the posterior tibial artery, with which it enters the foot to supply the intrinsic muscles and the sensory branches to the toes.

The *peroneal* branch follows the biceps-tendon closely to the head of the fibula; winds superficially round the lateral aspect of the neck of that bone; gives a superficial branch to the peroneal muscles and the skin over the lateral side of the calf; and continues as the anterior tibial nerve in company with the anterior tibial artery in the extensor compartment. Here it supplies the extensor muscles, enters the dorsum of the foot, and gives digital branches to the dorsum of the toes.

## CHAPTER VII

### ABDOMEN

#### **Abdominal cavity and boundaries.**

THE abdominal cavity is the largest of the body spaces and even more extensive than is at first obvious, for its roof, the diaphragm, reaches high into the bony thorax under cover of the lower ribs; in fact, the ribs enclose a part of the abdominal cavity almost equal to that of the whole thoracic cavity itself.

The right and left domes of the diaphragm separate the base of the right and left lungs above from the corresponding lobes of the liver below, with the heart and pericardium sitting on the flat middle part of the partition. In full expiration, on breathing out as far as possible, the right dome of the diaphragm is at the level of the fifth rib, just below the nipple, and the left is an inch lower.

It is necessary to distinguish between the *abdomen proper*, which contains the main digestive organs, bowel, liver, pancreas, and spleen, the kidneys, suprarenals and great vessels; and the *pelvic cavity* below, enclosed by the innominate bones, containing the termination of the bowel, the bladder and genital organs. The two cavities are freely continuous at the pelvic inlet, which forms as it were a deficiency in the floor of the main abdominal cavity. And a longitudinal section through the trunk shows how the main axes of the two cavities are set at such an angle that there is a considerable backward inclination of the pelvis, whose organs in consequence are relatively separate from those in the abdomen proper.

Unlike the cranial and thoracic cavities, the abdomen



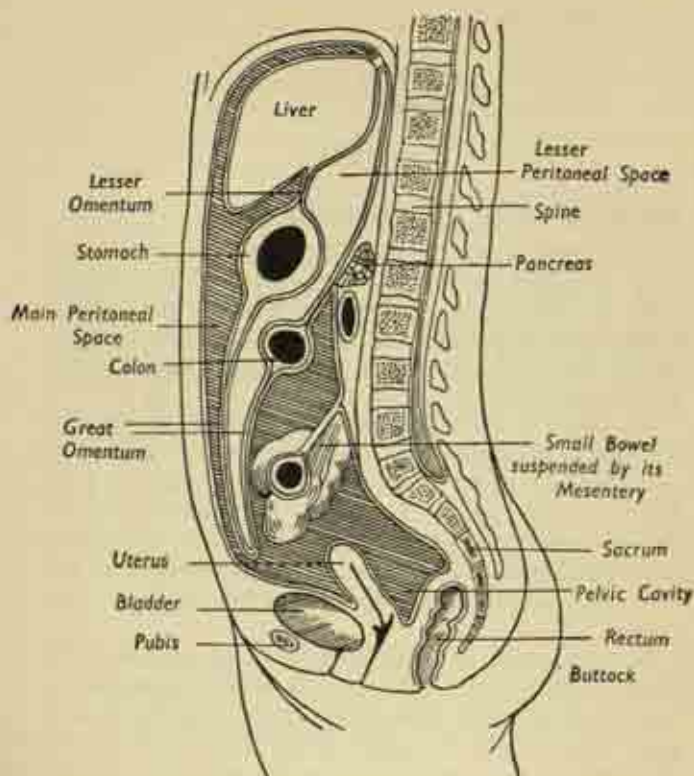


FIG. 88. Longitudinal section of the (female) abdomen, showing the distinction between pelvic cavity and abdomen proper.

is relatively unprotected by bony framework, though this is compensated for to some extent by a strong muscular belly-wall anteriorly and in the flanks.

The boundaries of the abdomen are :

(i) *behind*, the lumbar vertebræ of the spinal column, clothed by the psoas and quadratus lumborum

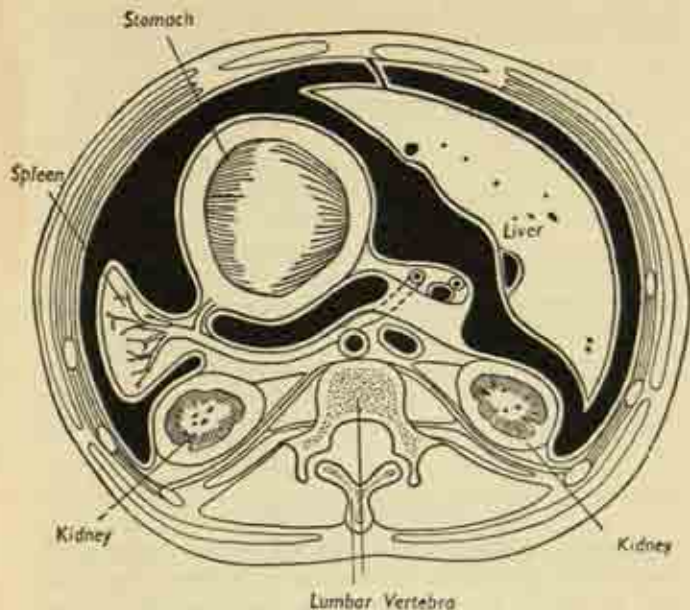


FIG. 89. Cross-section of the abdominal cavity. Note the recess on either side of the vertebral column in which each kidney lies. The large black space is the greater sac of the peritoneal cavity; the lesser sac is the small space immediately behind the stomach.

muscles, which help to form the actual posterior wall of the cavity;

(ii) *in front and at the sides*, the muscles of the flank and anterior abdominal wall;

(iii) *above*, by the diaphragm; and

(iv) *below*, on each side, the iliac fossæ of the innominate bone, clothed with the iliacus muscles, support part of the abdominal contents.

The cavity is lined by a serous membrane, the peritoneum (p. 154) which also clothes most of the contained organs, the viscera; these peritoneal surfaces are normally

in close contact and the cavity is thus only potential, unless air is admitted by operation or injury, when the organs fall away from each other. Note also, in cross-section, how the vertebral column encroaches forward so that it can be easily felt through the anterior abdominal wall, leaving a great bay on either side of the posterior abdominal wall in which lie the kidneys.

There is considerable respiratory excursion in the abdomen; on inspiration, the diaphragm is considerably lowered as the lungs expand, with corresponding effects on the abdominal organs, the liver descending 2-3 inches with a deep breath. This is less conspicuous in the lower-placed organs; and the cavity constantly varies in size with contraction and relaxation of its muscular walls and the degree of distension of the hollow viscera.

### Surface anatomy

**Anterior abdominal wall.** In the surface anatomy of this region, the main points are as follows. On each side superiorly the *costal margins*, the lower borders of the ribs, form a  $\wedge$ -shaped angle whose acuteness varies with the general build of the individual. At the apex of this angle, and rather depressed below the surface, is the tip or *xiphoid process* of the sternum. The *umbilicus* or navel is in the midline, on a level with the fourth lumbar vertebra behind; it is the scar marking the former attachment of the umbilical cord joining foetus to placenta. In the lowest part of the midline anteriorly is the *pubic symphysis*, formed by the junction of the two halves of the pelvis. Xiphisternum, umbilicus and symphysis are all connected by a tough strip of deep fascia, the *linea alba*, a very firm central attachment for the muscles whose aponeuroses intersect at this point. When these muscles are contracted, the linea alba is seen as a central depression between the prominent *rectus* muscle

on either side; and the belly of the latter is crossed by 2-3 transverse intersections.

Inferiorly, the symphysis can be traced out to the pubic crest on each side, and then the *inguinal ligament* spanning across from pubic tubercle to anterior superior iliac spine marks the junction between abdomen and thigh; from the iliac spine the *iliac crest* can be followed round to the back.

The surface of the anterior abdominal wall is divided into conventional zones for convenience in the reference and location of the organs. These are shown in fig. 90. In the upper zone lies the epigastric region centrally, with the hypochondriac regions on either side; in the middle zone, the umbilical region centrally, flanked by the lumbar regions; and in the lower zone, the hypogastric region centrally has the iliac regions to right and left. A conventional representation of the surface projection of some of the internal organs on this pattern is given in Plate 5, but it must be remembered that there are very considerable variations in their positions with change of posture and in different individuals.

**Posterior abdominal wall.** In the midline of the back, the spinous processes of the lumbar vertebrae are felt between the thorax and the sacrum; and on each side of the spine is the belly of the great *erector spinae* muscle which is constantly helping to maintain the erect position. The short twelfth rib on each side marks the lowest limit of the bony thoracic cage above; while below, the iliac crests can be traced back towards the sacrum where they end in the posterior superior iliac spines, marked by an overlying dimple in the skin. Thus, on each side of the spine, beyond the lateral border of the *erector spinae* muscle, is an unprotected portion of the abdominal wall, the loin or lumbar region, lying between twelfth rib and iliac crest. However, the flank musculature is extremely strong and resistant. Plate 5 indicates the relation of

some of the internal organs to the surface of the back, and it should be noted that the colon and kidneys, because they are *behind* the peritoneum, are relatively fixed; unlike the mobile liver and small bowel which are slung freely in the peritoneal cavity.

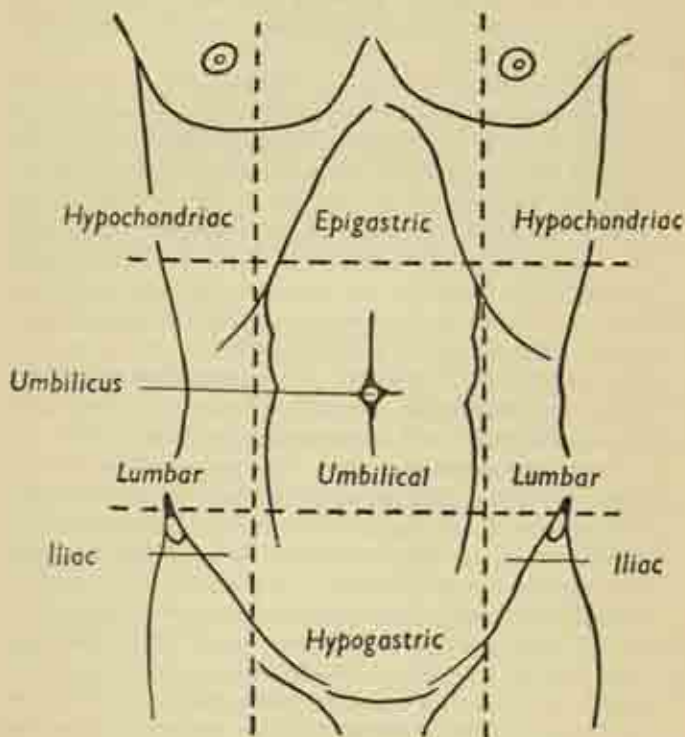


FIG. 90. The zones of the anterior abdominal wall.

**Abdominal muscles.** These are more easily drawn than described; and are best considered in the following groups ;



- (i) the muscles of the posterior abdominal wall: *psoas, quadratus lumborum*;
- (ii) the muscles of the flanks: *internal* and *external obliques, transversus abdominis*;
- (iii) the muscles of the anterior abdominal wall: *rectus abdominis, pyramidalis*.

The cross-section in fig. 91 gives a general idea of the interrelation of these groups.

*Muscles of posterior abdominal wall.* The *psoas* has already been encountered in connexion with the hip-joint (p. 128); a long belly beside the lumbar vertebræ, it finally skirts the pelvic brim to enter the thigh. The *quadratus lumborum* lies immediately lateral to it, a flat quadrilateral muscular plate extending vertically between twelfth rib and iliac crest.

*Flank muscles.* These make up a layered arrangement of muscles, in which the *internal oblique* is sandwiched between the *external oblique* superficially and the *transversus abdominis* deeply; their fibres cross each other in different directions, thus adding to their protective power. They all arise from the lower ribs above; the iliac crest below; and, via a dense sheet of lumbar fascia, from the tips of the lumbar transverse processes behind. The external oblique fibres run downwards and in, the direction of a man putting his hand in his pocket; the internal oblique fibres are exactly at right angles to this; and those of transversus run straight round in the horizontal plane.

Near their origins, above, below and behind, these muscles are very fleshy, but as they curve round the flank to reach the anterior abdominal wall they merge into great aponeurotic sheets extending between costal margin and iliac crests. These aponeuroses are intimately related to each other and to the rectus abdominis muscle, as indicated below; and intersect at the linea alba in the midline.



The *rectus abdominis* is a flat vertical muscle on each side of the midline, extending from the front of the costal cartilages of the lower ribs to the pubic crest on each side of the symphysis below. Note how the upper part of its belly is marked by 2-3 transverse tendinous intersections interrupting the fibres, obvious under the skin when the muscle is made to stand out. The *pyramidalis* is a little triangular muscle arising from the pubic crest in front of the rectus and inserted into the linea alba.

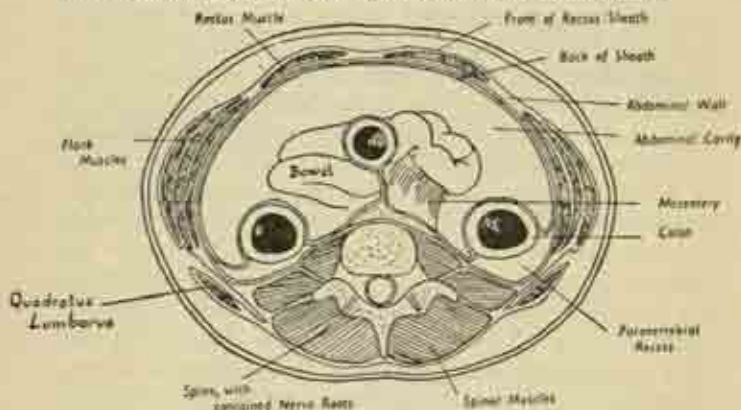


FIG. 91. Cross-section of abdomen below the level of the kidneys. Note the suspension of the small bowel by its mesentery from the posterior abdominal wall; also the relations of the muscle groups.

The *aponeuroses, the rectus sheath, nerves and vessels of the abdominal wall*. We have seen that, at a point about half-way between the flank and the linea alba, the flank muscles are continued anteriorly as aponeurotic sheets. As these sheets approach the lateral border of the rectus muscle, the external oblique aponeurosis passes in front of that muscle, and the transversus aponeurosis behind; while that of the internal oblique splits in two, one layer joining each of the others (fig. 91). This arrangement provides a continuous rectus

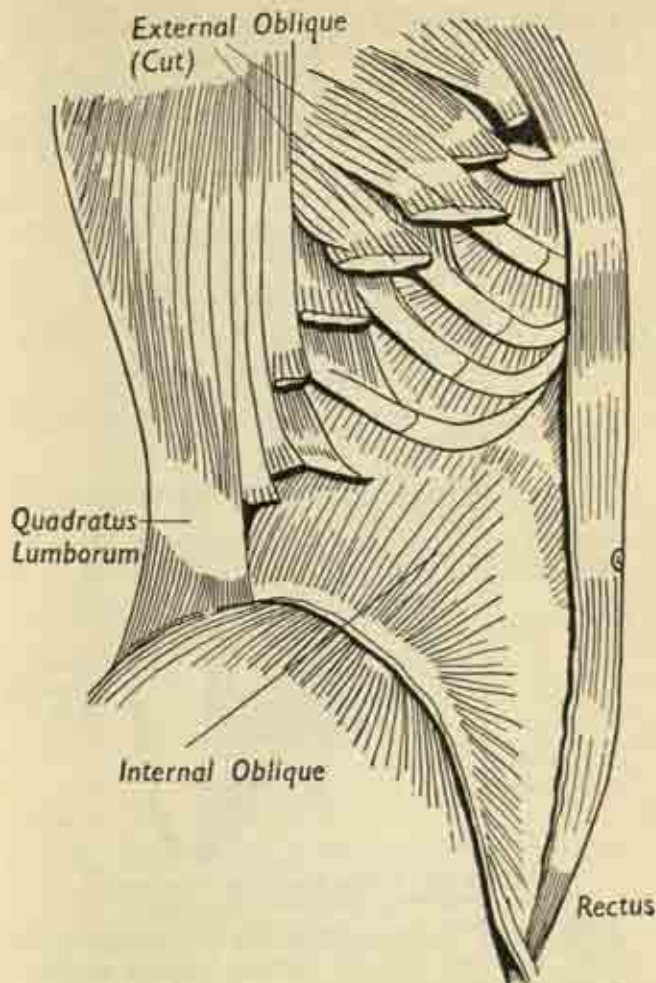


FIG. 92. The flank abdominal muscles of the right side, intermediate layer. The external oblique has been removed, and the internal oblique is seen extending between the quadratus lumborum behind and the rectus abdominis in front.

sheath, whose anterior and posterior walls rejoin on the inner side of the rectus to form the linea alba.

The nerves and vessels of the anterior abdominal wall are the lower 6 of the 12 pairs of thoracic vessels and nerves; this is because, as the lower ribs overhang the

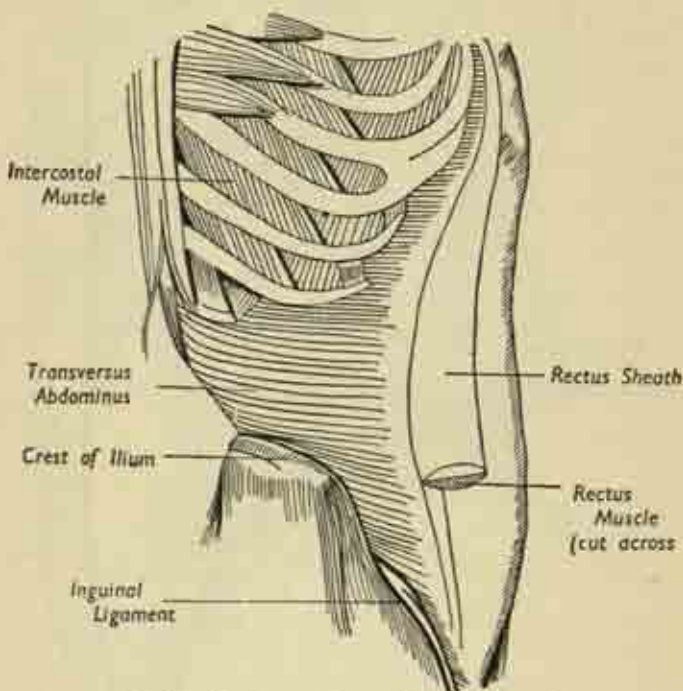


FIG. 93. The deepest layer of the flank muscles, transversus abdominis. (After Gray).

abdominal cavity and as these ribs are incomplete anteriorly, the neuro-vascular bundles running in the rib spaces emerge between the flank muscles of the abdominal wall. Here they run in the plane between the transversus and internal oblique until the lateral border of the

rectus is reached, when they enter the sheath behind the muscle and finally turn forward at its inner border, piercing the linea alba to reach the skin. In their circular course, superficial branches have been given off in the flanks and twigs to the muscle layers.

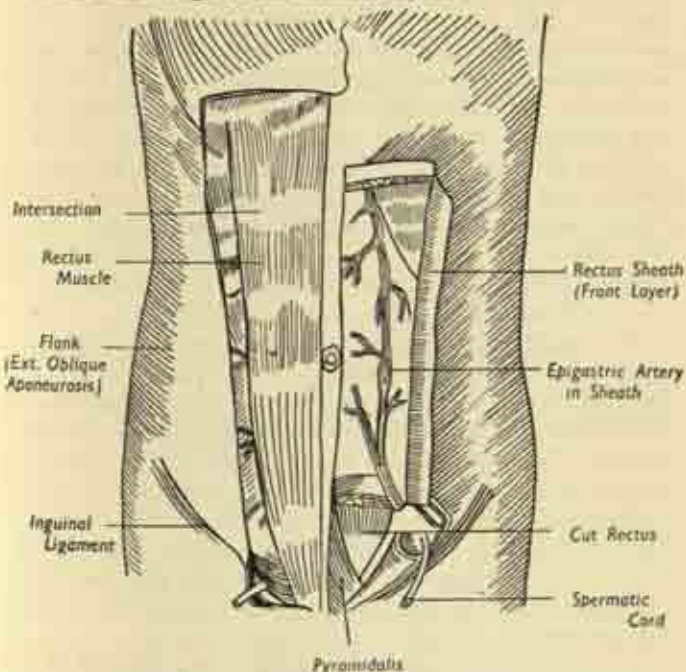


FIG. 94. The rectus muscles and their sheaths. The left rectus has been removed to display the posterior wall of its sheath and the arterial network. (After Gray).

Finally, within the rectus sheath, a vertical arrangement of arteries and veins is formed behind the rectus muscle by anastomosis between the superior epigastric vessels coming down from the thorax and the inferior epigastrics running up from the external iliac trunks below.

**Peritoneum, mesenteries, omenta.**

The abdominal cavity is a closed sac, lined continuously with the peritoneal serous membrane; that part of the membrane clothing the deep aspect of the abdominal wall is the *parietal* peritoneum, which is reflected over the contained viscera as the *visceral* peritoneum. The parietal layer is attached to the deep surface of the anterior and posterior abdominal walls, to the under-surface of the diaphragm, and to the upper surface of the pelvic floor. Its smooth surface, lubricated by a small amount of serous fluid, allows the structures to glide freely; and a loose layer of extraperitoneal connective tissue intervenes between the parietal peritoneum and the abdominal wall, a layer in which any infection derived, for instance, from a perforating wound of the bowel spreads with great ease and virulence.

The main peritoneal cavity of abdomen and pelvis is known as the *greater sac*, in contra-distinction to a smaller recess, the *lesser sac*, which lies immediately behind the stomach and is almost cut off from the general cavity. These spaces, and the relations of the various organs to the peritoneum, are rather complex and best understood by studying figs. 88 and 89, bearing in mind that most of the organs lying freely in the abdominal cavity have developed in the embryo from the posterior wall, to which they still retain an attachment. The main points are these (fig. 96):

(i) Certain organs are entirely retroperitoneal and therefore fixed, e.g., the kidneys and pancreas; they lie on the posterior abdominal wall, with a peritoneal covering, if any, on their anterior surfaces only.

(ii) Other organs, the ascending and descending portions of the colon and the rectum, all parts of the large bowel, have a peritoneal covering in front and at the sides; they are still retroperitoneal, but with rather more mobility.



(iii) The small intestine, and the transverse and pelvic portions of the colon, hang freely in the cavity; to do so, they have pulled out a double-layered sheet

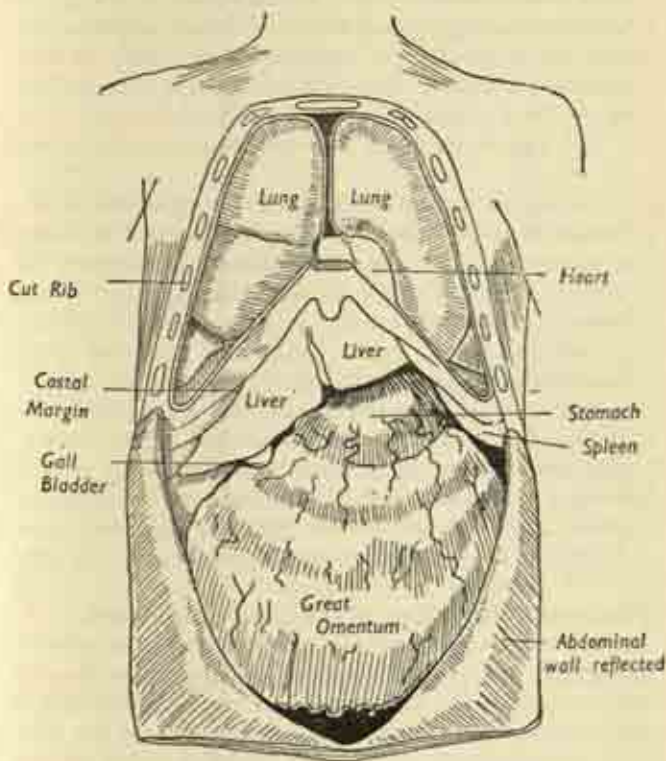


FIG. 95. The viscera exposed by removal of the anterior walls of abdomen and thorax.

of peritoneum from the posterior abdominal wall which is known as a *mesentery*. This is laden with fat, contains lymph glands and vessels, and the blood-



vessels reach the bowel by running between its layers from the great vessels on the posterior abdominal wall. Small bowel, transverse and sigmoid colon, each have their own mesentery; but the main one is the great sheet supporting the small bowel, known simply as the mesentery, the line of attachment of which behind crosses the lumbar spine obliquely from left to right from above downwards (fig. 91).

(iv) The stomach has two special mesenteries known as *omenta*.

The *great omentum* hangs down from the lower border of the stomach as an apron-like fold in front of the small bowel, and then turns up to embrace the transverse colon before its final reflexion on to the posterior abdominal wall, i.e., the mesentery of the transverse colon is really continuous with the great omentum of the stomach (figs. 88, 95).

The *lesser omentum* connects the upper border of the stomach to the liver, and its layers split to enclose that organ before their final reflexion on the under-surface of the diaphragm as the suspensory ligaments of the liver. It can be seen that the lesser omentum forms the anterior boundary of the lesser sac (fig. 88).

### The general disposition of the abdominal organs.

Fig. 95 shows the structures revealed when the anterior abdominal wall is removed. The *liver* occupies the upper right portion of the cavity, emerging a little below the costal margin and occupying a little of the left side, with its superficial intermediate portion lying in the epigastric region immediately below the xiphisternum. Beneath its lower border, on the right side, projects the *gall-bladder*. The *stomach* is largely under cover of the left ribs but a part of its anterior surface is seen in the angle between the lower border of the liver and the left costal margin. The *great omentum* descends from the

lower border of the stomach like an apron, covering and obscuring the *transverse colon*, which lies immediately below the stomach, and the numerous coils of *small bowel*. These last are the main contents of the cavity, insinuating themselves into its recesses and dropping down into the pelvis. The *spleen* is barely seen, as it is tucked up entirely under cover of the left costal margin. The more superficial viscera will now be considered in turn.

### Stomach.

The stomach is the widest part of the digestive tract, connecting the oesophagus (gullet) with the duodenum, the beginning of the small intestine. The oesophagus joins the stomach very shortly after entering the abdomen through the diaphragm; and the duodenum leaves the organ at the pyloric orifice. The stomach lies mainly in the epigastric and left hypochondriac regions, but there is considerable variation with posture, digestive state and emotion; and part may lie in the umbilical region or even descend to the pelvic brim. It is a rather J-shaped structure, with anterior and posterior surfaces parallel to the abdominal wall, and upper and lower borders known as the lesser and greater curvatures respectively. It can be seen in fig. 97(a) how the lesser curve forms a continuous sweep between the oesophageal entry at the cardia at its left extremity, and the departure of the duodenum at the pylorus at the right-hand end. The main sub-divisions are :

- (i) the dome-shaped *fundus*, the receptive portion, often distended with air;
  - (ii) the main *body*, concerned with digestion, and marked off by a definite notch from
  - (iii) the *pyloric* or expulsive portion, narrowing down as the pyloric antrum to the pyloric canal itself.
- Both cardiac and pyloric orifices are surrounded by what are known as *sphincters*, muscular rings which are

normally in contraction, keeping the openings closed until temporary relaxation is required for the entry or exit of food. This sphincteric control of the exits of hollow muscular organs is a common mechanism in the body, e.g., at the neck of the bladder and the opening of the anus.

In structure, the stomach is made up of several layers (fig. 97(b)). There is the smooth outer *serous* or peritoneal coat; the thick intermediate *muscular* wall which contains circular, longitudinal and oblique fibres; and the internal lining *mucous membrane*, a velvety layer of intricate folds whose glands secrete the gastric juice.

The *anterior surface* of the stomach is under cover of the left lobe of the liver and the left costal margin; with a small intermediate portion which is applied to the back of the anterior abdominal wall. The *posterior surface* lies on a definite "stomach bed," shown in fig. 98 which is formed by several organs of the posterior abdominal wall—pancreas, left kidney and suprarenal, and spleen. And between the posterior surface and its bed is, of course, the lesser sac. The *fundus* lies immediately in contact with the under-surface of the left dome of the diaphragm.

We have already seen that the two layers of peritoneum clothing the surface of the stomach meet at its borders to form the omenta; the lesser omentum connects the lesser curvature to the liver, and the greater omentum hangs down from the greater curvature as a large apron.

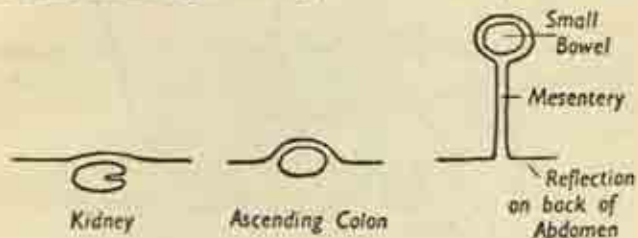
### Small intestine.

This is the portion of the digestive tract between the pyloric orifice of the stomach and the large bowel. Some 20 feet long, it is divided into :

- (i) the *duodenum*, a short coil of 10 inches immediately continuous with the stomach and bound down tightly to the posterior abdominal wall;

(ii) the *small intestine proper*, suspended in coils from the posterior wall by its mesentery.

The *duodenum* is rather C-shaped, embracing in its concavity the head of the pancreas. A short first part runs horizontally from the pylorus under cover of the liver and gall-bladder; the vertical second part descends in front of the right kidney; and the third part crosses



1. A Retroperitoneal Organ
2. Organ with Peritoneum on 3 sides
3. Freely Suspended Organ with Mesentery

FIG. 96. Different degrees of peritonisation of abdominal organs, transversely in front of the lumbar vertebræ, from which it is separated only by the great vessels—the aorta and inferior vena cava. It finally joins the small intestine at the duodeno-jejunal flexure. The pancreatic duct and the bile ducts from the liver have a common opening into its second part. (Plate 6.)

The *small intestine proper* runs from the duodeno-jejunal flexure to the ileo-colic valve which marks the junction of small intestine with the cæcum of the large bowel. Its coils are completely surrounded by a peritoneal coat except for a narrow strip, the mesenteric border, where the two layers of the mesentery diverge to enclose them. In essential structure the small bowel resembles the other parts of the intestine, possessing an outer serous coat, a muscular wall, and a lining mucosa. But characteristic are the circular folds projecting into

the lumen; the enormous number of minute fringes or *villi* of the mucosa which give it a velvety appearance

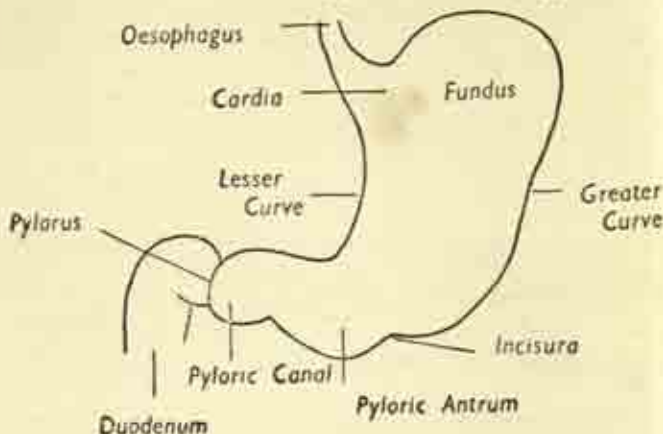
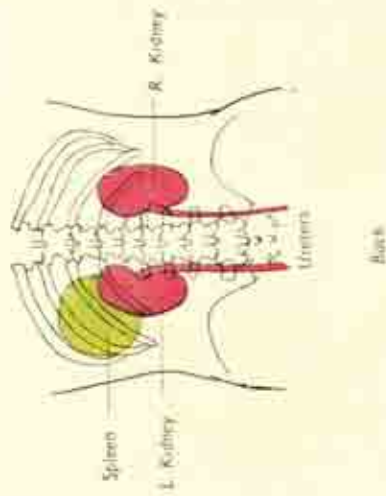


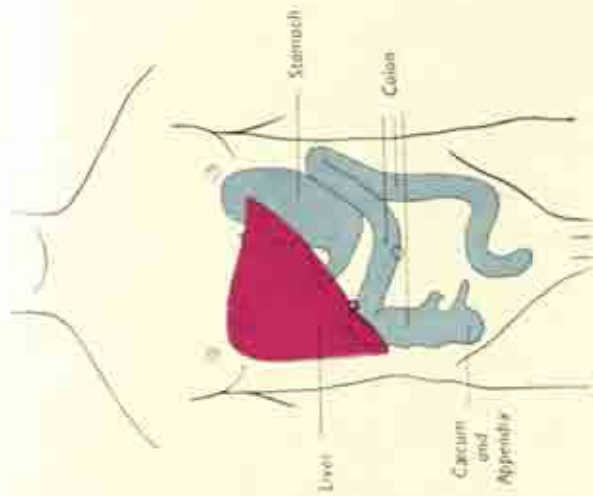
FIG. 97 (a). The stomach, anterior surface.

like the pile of a carpet, a device for increasing the absorptive area within a limited space; and the scattered patches of lymphoid tissue. Networks of blood and lymph vessels and of nerves form plexuses between the layers, all eventually forming larger trunks which run into the mesentery. The blood-vessels of the bowel enter the root of the mesentery as the superior mesenteric branches of the aorta and vena cava, and form a complicated pattern of arches or arcades between its layers, from which the ultimate twigs are given off which encircle the bowel itself.

The *jejunum* is the upper two-fifths of the small bowel, the *ileum* the lower three-fifths; there is no sharp distinction, but the ileum is thinner, narrower, less vascular, and contains more lymphoid tissue, indications that digestion and secretion are preponderant at the upper end of the bowel, absorption at the lower. The coils of the small gut as a whole are enclosed within a space



Back

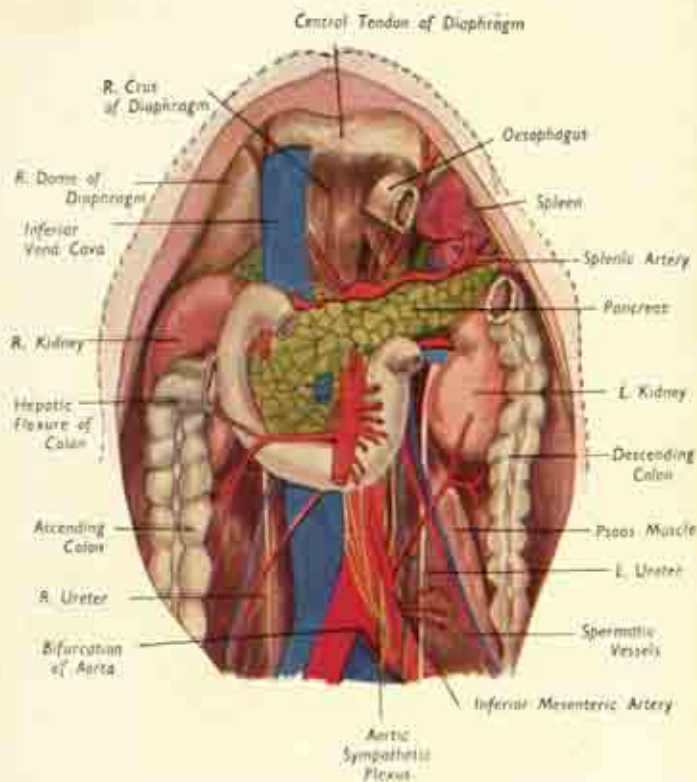


Front

Surface markings of certain abdominal organs.

PLATE. 5





Structures of the posterior abdominal wall after removal of the liver, stomach, small intestine and transverse colon. The duodenum, which is unlabelled, is the C-shaped loop of bowel in the centre. The transverse colon normally arches across it to connect the ascending and descending limbs of the large bowel, here shown cut across.

bounded by the limbs of the colon; and in general the jejunum is above and to the left while the ileum is central and inferior, some of its loops usually spilling over into the pelvis before rising again as the terminal ileum to join the large bowel.

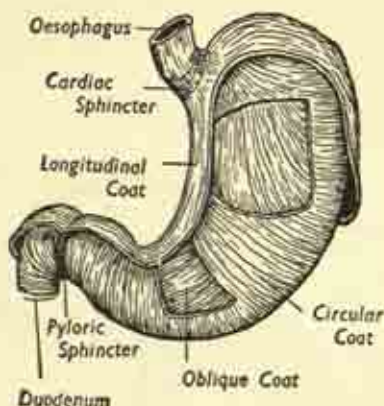


FIG. 97 (b). The muscle coats and sphincters of the stomach.

**The Mesentery.** The leaves of the mesentery enclose between them : (i) considerable fat and connective tissue, (ii) many lymph glands receiving the bowel lymphatics or lacteal vessels, so called because of the milky fat-laden fluid in them, (iii) the mesenteric vessels, and (iv) nerves supplying the intestine. It is stimulation of the latter which give rise to shock and collapse when the mesentery is injured or twisted. The posterior attachment, or "root" of the mesentery is an oblique line of some six inches running down the posterior abdominal wall from the left of the second lumbar vertebra to the region of the right sacro iliac joint below, crossing over the duodenum and great vessels. The great disparity between this short origin and its extensive attachment to the bowel causes the membrane to be thrown into fan-shaped folds.

**Large bowel.**

The large intestine runs from the end of the ileum to the external orifice of the anus in the perineal region. Only some 5-6 feet long, it includes the following portions:

- (i) the *caecum*, with its *vermiform appendix*;
- (ii) the *ascending*, *transverse* and *descending* limbs of the colon;
- (iii) the *pelvic colon*;
- (iv) the *rectum* and *anal canal*.

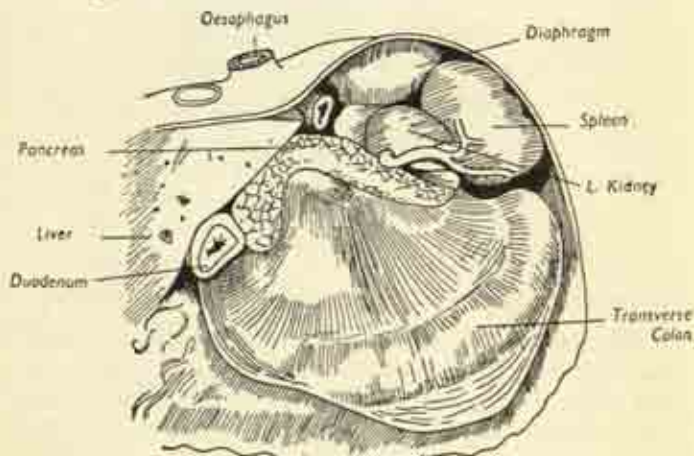


FIG. 98. The stomach bed. The left lobe of the liver has been cut away, and the stomach itself removed, to show the organs on which it lies. (After Gray).

Of these, only the transverse and pelvic segments of colon have mesenteries and are freely mobile; the remainder are retroperitoneal, while the lower rectum and anus are entirely below the level of the peritoneum in the depths of the pelvis.

The *caecum* lies in the right iliac fossa, the shallow basin formed by the internal surface of the iliac portion of the innominate bone. It is the blind sacculated

commencement of the large bowel, the terminal ileum opening into it at one side by an aperture guarded by the ileocolic valve. The appendix is attached a little lower

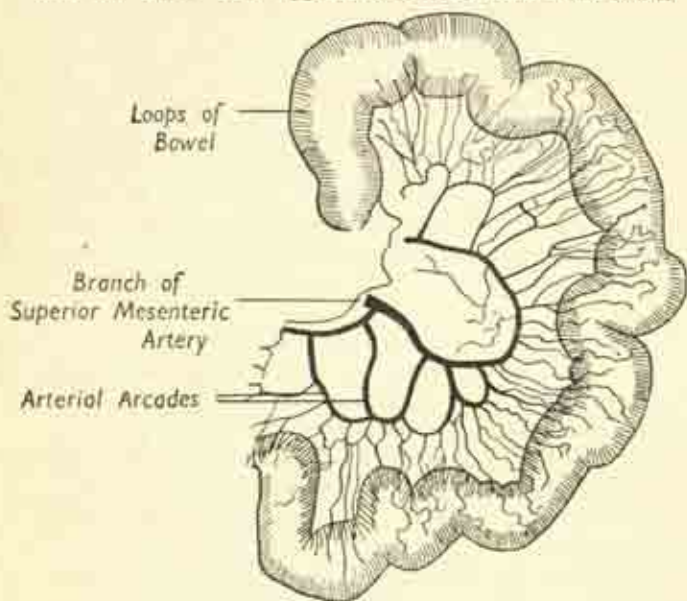



FIG. 99. A loop of small bowel, with its blood vessels, down in the angle between the two. The caecum has no mesentery but is completely invested by peritoneum, and has the considerable mobility of a flapping balloon tethered at one point.

The *appendix* is a worm-like tube of varying length, blind at its free end, and with a tiny mesentery of its own. Its position is far from constant; it may lie tucked up behind the caecum, hang down over the pelvic brim, or turn up in front or behind the terminal ileum, a range of variation responsible for the difficulties in diagnosing acute appendicitis.

**Colon.** The ascending, transverse and descending colon are arranged round the abdominal cavity like three sides of a square——but the two vertical limbs lie in the paravertebral gutter on each side and therefore behind the plane of the transverse limb, which sags down towards the pelvis in a redundant fashion. The junctions of transverse colon with the vertical limbs at either end are known as flexures, the *hepatic flexure* on the right under cover of the right lobe of the liver, and the *splenic flexure* on the left in relation to the spleen. And because of the greater bulk of the liver on the right side of the abdomen, the hepatic flexure is pushed down several inches lower than the splenic. The colon in general is distinguished by :

- (i) three superficial bands of longitudinal muscle standing out under the serous coat and traversing the bowel from end to end—the *taenia coli*, which are spaced equally round its circumference;
- (ii) the scattered fatty tags or polyps which project as the stalked *epiploic appendages* on the surface;
- (iii) a segmentation into coarse *sacculations* vaguely resembling those of an earthworm.

The internal structure is like that of the bowel in general, except that the serous coat is incomplete wherever the colon is only partly peritonized, and that the mucosa is smooth and pale.

The *ascending colon* lies on the posterior abdominal wall, mainly on the quadratus lumborum muscle; and since it is bound there by a peritoneal covering on the front and sides only, is relatively immobile.

The *hepatic flexure* lies in front of the lower pole of the right kidney and is itself overhung by the right lobe of the liver.

The *transverse colon* arches across the abdomen, lying immediately below the greater curvature of the stomach and obscured by the great omentum of the latter. It is



very mobile since it has a mesentery, the *transverse meso-colon*, derived as we have seen from the doubling back of the layers of the great omentum which diverge to enclose the bowel, and then rejoin to form its mesentery as they are reflected on the posterior abdominal wall (fig. 88).

Plate 6 shows the transverse colon to lie in front of most of the structures of the posterior abdominal wall at this level—duodenum, pancreas, great vessels, and portions of the kidneys on either side; and the prominence of the lumbar spine behind all these arches the colon forwards.

The *splenic flexure* lies in front of the left kidney, immediately below the lower pole of the spleen, with the diaphragm supporting it behind.

The *descending colon*, like the ascending, has no mesentery and is plastered on to the posterior abdominal wall behind the peritoneum. It runs down from the splenic flexure as far as the pelvic brim on the left side, where the shallow left iliac fossa gives way sharply to the deep true pelvis. And to reach this position it crosses in front of the left psoas muscle and the left common iliac artery and vein.

The *pelvic colon*, the continuation of the descending colon, extends from the pelvic brim to the beginning of the rectum, opposite the middle of the sacrum in the depths of the true pelvis. It has a long mesentery, the *pelvic meso-colon*, and this part of the bowel is consequently loose and mobile; it may hang down in the pelvis or lie turned up in the main abdominal cavity.

The *rectum and anus* will be described in connexion with the pelvis (p. 187).

### Blood-vessels and lymphatics of the large bowel

These are indicated diagrammatically in fig. 100. Each limb of the colon has a main artery of its own; the ascending and transverse colon have the right and middle



colic vessels, branches of the superior mesenteric artery which has already supplied the whole of the small bowel; while the descending limb receives the left colic division of another great branch of the aorta, the inferior hæmorrhoidal artery, which passes down to the rectum after giving twigs to the loop of the pelvic colon. Note that as the right, middle and left colic arteries approach the

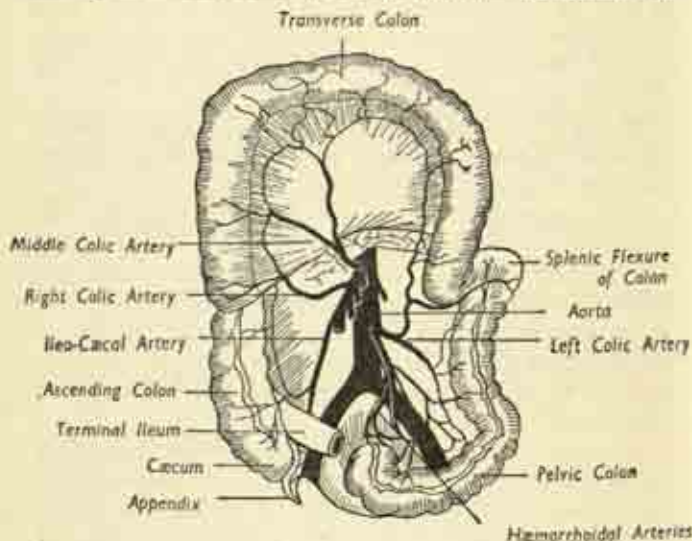


FIG. 100. The large Bowel and its blood-vessels. The transverse loop of colon, which is normally dependent, has been turned up for clarity.

bowel (the middle between the layers of the transverse meso-colon and the other two behind the peritoneum of the posterior abdominal wall) they each fork into two main branches which run parallel with the bowel to anastomose with the adjacent vessels. They thus form a continuous arterial channel from one end of the large bowel to the other, a channel whose branches form a network of arteries whose twigs ultimately reach the intestine.

The general peripheral pattern of the corresponding *veins* is similar; but whereas the arteries have sprung from the great artery of the posterior abdominal wall, the aorta, the veins do not return to the companion inferior vena cava but enter an entirely separate venous trunk behind the pancreas, the *portal vein*, which gathers up the splenic vein on its way to run up in the lesser omentum and enter the liver. This so-called "portal circulation" ensures that the venous blood draining from the bowel, and containing the products of digestion, passes through the liver before entering the general circulation. This organ is thus enabled to store certain of these products, such as glycogen, and to effect certain biochemical changes in others, such as the splitting-up of proteins and the formation of urea.

### Liver.

This is an appropriate place to consider the liver, a bulky solid organ, the largest gland in the body, occupying the upper right portion of the abdominal cavity. It has a brownish friable substance, with a smooth peritoneal coat, and is slung from the under-surface of the diaphragm by suspensory ligaments which are the peritoneal reflexions on to the under-surface of that partition. The large *right lobe* and the much smaller *left lobe* lie directly beneath the right and left domes of the diaphragm, and most of the organ is under cover of the ribs. It reaches almost to nipple level on each side, and only projects a little beyond the costal margin in the epigastric and right hypochondriac regions, where it lies in contact with the back of the anterior abdominal wall.

Note that, because of the upward bulge it produces in the floor of the thoracic cavity, the lower borders of the lung and pleural cavity actually surround the upper part of the liver in a sort of rim, so that a penetrating wound in the lower part of the chest may traverse the lung and

pleura and then enter the liver. The organ is  $\pi$ -shaped in sagittal section, the sloping limb facing backwards; with superior, anterior and posterior surfaces, and bluntly rounded borders of which the inferior is the sharpest.

The *anterior surface* is opposed to the backs of the

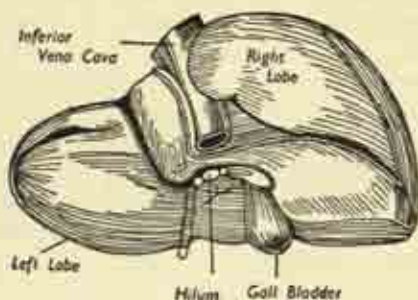


FIG. 101. The liver seen from behind. (After Gray).

lower ribs and to the back of the anterior abdominal wall in the epigastric region. On it, the demarcation of right and left lobes is made by the *falciform ligament*, which attaches the liver to the back of the anterior abdominal wall in the midline between xiphisternum and umbilicus. The *superior surface* rests in contact with the diaphragm. The *posterior surface* is more complex. On the right, it overlies the right kidney and the hepatic flexure of the colon; on the left, it covers the front of the stomach, the upper pole of the left kidney with its suprarenal gland, and the spleen.

The *gall-bladder* is attached to the back of the right lobe and can just be seen from in front projecting below the inferior border. The *inferior vena cava* is embedded in the substance of the upper part of the back of this lobe, on its way up to pierce the diaphragm and enter the thorax.

At the very centre of the posterior surface of the liver,

between the lobes, is the root of the organ, the *hilum*, where the main vessels and ducts enter and leave the organ. These structures are :

- (i) the *hepatic artery* from the aorta, dividing into right and left branches to the two lobes;
- (ii) the *portal vein*, carrying nutriment from the bowel, again dividing in two branches;

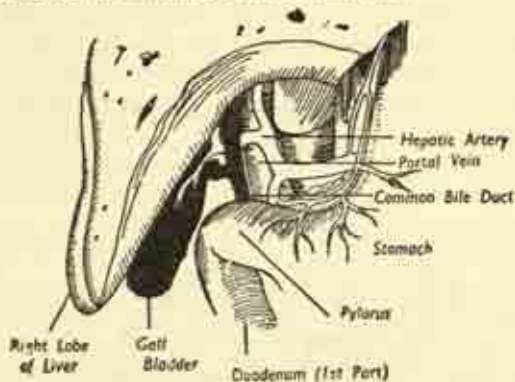


FIG. 102. The liver from in front, with part of the right lobe cut away to show the structures entering and leaving the hilum. (After Gray).

(iii) the right and left *hepatic ducts* conveying the bile secreted by each liver lobe, joining to form the *common hepatic duct*. The *cystic duct* from the gall bladder joins the common duct a little below its formation, and the main channel thus formed to pass the bile down to the duodenum is the *common bile duct*.

These structures—bile duct, hepatic artery and portal vein—have to run from the liver to the posterior abdominal wall, and they do so between the layers of the lesser omentum, which is attached to the hilum of the liver at one end and to the lesser curve of the stomach at the other.

The *functions* of the liver include the preparation of carbohydrates and proteins for utilisation by the body after their absorption from the bowel; the storage of excess carbohydrate as glycogen; and the secretion of the bile. The latter is stored and concentrated in the gall bladder, a purely mechanical reservoir with no secretory function of its own. It has a muscular coat which contracts in reflex response to the entry of food into the duodenum from the stomach; the bile is then emptied through the common duct into the duodenum, where it emulsifies the fat of the food into tiny globules for easier digestion.

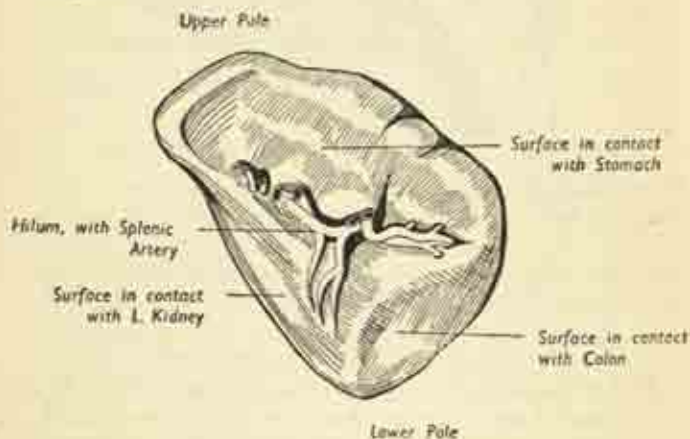


FIG. 103. The spleen.

### Spleen.

This organ occupies a position immediately below the left dome of the diaphragm corresponding to that of the right lobe of the liver on the opposite side; but it is a much smaller organ, entirely under cover of the ribs, of a soft pulpy consistency with a fibrous capsule. It is pyramidal or tetrahedral in shape, with a large smooth



convex surface applied to the underside of the diaphragm, and three smaller surfaces facing inwards and converging on the *hilum*, where the splenic artery and vein are attached. One surface forms part of the stomach bed (fig. 98); the others are in contact with the left kidney and the splenic flexure of the colon; and the tail of the pancreas reaches to the hilum.

The spleen is a reservoir of red blood corpuscles; since there are muscle fibres in its capsule and substance, it is able to squeeze more cells out into the circulation if effort or oxygen-lack make it necessary, and then the organ shrinks considerably. It is also a site for the formation of the lymphocytes of the blood, and is concerned with the elaboration of immune bodies in response to infection.

### Posterior abdominal wall and related structures

Looking into the main abdominal cavity from the front after removal of the great mass of small bowel, we see the *posterior abdominal wall*, a bony and muscular boundary partly obscured by certain organs and structures lying immediately in front of it. These are the pancreas and duodenum, stretching transversely across from side to side; the kidneys and ureters, one in each paravertebral recess; and the great vessels running vertically downwards in the midline. (Plate 6.)

The *posterior wall* itself is composed in the midline of the bodies of the lumbar vertebrae which project forward so much as to render the abdominal cavity kidney-shaped in cross-section, leaving a deep *paravertebral recess* on each side in which lie the kidneys and the ascending or descending limbs of the colon. On each side of the bodies is the psoas muscle, and more laterally the flat quadratus lumborum muscle, extending vertically between twelfth rib above and iliac crest below. The plexus of lumbar nerve roots, which emerge between the vertebrae to form a network whose ultimate branches supply the



leg, lies embedded in the psoas muscle. The upper limit of the posterior wall is the lowest attachment of the diaphragm behind; the lower limit is the pelvic brim; and laterally it is continuous with the abdominal muscles of the flank.

### **Great vessels: aorta and inferior vena cava**

The *abdominal aorta* is the continuation through the aortic aperture of the diaphragm, at the level of the twelfth thoracic vertebra, of the thoracic portion of this great artery which has arisen from the left ventricle of the heart. It runs down the midline, immediately in front of the lumbar bodies, as far as the fourth lumbar vertebra, where it divides into the right and left common iliac arteries; a bifurcation marked on the surface by a point just below and to the left of the umbilicus. It lies therefore very deeply, and is crossed transversely by the body of the pancreas and the third part of the duodenum. There is a mass of sympathetic nervous tissue on each side of its commencement, the *coeliac ganglia* or *solar plexus*, just below the diaphragm; and branches of this form a network around the length of the vessel as the *aortic plexus*. The main sympathetic chain lies on the vertebral bodies to either side of the aorta.

The *inferior vena cava* is a great vein lying immediately to the right of the aorta, draining the venous blood from the lower abdomen and legs. It is formed by the union of the two common iliac veins in front of the body of the fifth lumbar vertebra, the junction lying behind the right common iliac artery. And it runs up the posterior abdominal wall to pierce the central tendon of the diaphragm and enter the right atrium of the heart.

The branches of the aorta include :

(i) single unpaired branches from the front of the vessel in the midline : the *coeliac axis* to liver, spleen and stomach; the *superior mesenteric* to small bowel,

ascending and transverse colon; and the *inferior mesenteric* to the remainder of the large bowel;


(ii) symmetrical paired branches on each side to the diaphragm, suprarenals, kidneys, testicles or ovaries. Of these the largest are the *renal arteries*, and the right renal has to pass behind the vena cava to reach its kidney. Since the ovaries lie in the pelvis, and the testicles even lower, their vessels have to run longitudinally downward on the posterior abdominal wall to reach them, in company with the ureters. The paired branches of the vena cava correspond to those of the aorta, with certain adjustments for the slight difference in position, e.g., the left renal vein is much longer than the right and has to cross in front of the aorta. But there is a considerable difference in the fate of the venous blood from the bowel, for this has to pass through the liver before entering the general circulation so that the products of digestion may be dealt with. This is achieved by means of a small secondary *portal circulation*. The superior and inferior mesenteric veins join behind the pancreas to form a main *portal vein* which also drains the stomach and spleen. This portal trunk then ascends between the layers of the lesser omentum to the liver, there giving a branch to each lobe; in the omentum it forms a common bundle with the bile duct and hepatic artery.

After the portal blood has passed through the liver substance, it re-enters the general venous stream by a number of little *hepatic veins* opening directly into the vena cava as it lies in contact with the back of the liver, just before its passage through the diaphragm.

The main *lymphatic* drainage from the abdomen, including the lacteal vessels carrying digested fat from the bowel, is into a small vessel, the *cisterna chyli*, lying between the upper parts of aorta and vena cava; it enters the thorax with the aorta to become the thoracic duct,

which is destined to travel right up to the root of the neck on the left side before discharging its contents into the venous circulation.

### **Pancreas.**

This, the sweetbread, is a soft, solid, lobulated organ of -shape, embraced in the concavity of the duodenum and stretching transversely across the posterior abdominal wall and great vessels. It is composed of a *head*, the large rounded right-hand extremity, closely packed into the duodenal curve; a *neck* connecting the head to the *body*, which stretches right across the midline to the left side, in front of the great vessels and the upper part of the left kidney; and a final *tail*, turning up to reach the hilum of the spleen.

The pancreas is an important organ, both of external and internal secretion. The *external secretion*, the pancreatic juice, aids in digestion of carbohydrates, fats and proteins; it is discharged through the main pancreatic duct into the second part of the duodenum. This duct forms a common channel with the lower part of the common bile duct, so that bile and pancreatic juice are discharged simultaneously when required, the opening being kept closed by a sphincter between meals.

The *internal secretion*, from certain island-groups of cells, is *insulin*, which passes directly into the blood stream and is essential for the proper utilization of sugar in the body; deficiency of this secretion is the cause of diabetes.

Plate 6 shows how the superior mesenteric vessels emerge from behind the body of the pancreas and then pass in front of its head to enter the mesentery of the small bowel. The *splenic artery* runs in wavy fashion along the upper border of the organ from the coeliac branch of the aorta to the spleen. And the lower parts of portal vein, hepatic artery and common bile duct are

all situated in or behind the substance of the head and neck.

### Kidneys and Ureters.

The kidneys are responsible for the removal of waste products and excess water from the blood brought to them by the great renal vessels; and the urine they excrete is passed into ducts, the *ureters*, which carry it to the bladder. The kidneys lie one in each paravertebral recess, closely applied to the posterior abdominal wall. They are rounded, bean-shaped organs, convex at their outer borders and concave where they face the midline; with a main body and upper and lower poles. Perched on the upper pole like a little helmet is the *suprarenal gland*, an organ of internal secretion.

The kidneys are rather flattened organs, lying obliquely with the upper pole rather nearer the midline; and the general level of the right kidney is an inch or more lower than the left, owing to the great bulk of the overhanging right lobe of the liver, which, as we have seen, produces a similar difference between the two flexures of the colon. Thus, while the left kidney rests on the eleventh and twelfth ribs behind, the right is in contact only with the twelfth. At the middle of the concave medial border is a puckered depression, the root of the organ or *hilum*, where the artery and vein are attached and the ureter makes its exit.

Longitudinal section (fig.105) shows the organ to have an outer solid substance enclosing an inner cavity, the *renal pelvis*, which collects the urine as it is formed. The renal substance has an outer rind or *cortex* and a deeper *medulla*; and the latter is arranged in pyramidal masses whose apices project into little bays of the pelvis called the *calyces*. The microscopic renal tubules, in which the urine is formed, discharge their content at the tips or papillæ of the pyramids into the renal pelvis. The pelvis



itself is partly enclosed within the kidney—the intra-renal portion; and partly emerges at the hilum as the extra-renal portion to become continuous with the ureter at the pelvi-ureteric junction.

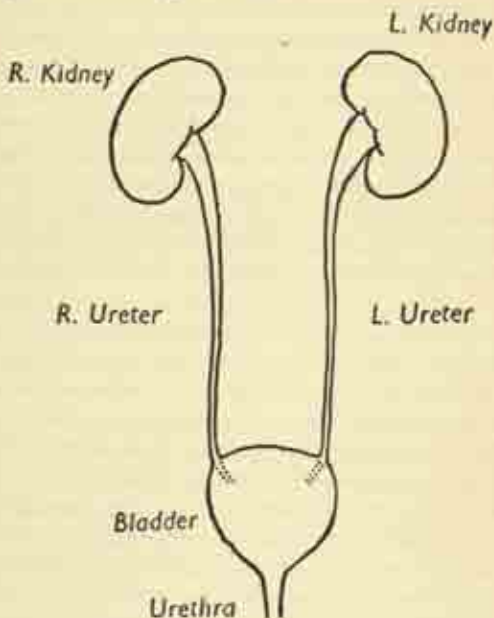


Fig. 104. The Urinary System.

The kidney has a tough true capsule which forms the glistening outer surface; and lies embedded in a much looser and more voluminous false capsule of perinephric fat and fascia in which it glides up and down with respiration. It is liberally supplied with nerves and consequently is very sensitive to over-distension if the free exit of urine is obstructed.

Since the kidneys lie on the lower ribs, they are in relation to the lowest part of the pleural cavity of the

chest, which overhangs the back of the upper pole, separated only by the lowest fibres of the diaphragm; but most of the organ lies on the psoas and quadratus muscles behind. The other relations have already been touched on, and differ somewhat on the two sides.

*Right.* The right lobe of the liver is in front of most of the anterior surface; the second part of the duodenum lies before the hilum; the hepatic flexure of the colon is in front of the lower pole.

*Left.* The body of the pancreas crosses the middle of the anterior surface; the latter also forms part of the stomach bed. The spleen is applied to the convex outer border, and the splenic flexure of the colon is in contact with the lower pole.

The *ureters*, the ducts of the kidneys, begin at the pelvi-ureteric junction in the hilum of the kidney; emerge from behind the renal vessels; and run obliquely downward and inward on the psoas muscle behind the parietal peritoneum. Reaching the pelvic brim, they cross in front of the common iliac vessels, run down the side wall of the true pelvis, and finally enter the bladder. They are hollow muscular tubes, some 10 inches long and one-sixth of an inch in diameter, down which urine is propelled in gushes by regular waves of contraction, or peristalsis.

### The diaphragm.

The chief muscle of respiration, and the most important muscle of the body after the heart. We have seen that it forms a partition, part muscular, part tendinous, between the thoracic and abdominal cavities. It has a right and left muscular *dome* rising high into the thorax and separating the base of each lung from the abdominal viscera; and there is an intermediate flatter *central tendon*, on which rests the heart in the pericardium.

The muscular portion must obviously have a number



of bony origins at different points around the periphery of its lower attachments. Thus, in *front*, it arises from the back of the xiphisternum; at the *sides*, from the deep aspect of the lower ribs; and in the midline *posteriorly* it enters into the formation of the upper part of the

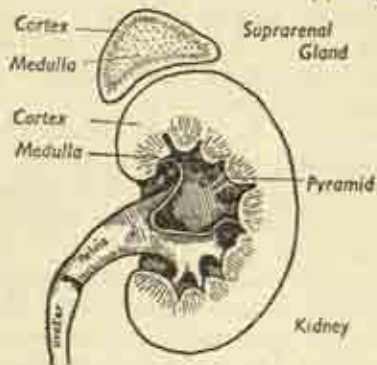


FIG. 105. Kidney and suprarenal gland, longitudinal section.

posterior abdominal wall by arising in two muscular pillars from the sides of the upper three lumbar vertebrae, forming the *crura* of the diaphragm (fig. 106).

There are several apertures for the structures passing between thorax and abdomen. The *aortic aperture* is where that vessel is embraced by the two crura as they cross in front of the body of the twelfth thoracic vertebra. The *oesophageal aperture* is in the muscular substance of the left dome at the level of the tenth thoracic body. And the opening for the *inferior vena cava* lies in the central tendon just to the right of the midline at the level of the ninth thoracic body. (Plate 6.)

It may be mentioned here that there are occasionally congenital deficiencies in the muscular substance of the partition, as clefts between its different heads of origin. Thus there may be a gap between sternal and costal attachments. And when this is so some of the abdominal

viscera—the stomach, liver or small bowel—may herniate through and lie in the thoracic cavity in contact with the lung. This is a diaphragmatic hernia, and it is commoner on the left side as the bulk of the right lobe of the liver usually prevents such displacement.

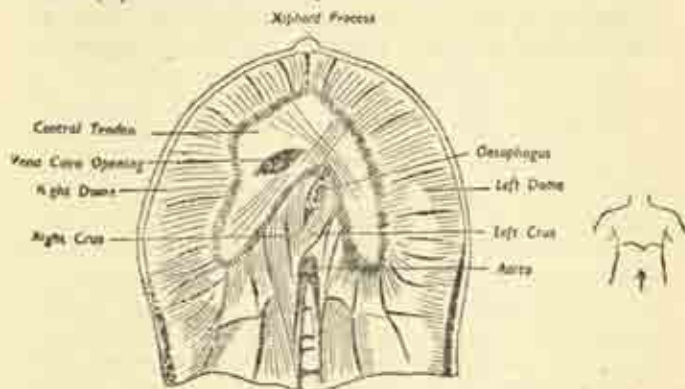


FIG. 106. The Diaphragm, seen from below. (After Gray).

## THE PELVIS

We have already seen that the lower portion of the main abdominal cavity is known as the pelvic cavity; and that the latter is set at such a backward inclination from the vertical that it forms rather a separate compartment, although the two are freely continuous at the pelvic inlet (fig. 88).

The cavity is formed by the basin-shaped arrangement of the bony pelvis, the ring formed by the two innominate bones at the sides and in front, and the sacrum and coccyx behind; a ring which is interposed between the lower spine and the legs (figs. 23, 24). The bony pelvis falls naturally in two parts (figs. 108, 112).

(i) the *false pelvis*, the shallow edges of the basin above the pelvic brim on each side, i.e., the right and left *iliac fossæ*, which are clothed by the iliacus muscles.

and support the caecum and pelvic colon respectively;

(ii) the *true pelvis*, the deeply-enclosed portion below the pelvic brim, containing the essential pelvic organs. The true pelvis is what is usually meant by the word "pelvis" in general use and our further remarks will apply to it alone, as the false pelvis merely forms on each side the floor of the abdominal cavity proper.

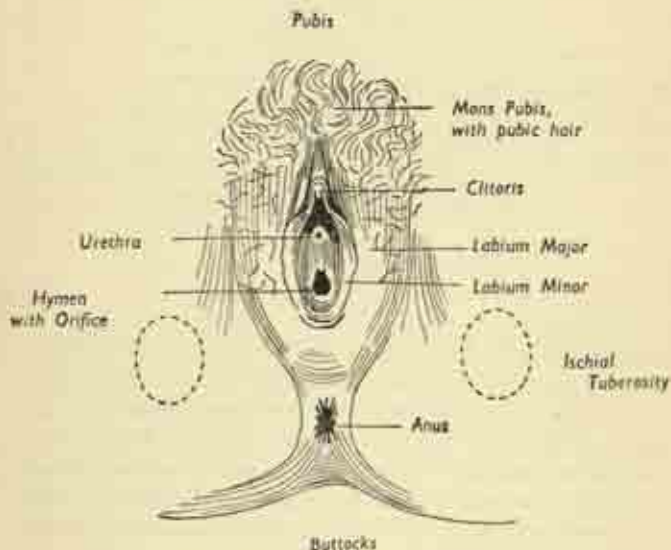


FIG. 107. The female perineum.

It has an *inlet*, an *outlet*, a *cavity*, and a *floor*; its boundaries are only partially bony and are completed by soft tissues—muscles, ligaments and membranes; and the floor is composed entirely of soft tissues.

The *inlet* faces mainly forwards, and only slightly upwards, owing to the marked backward inclination of the sacrum. Its boundary is the pelvic brim, which is seen from above to be heart-shaped, with the projecting

upper part of the sacrum, the promontory, encroaching considerably behind and the obtuse angle of the pubic arch meeting at the symphysis in front (figs. 23, 24).

The *cavity* is a conical canal, much deeper posteriorly. Its walls are: *anteriorly*, the back of the pubic symphysis and rami; *laterally*, the pelvic aspects of the innominate bones, with the obturator foramina bridged across by the obturator membranes; and *posteriorly*, the anterior surface of sacrum and coccyx. These bony walls are very incomplete and are lined by various muscles, by pelvic fascia, and to some extent by the pelvic peritoneum. The principal contents of the cavity are the pelvic colon and the rectum on the posterior wall, in the hollow of the sacrum; and the bladder in front, immediately behind the symphysis. In the woman, the uterus and vagina are interposed between rectum and bladder; in men, the bladder rests on the prostate gland and seminal vesicles.

The *outlet* is a diamond shaped space when seen from below. The four bony points of the  $\diamond$  are: anteriorly, the symphysis; at each side, the ischial tuberosity, and posteriorly, the tip of the coccyx, the lowest part of the spinal column. The two anterior limbs of the  $\diamond$  are bony, the pubic arch formed by the inferior pubic rami running up to the symphysis; the two posterior limbs are ligamentous, the sacro-tuberous ligaments spanning from sacrum and coccyx to ischial tuberosities.

### Sex difference in the bony pelvis.

These are more obvious than in any other bones, as the female pelvis has to allow the passage of the baby's head in the process of birth or parturition. As a result, it is roomier than the male and shallower. The female pelvis has its side walls more vertical, the iliac fossæ are shallower, the inlet is large and nearly circular, the sacrum is short and wide and projects but little into the

pelvic cavity, and the outlet is wide, the pubic arch forming an obtuse angle, while the coccyx is usually very mobile.

All these characters are reversed in the male pelvis, a narrow cavity with sloping walls, small heart-shaped inlet with marked sacral encroachment, a tighter outlet with the pubic arch an acute angle; and a more rigid coccyx.

The female pelvis may be *contracted* or *distorted*, either congenitally or from disease such as rickets; and then labour may be more or less obstructed and normal child-birth an impossibility.

### Surface anatomy.

The only region where the pelvis comes near the surface is at the *perineum*, the space between the legs which contains the external orifices of genital, urinary and digestive tracts. Fig. 107 shows the female perineal structures as they overly the framework of the pelvic outlet. There is a diamond-shaped area of perineal skin, divided into two triangles by a line joining the ischial tuberosities. The posterior *anal triangle* contains the opening of the anus, continuous with the rectum above. The anterior *urogenital triangle* contains the opening of the *vagina*, the lower end of the genital tract; with the *urethra* just in front, the urinary channel which has run down from the bladder through the pelvic floor; further forward still, is the *clitoris*, the diminutive female equivalent of the masculine penis.

In *men*, the anal triangle is similar, but the urogenital region is very different owing to the absence of the vagina and the presence of the *penis*. The latter has at its base a central *bulb*, attached to the midpoint of the perineum, into which the urethra passes after its passage from the bladder through the prostate and pelvic floor (figs. 108, 109); and it has two lateral supporting *crura*, attached



## False Pelvis

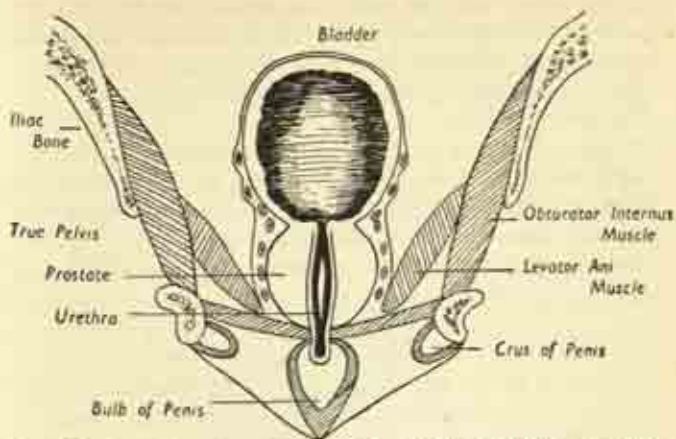


FIG. 108. Coronal section of male pelvis. Note the distinction between true and false pelvis; also the muscles of the pelvic floor. (After Gray.)

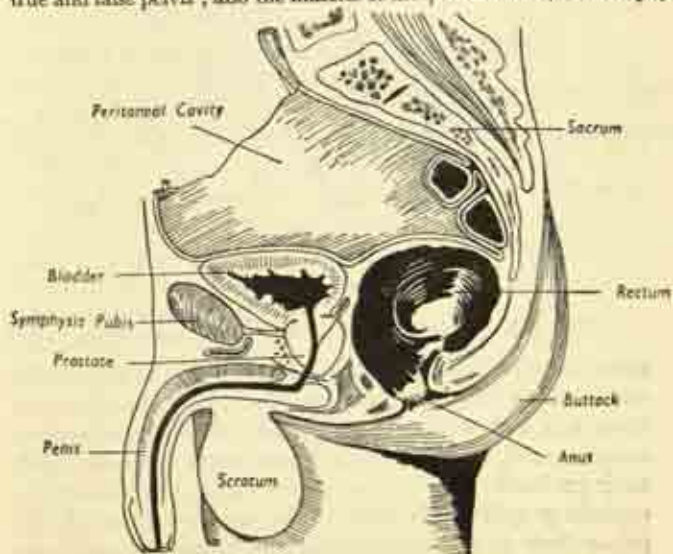


FIG. 109. Midline sagittal section of the male pelvis. (After Gray.)



to the pubic arch on each side and converging on the bulb to form the shaft of the organ, which is traversed throughout its length by the *urethral canal*, opening at the *external urinary meatus* at its tip.

**The pelvic floor.**

The pelvis may be compared to a funnel with a very wide stem; the false pelvis will be equivalent to the sloping sides of the funnel and the true pelvis to the vertical portion. The pelvic organs proper are contained within the vertical portion and rest on its floor, a

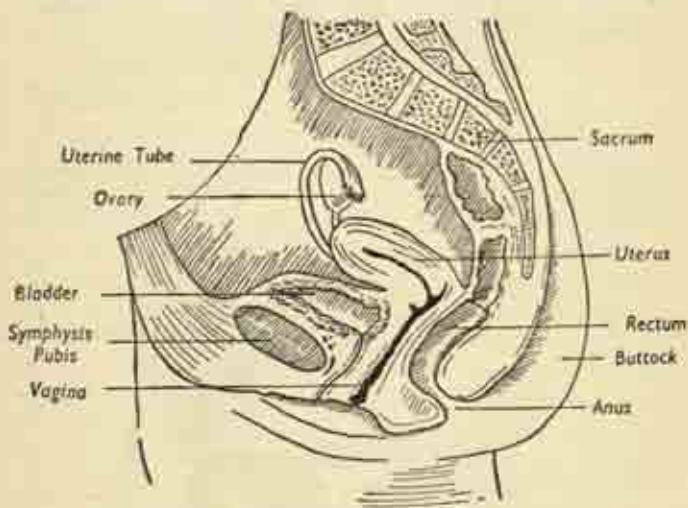


FIG. 110. Midline sagittal section of the female pelvis.

muscular partition slung from the sidewalls of the cavity and sagging obliquely downwards under their weight. Since it is a muscular partition and embraces the various canals—anal, vaginal, urethral—which pierce it to reach their perineal orifices, it surrounds each of these with an encircling sphincteric grip. The upper aspect of the pelvic floor is related more or less intimately with the

parietal layer of peritoneum, which lines the pelvis as a closed sac, and it reflected over the contained organs. The general arrangement is shown in longitudinal section (figs. 109 and 110); and is considerably simpler in the male.

In the *male*, the peritoneum is reflected from the back of the abdominal wall over the upper surface of the bladder, dips down in a recess between bladder and rectum (the recto-vesical pouch) and then turns up again over the front of the rectum. Thus, the greater part of the bladder is below peritoneal level, and the prostate entirely so.

In the *female*, the peritoneum, after covering the bladder, is thrust up by the projection of the uterus; it covers the anterior and posterior surfaces of that organ, passing off the latter to form the recto-uterine pouch—the most dependent part of the abdominal cavity—before ascending again on the rectum.

In both sexes the lower limit of peritoneum is at the level of the third piece of the sacrum; the upper part of the rectum has a peritoneal covering in front, but no mesentery, and the lower part is entirely below peritoneal level.

#### **Pelvic viscera.**

We can now describe the pelvic viscera in more detail; bladder and rectum are much the same in both sexes, but the genital organs need separate discussion, and will be dealt with later (Chapter XIII).

#### **Bladder.**

This is a hollow muscular organ occupying the anterior part of the pelvic cavity; it receives urine via the ureters from the kidneys, and expels it into the urethra by the act of micturition. Its shape is inconstant, owing to the varying degree of urinary distension, but is roughly that of an inverted pyramid resting on its apex when, contracted and empty, it lies entirely within the

pelvis. As it distends, its domed upper portion or *fundus* ascends unto the abdomen, in contact with the back of the posterior abdominal wall, and may reach as far as the umbilicus in cases of chronic obstruction to the urinary outflow.

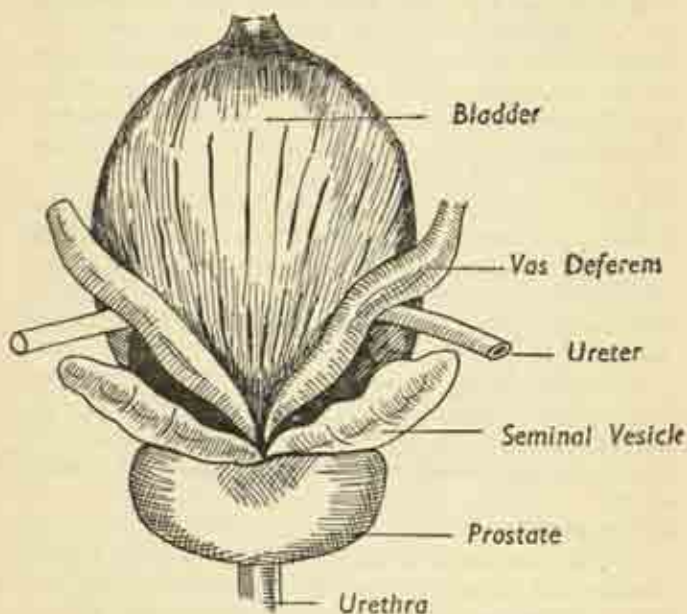


FIG. 111.

Bladder and associated organs in the male. Posterior aspect.

The upper surface is covered by peritoneum, and the ureters open into the organ at its upper lateral angles by valve-like oblique passages through the muscular wall, at the right and left *ureteric orifices*. The tapering dependent portion, the bladder neck, is continuous with the urethra at the *internal urinary meatus*. The two ureteric orifices and the internal meatus form the three points of the

*trigone*, an important region of the bladder base, very sensitive to stimulation.

In *women*, the organ is overhung from behind by the body of the uterus; and the urethra is a short canal of only one and a half inches which pierces the pelvic floor to open immediately in front of the vagina. In *men*, the neck of the bladder rests on the *prostate gland*, into which the male urethra passes; the *seminal vesicles* for the storage of sperm, and the ducts conveying sperm from the testicles, are also in close relation to the lower part of the male bladder.

The bladder wall is only partly peritoneal; there is a thick muscular coat and a mucosal lining which is ridged and wrinkled when the organ is contracted, owing to the slack required to permit distension. The involuntary nervous system adjusts muscle tone to fluid content so that it relaxes as it fills, keeping the tension constant until a threshold level is reached, when the tension rises and is felt as a conscious urge to micturate.

### **Rectum and anus.**

The rectum is the lower part of the large bowel; faeces enter it from the pelvic colon and remain there until discharged by defaecation. It is some five inches long, begins as the continuation of the pelvic colon at the middle of the sacrum, and conforms to the hollow of the sacral curve in its course, finally turning forward at the level of the coccyx to join the *anal canal*, a short wide passage one and a half inches long which bends sharply backward to open externally at the anal orifice.

The rectum has a wavy course from side to side, and its lower portion or *ampulla* is capable of considerable distension; two or three valve-like folds of mucosa project into its lumen. Only the upper portion has a peritoneal coat, and that only on the front and back sides of the bowel; the main part of its wall is longitudinal and

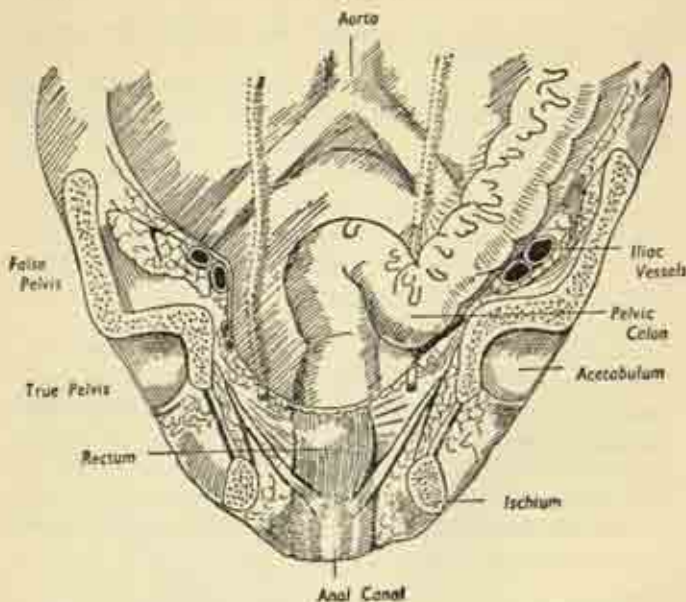


FIG. 112. Coronal section of pelvis to show the rectum and anus. Note the distinction between true and false pelvis, also the lower limit of the peritoneal cul-de-sac. (After Gray).

circular muscle, and the lowest part of the latter is thickened as a powerful ring gripping the ano-rectal junction, the *internal sphincter*.

The anal canal is also widely distensible for the passage of faeces; its upper part is lined with mucosa, but the lower half inch by inturned skin continuous with that of the perineum. And immediately under the peri-anal skin, encircling the orifice, is another circular muscle, the *external sphincter*. Both sphincters are normally closed; in the act of defaecation they relax, the abdominal wall tightens and voluntarily raises the abdominal pressure, and the rectum is lifted up over its contained faeces by the muscular floor of the pelvis.



**Other pelvic structures.**

The *ureters* cross the pelvic brim by passing over the common iliac vessels; travel down the sidewalls of the true pelvis under the peritoneum, a couple of inches away from the rectum; and then sweep inward and forward in a wide curve to reach the angle of the bladder.

**Vessels.**

The *common iliac* vessels pass downwards and out from their formation, and divide at the level of the lumbo-sacral joint into external and internal iliac branches. The *external iliacs* continue the same course along the pelvic brim, together with the psoas tendon and the femoral nerve more laterally; and pass beneath the inguinal ligament to emerge as the femoral vessels in the front of the upper part of the thigh. The *internal iliac* vessels descend sharply down the sidewall of the true pelvis and break up into several branches supplying bladder, rectum, and genital organs.

**Nerves.**

We have already noted the *lumbar plexus* on the posterior abdominal wall, and this is continued in the pelvis as the *sacral plexus* of nerve roots emerging from the foramina of the sacrum and lying on the posterior wall of the cavity. The main branch of the lumbar plexus is the *femoral nerve* which accompanies the psoas tendon and external iliac vessels to the thigh; and the main branch of the sacral plexus is the *sciatic nerve* which leaves the back of the pelvis to emerge in the depths of the buttock behind.

The *sympathetic chain* is continued down from the abdomen to run on the front of the sacrum and coccyx, ending as a single fused ganglion on the latter bone.

Uterus, uterine tubes, ovaries, vagina, prostate, seminal vesicles, testicles and their ducts, are described in Chapter XIII in detail, in connexion with reproduction.



## CHAPTER VIII

### THORAX

THE thorax is a complete and intricate bony cage, containing the heart and lungs. Its apparent cylindrical shape is illusory, and due to the upper projection of the shoulders on each side; when these are removed (fig. 113) it is seen to be conical or barrel-shaped, with quite a narrow apex.

#### Bony wall.

In the midline behind are the 12 thoracic vertebræ of the spinal column, and in the midline anteriorly the breast-bone or sternum; between them are the encircling ribs. Note, in cross-section (fig. 116) the paravertebral recess on each side of the spine due to the backward curve of the ribs before they turn forward.

#### Ribs.

There are 12 pairs of ribs, separated by the *intercostal spaces* which contain the intercostal muscles, nerves and vessels. The first seven are *true ribs*, complete rings from spine to sternum; the eighth, ninth, and tenth are *false ribs*, not reaching the sternum but turning up to join the ribs above; and the eleventh and twelfth are *short floating ribs* ending in free blunt conical ends, embedded in the flank muscles of the abdomen. The first and twelfth ribs are very short, the intermediate ones reaching their greatest size at the seventh and eighth, so that the barrel contour of the chest slopes away in again above and below this level. Each rib also slopes somewhat downwards, its sternal end being lower than its vertebral end.

Each rib possesses a *head*, articulating with the side of the vertebral body; a short *neck*, lying on the transverse

process of the vertebræ; a *body* which runs back a little and then changes direction sharply at the *angle* to sweep forwards; and finally the *costal cartilage*, a gristly rod of one or two inches connecting bony rib to sternum. The framework is a little deficient below anteriorly, where the costal arch is formed by the right and left costal margins.

The *intercostal spaces* are filled by layers of muscle between which the intercostal vessels and nerves encircle the chest, giving branches in their course. One nerve, artery and vein occupy each space, a good example of the pattern of segmentation (p. 21).

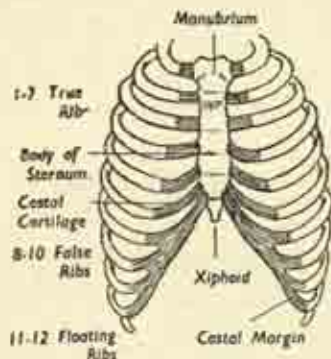


FIG. 113. The bony thoracic cage, seen from in front.

The *sternum* or breast-bone is dagger-shaped, with three main pieces. Uppermost is the broad flat *manubrium*, to which are attached the inner ends of the clavicles and first ribs on each side. Below this is the main *body*, a flat bone of two compact layers enclosing spongy bone and red marrow, with the costal cartilages attached on either side. And inferiorly is the small pointed *xiphisternum*, already encountered in the upper part of the abdominal wall.

The thorax has an *inlet* above, through which the great vessels and nerves pass up into the neck, or out

over the upper surface of the first rib into the axilla and arm. The inlet is narrow and closely packed, only two and a half inches separating the back of the manubrium from the front of the spine, with the first ribs on either side. The most important structures traversing the inlet are the *oesophagus* (gullet), *trachea* (windpipe), certain *nerves*, and the great arteries and veins. There is no inferior outlet as the thorax is sealed off below by the diaphragm.

### Respiration.

The purpose of respiration is to draw air into, and push air out of, the lungs. In inspiration, the chest cavity is enlarged and air enters; in expiration the reverse occurs. Respiratory movements are both thoracic and abdominal, though either may occur separately. In

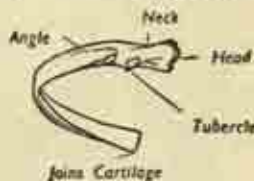
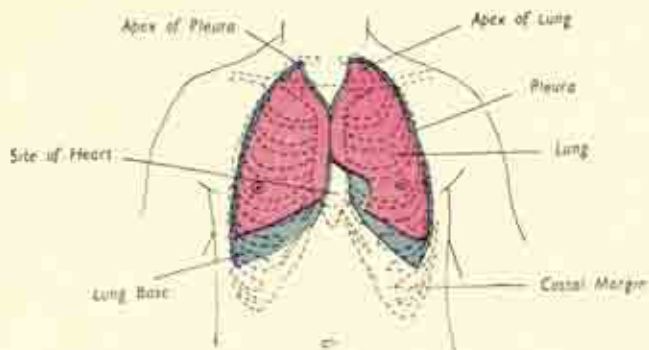
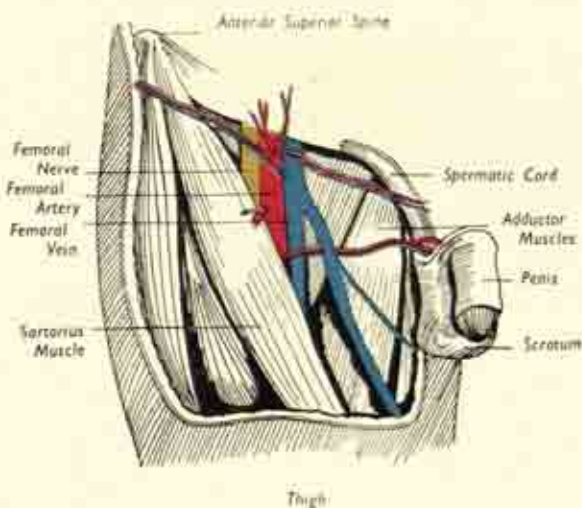


FIG. 114. A typical rib seen from behind.

*thoracic* inspiration, the sternum is lifted up by the elevation of the ribs which come to lie more horizontally; and both the transverse and antero-posterior diameters of the chest are thus increased. In *abdominal* inspiration, the diaphragm contracts and its domes flatten out, pressing the abdominal organs down and bulging out the abdominal wall; in this way the vertical height of the thorax is increased. Thus inspiration is an active process, due to muscular exertion. Expiration, on the other hand, is passive; the chest wall subsides, the abdominal wall recoils, the diaphragm relaxes, and air is driven out of the lungs.

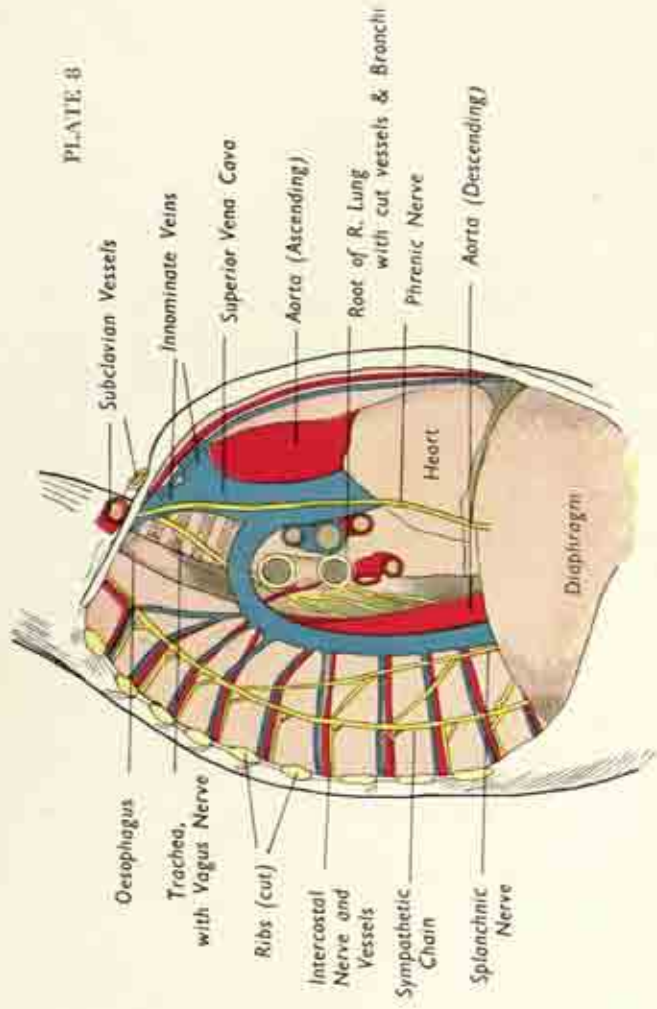


Surface markings of lungs and pleural cavities in the chest.

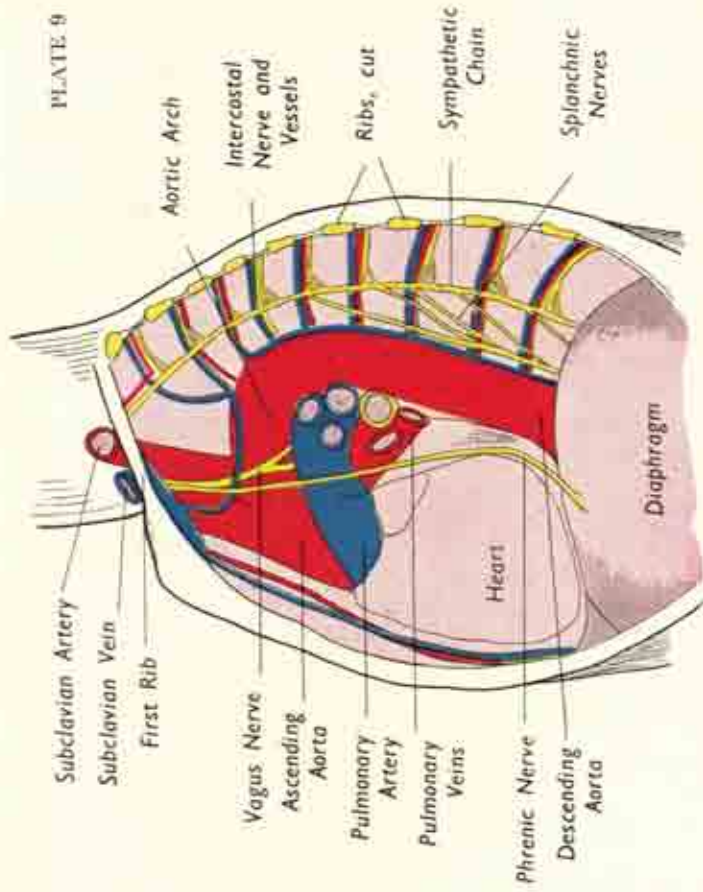


Contents of the right groin. Note the femoral nerve and vessels, the associated muscles, and the spermatic cord connecting the testicle in the scrotum with the abdomen. (After Gray.)

# PLATE 8

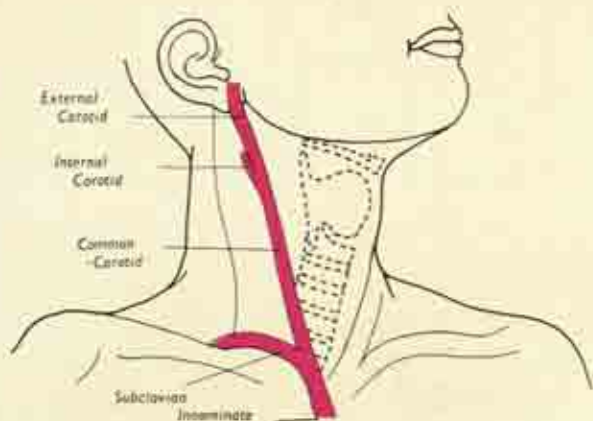


Contents of the Right side of the chest. The lung and pleura have been removed to exhibit the mediastinal structures.

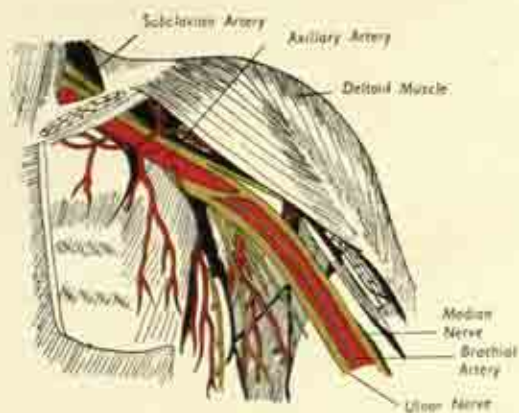


Contents of the Left side of the chest. The lung and pleura have been removed to exhibit the mediastinal structures.





Surface marking of the great arteries of the neck on the right side. (After Gray.)



Great vessels and nerves in their course from trunk to arm. Both pectoral muscles have been removed. (After Gray.)

### The muscles of the chest wall.

*Anterior.* In front, the chest wall is covered by the great mass of the *pectoralis major*, to which we have already referred in connexion with the arm. Arising from sternum, clavicle and ribs, its fibres converge laterally as they are inserted into the upper humerus; its function is adduction of the arm to the side. A smaller *pectoralis minor* lies under cover of the major, arising from three or four ribs and inserted into the coracoid process of the scapula. In the lower part of the chest wall, some of the abdominal muscles are attached to the ribs:—the *rectus* near the midline, and the *oblique* muscles more laterally.

*Posterior.* These are shown in fig. 115. Two great superficial sheets of muscle are the trapezius above and latissimus below. The *trapezius* is a triangular muscle with its base attached to the spinous processes of the thoracic vertebræ, and extending up the back of the neck as far as the occipital region of the skull. The muscle narrows rapidly as it converges to its insertion on the spine of the scapula and the back of the clavicle. As we have seen, its function is to rotate the scapula on the chest wall (fig. 35(b)), and thus aid the movement on abduction at the shoulder joint.

The *latissimus dorsi* is somewhat overlapped by the trapezius above. It originates from the lower thoracic vertebræ, and from the lumbar spine via a dense sheet of lumbar fascia. And its fibres pass away and up to be inserted into the humerus at the same level as the *pectoralis major*; like that muscle, it adducts the arm. Placing one's fingers in the armpit, a thick muscle boundary is felt both in front and behind; the one in front, the anterior wall of the axilla, is the *pectoralis*, the one behind, the posterior wall, is the *latissimus*.

Under cover of the superficial muscles behind are the *erector spinæ* muscles, which grouped together form a

thick rounded belly stretching from skull to sacrum on each side of the vertebral column. It gains attachment to the ilium, vertebræ, ribs and skull, at different levels, and by its tonus helps to maintain the normal curves of the spinal column in the erect posture. Its action is to extend, i.e., straighten out, the spine, including the head and neck.

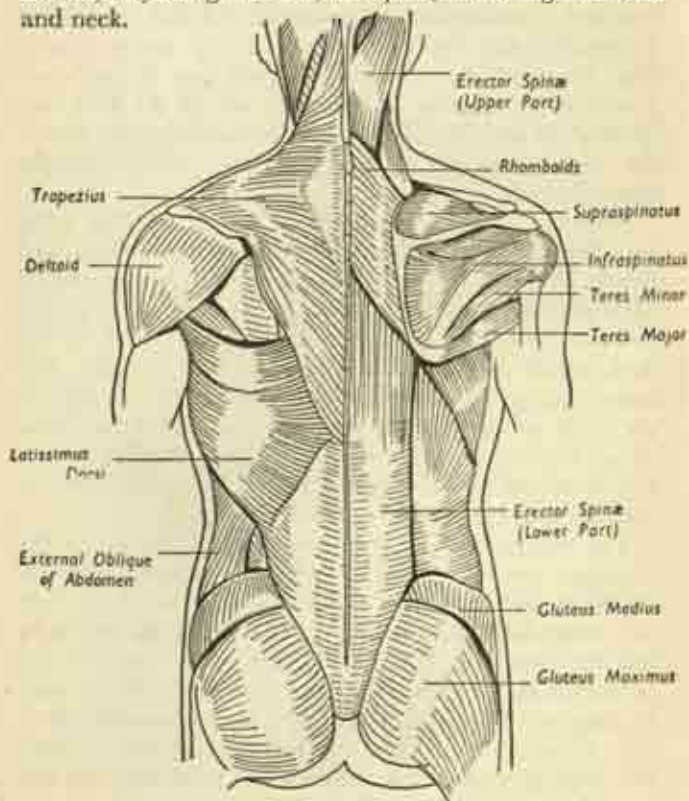


FIG. 115. Muscles of the back.  
On the right side the superficial muscle layer has been removed to expose the deeper structures.

### Surface Anatomy.

*Anterior.* If the clavicles are traced to their medial ends, there can be felt between them, in the hollow of the base of the neck, the manubrium of the sternum. Two inches lower, in the midline, the junction of manubrium and body of sternum is marked by a prominent ridge, the sternal angle; it is easy to feel the costal cartilage of the second rib attached here on either side.

The main body of the sternum is subcutaneous, a broad plate of bone ending below as the little xiphoid process, which is rather depressed below the surface in the angle formed by the meeting of right and left costal margins. The ribs are attached on each side of the sternum and are best numbered by first locating the second rib, as indicated, and then counting downwards; for the inner ends of the first rib lies so deeply beneath the clavicle that it cannot easily be felt. The ribs are palpable well out into the side and even round to the spine, depending on the amount of overlying fat and muscle; and the intercostal spaces are to be felt as depressions between.

The *nipple* lies in the fourth space in men (i.e., between fourth and fifth ribs), but is more variable in women owing to the size of the breast; the female breasts are described in Chapter XIII. The beating of the apex of the heart is felt or seen just medial to the left nipple, i.e., in the fifth space on the left side, some three and a half inches from the midline, but this again is inconstant.

The surface markings of the heart, lungs and pleura, are shown in Plate 7. Note that the lungs do not extend quite as far as the lower borders of the pleural cavity; this does not imply an empty pleural space below; the space is potential only, comprising simply a narrow cleft here between diaphragm and chest wall where the two pleural layers come in contact. The apex of the

<sup>1</sup> The pleura is the lining membrane of the chest cavity, cf., the peritoneum in the abdominal cavity.

pleura just emerges into the root of the neck on each side; and the two pleural sacs touch each other behind the sternum.

*Posterior.* The back of the chest is obscured by the overhanging shoulder-blades above on each side, and by the great muscle masses of this region. The spinous processes of the thoracic vertebræ are felt in the midline, but the ribs lie deeply and can only be felt by heavy palpation. The eleventh and twelfth ribs are quite short, extending outwards for only a few inches on each side of the spine.

### Thoracic Cavity.

The thoracic cavity is divided into right and left halves by a massive partition, the *mediastinum*, which lies in the sagittal midplane, stretching from the back of the sternum to the vertebral column. Vertically, it extends from thoracic inlet above to diaphragm below. The two halves of the cavity are completely separate, and contain the right and left lungs. Each lung is attached to the mediastinum at its root or *hilum* by its bronchus (air-tube) and blood-vessels.

The cavity is lined by a smooth serous membrane, the *pleura*, which facilitates the gliding of the lung on the chest wall. Each pleural space is thus a closed sac, for the pleura, like the peritoneum, is divided into *parietal* and *visceral* layers which are everywhere continuous. The *parietal pleura* clothes the deep aspect of the ribs, the upper surface of the diaphragm, and the sides of the mediastinum; and the *visceral layer* encloses the lung, the two layers being continuous along the root of that organ. The apex or dome of the pleural sac rises into the root of the neck, a little way above the clavicle on each side; and its base overhangs the liver in front and the upper poles of the kidneys behind. Though the lung closely follows the pleural distribution, it does not reach



quite as far as its upper and lower limits. Normally there is no actual pleural cavity, for the two layers are in contact, the lung entirely filling its side of the thorax. But the lung is a very elastic structure, constantly tending to shrink down and expel its contained air. This cannot occur normally, and a negative pressure is thus set up in the potential pleural space; the moment that air is

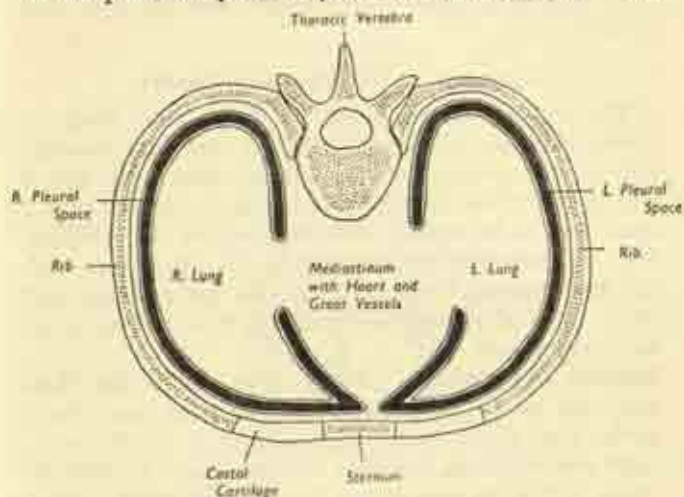


FIG. 116. Cross-section of the chest to show its division into right and left halves by the mediastinal partition.

admitted to the latter, by wound from without or perforation of the lung from within, the lung immediately shrinks into a small, solid, airless mass collapsed against the mediastinum. This is made use of in the treatment of pulmonary tuberculosis, where a diseased lung is rested by the deliberate introduction of air into the pleural cavity to form what is known as an artificial pneumothorax.

The *heart* is embedded in the mediastinum itself, occupying a central position in the chest between the two



lungs, though extending more towards the left side. It is enclosed in a fibrous sac, the pericardium, which rests on the central tendon of the diaphragm below. Plates 8 and 9 show the right and left sides of the thoracic cavity after removal of the lungs; it can be seen how the intervening mediastinal partition is packed solidly with vital structures—heart, great vessels, trachea and oesophagus.

### Contents of the Thoracic Cavity

The general arrangement of heart and lungs is indicated in figs. 95 and 117. Fig. 95 shows the thoracic viscera after removal of the anterior chest wall, and it will be noted how the lungs overlap the heart that only a small part is in contact with the back of the sternum. Fig. 117 shows the organs removed from the chest, with the lungs turned back to expose the great vessels and heart; the fibrous bag or pericardium enclosing the latter has been opened.

**Trachea and bronchi.** The *trachea* enters the chest from the neck at the thoracic inlet and runs down to the level of the sternal angle, where it divides into a *right* and *left* main *bronchus* for each lung. In its short course it has the oesophagus behind, separating it from the spine, and the great vessels—aorta and superior vena cava—in front, separating it from the back of the sternum. The bronchi enter the lungs at their roots, together with the pulmonary arteries and veins; and all these structures are shown cut across in Plates 8 and 9 as they project laterally from the mediastinum to reach the hilum of the lungs. Trachea and bronchi have in their walls numerous cartilaginous rings which keep the hollow tubes from collapsing and maintain a free air-passage. In the trachea these rings are deficient behind, so that the windpipe is semicircular in section. (See fig. 129.)

## Lungs.

The lungs are light spongy organs designed to provide the maximum internal surface area for the interchange of oxygen and carbon dioxide between air and blood. Pink at birth, they become increasingly bluish-black with age in town-dwellers, owing to the carbon deposited from inhaled smoke. A fine reticular pattern on the surface indicates their underlying subdivision into small lobules.

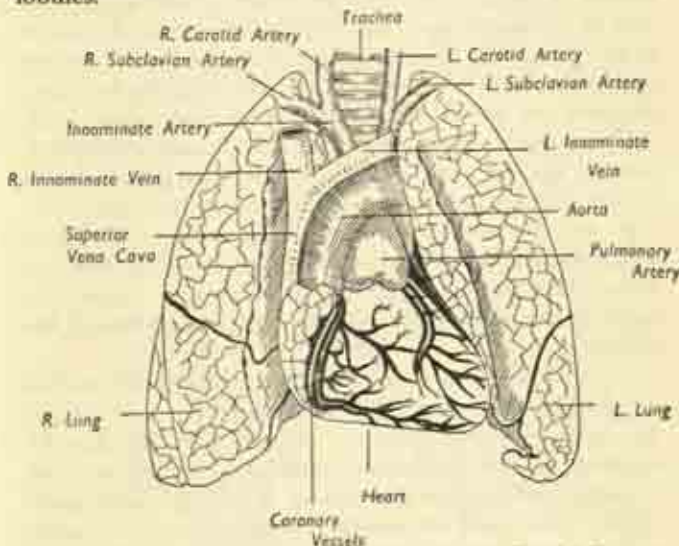


FIG. 117. Lungs, heart and great vessels, seen from in front after removal from the chest. The lungs normally overlap the greater part of the heart and have been retracted to expose that organ. (After Gray).

Each lung is divided into a main upper and lower lobe by an oblique fissure running downwards and forwards; and the right lung has in addition a third lobe, marked off from the upper lobe by a short transverse fissure. The lungs are permeated by elastic tissue, and the action of

this has been referred to. When removed from the chest, they immediately collapse to a quarter of their normal size. The whole or any part of the organ floats in water, unless rendered solid by disease.

The lungs lie free in the chest, enclosed in the visceral pleura, and are attached only by their roots to the mediastinum. The *apex* of each organ rises into the root of the neck,  $1\frac{1}{2}$  inches above the first rib, i.e.,  $\frac{1}{2}$  inch above the middle of the clavicle. The *base* rests on the upper surface of the diaphragm and is hollowed out by the bulge of that partition, which separates it on the right from the right lobe of the liver; and, on the left, from the left lobe, stomach and spleen. The *outer surface* is in contact with the deep inner aspect of the chest wall and is therefore marked by the overlying ribs. The rounded *posterior border* fits into the recess at the side of the thoracic vertebræ; and the sharper *anterior border* overlaps the heart and pericardium on each side. Because of the preponderant bulk of the heart on the left side, there is a well-marked cardiac notch in the anterior border of the left lung.

The *medial surface* faces inwards towards the mediastinum and on it is situated the hilum. The relations of the medial surfaces differ on the two sides, for they lie opposed to the mediastinal structures, which are not arranged symmetrically. Plates 8 and 9 show more clearly than words the general pattern of these structures, which make deep indentations on the lungs. The main differences are :

(i) the curvature of the arch of the aorta over the left bronchus to the left side and the prominence of the descending aorta on the left side;

(ii) the presence of the superior vena cava on the right;

(iii) the right-sided position of the oesophagus below.

*Internal structure of the lungs.* Each main bronchus divides into a branch for each lobe and these branches divide and subdivide within the lobes into a ramifying bronchial tree of fine bronchioles; all these subdivisions

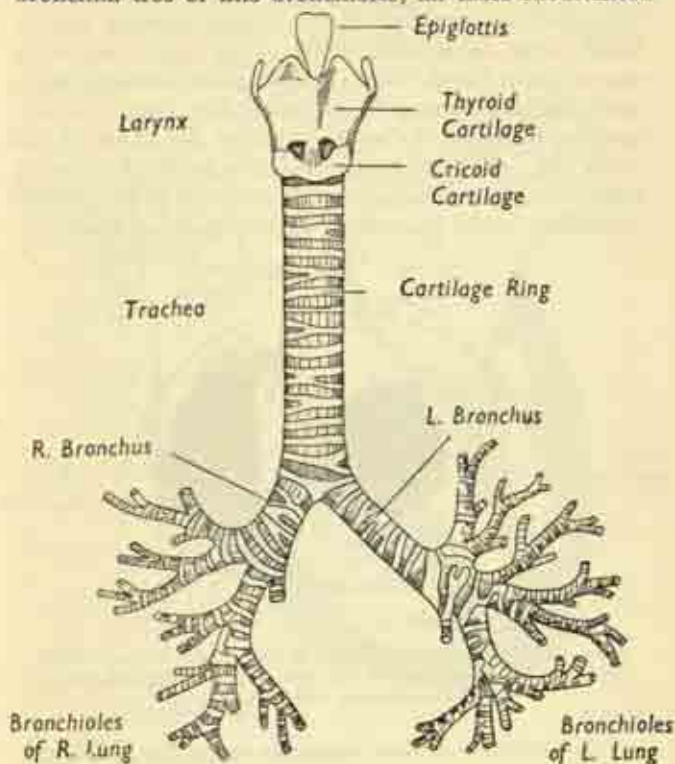


FIG. 118. The Respiratory passages.

are accompanied by corresponding branches of the pulmonary artery and vein. Each bronchiole ultimately ends in a cluster of tiny air-filled sacs or alveoli; and the gaseous interchange occurs between their contained air G\*

and gases dissolved in the blood of the capillaries which encircle the alveoli. Each lung lobule is composed of a terminal bronchiole and its air-cells, and the lung is composed of millions of lobules bound together by elastic connective tissue. Note that, whereas arteries usually convey fresh oxygenated blood to an organ and veins remove stale blood with excess carbon dioxide, these conditions are reversed in the lungs. For, since it is their function to renew the oxygenation of the blood of the whole body, the blood brought to them by the pulmonary artery is really venous, while that returned to the general circulation in the pulmonary veins is fresh and arterial.

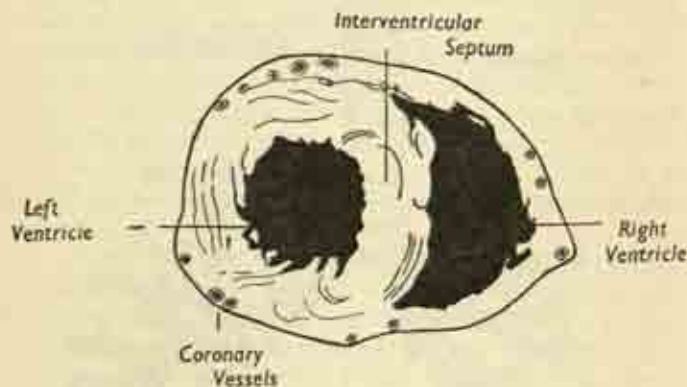


FIG. 119. Cross-section of heart in ventricular region. Note the greater thickness of the left ventricle, the massive septum, and the coronary vessels cut across.

### Heart.

The heart is a hollow muscular organ lying between the lungs in the mediastinum; it is enclosed in the *pericardium*. This membrane has a tough outer *fibrous layer* which is firmly blended below with the central tendon of the diaphragm; and a delicate inner *serous layer*. The serous pericardium lines the fibrous capsule and is reflected at the roots of the great vessels of the heart to



cover the organ itself, i.e., there are parietal and visceral layers just as with the pleura and peritoneum, with a potential pericardial cavity.

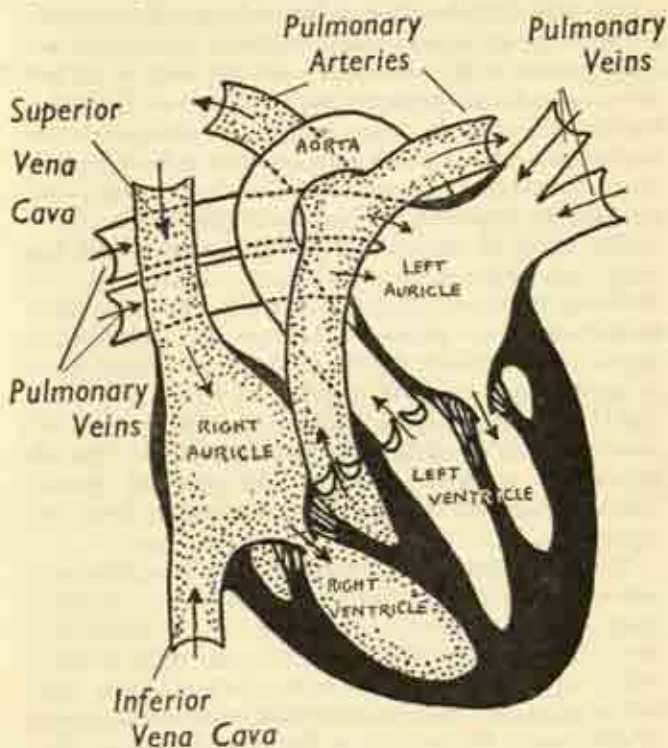


FIG. 120. Diagram showing the interior of the heart, entry and exit of the great vessels, and the direction of blood flow. The diagram is artificial in that no section normally exposes all four chambers in this way.

The heart itself is composed of four hollow chambers, the two *atria* above which receive blood from the great veins, and the two *ventricles* below which expel it into



the great arteries. Though the atrium and ventricle of the same side communicate freely, they are completely shut off from the opposite pair by a muscular *septum* which is much thicker between the ventricles than between the atria. The latter are thin-walled compared to the fleshy muscle of the ventricles; and the wall of the left ventricle is considerably thicker than that of the right. On the surface of the organ grooves or sulci indicate the demarcation between the chambers, and in these grooves run the little (but all-important) *coronary vessels* which nourish the muscle of the heart itself (fig. 117).

The shape of the heart is roughly conical, with the apex directed to the left and slightly downwards. Its surface projection has been indicated in Plate 9, and the anterior surface, behind the sternum and costal cartilages, is formed mainly by the right ventricle with a little of right atrium and left ventricle on either side. The right border is entirely right atrium, the left border is left ventricle, and the apex is the tip of the latter. The left atrium lies entirely behind, on the posterior surface, which is directed to face the vertebral column, the oesophagus and descending aorta intervening.

**The attachments of the great vessels.** Two great veins enter the right atrium, the *superior vena cava* at its upper part and the *inferior vena cava* at its lower. This venous blood flows through the chamber to the right ventricle and is expelled into the *pulmonary artery* arising from its upper border, going to the lungs in the two branches of this vessel. At the back of the heart four *pulmonary veins* return fresh blood from the lungs to the left atrium, which passes it on to the left ventricle; and the latter expels it to the great *aorta*, the wide arterial trunk which is the commencement of the general body circulation. Though the aorta rises on the left and the pulmonary artery on the right, this relation appears reversed from in front because the two vessels are spirally intertwined.

**The interior of the heart.** The openings between the chambers, and between the ventricles and their great arteries, are guarded by a system of cardiac *valves*. Between each atrium and its corresponding ventricle is a parachute-like valve, the strands of which are attached to the ventricular wall, the flaps lying in the orifice between the chambers. On the right this is known as the *tricuspid* valve, with three flaps; on the left, as the *mitral*, with two. When the atria contract the blood stream easily separates the valve-flaps as it passes into the ventricles; but when the latter undergo their contraction, or *systole*, the flaps are ballooned out, the guy-ropes of the valves are tautened and no backflow is possible, all the blood being directed into the arterial exits. These latter, the openings into the pulmonary artery and aorta from the corresponding right and left ventricles, are guarded by simpler valves composed of 3 semilunar pockets facing upwards. These are easily pushed apart by the blood surge but fall together when the ventricles relax in *diastole*, the weight of the blood column in each pocket forcing them into a close contact and effectively blocking any reflux.

**Great vessels of the thorax.** (Plates 8 and 9.) The *superior vena cava* is formed by the junction of the right and left *innominate veins*, each bringing venous blood from one arm and one side of the head and neck. The right innominate and the vena cava itself run vertically in a straight line continuous with the right atrium. But the left innominate crosses from one side to the other in front of the trachea and just above the arch of the aorta.

The *inferior vena cava* rises from the abdomen through the central tendon of the diaphragm and has only a very short intrathoracic course before it enters the lower part of the right atrium.

The *pulmonary artery* arises at the upper border of the heart from the summit of the left ventricle and twines

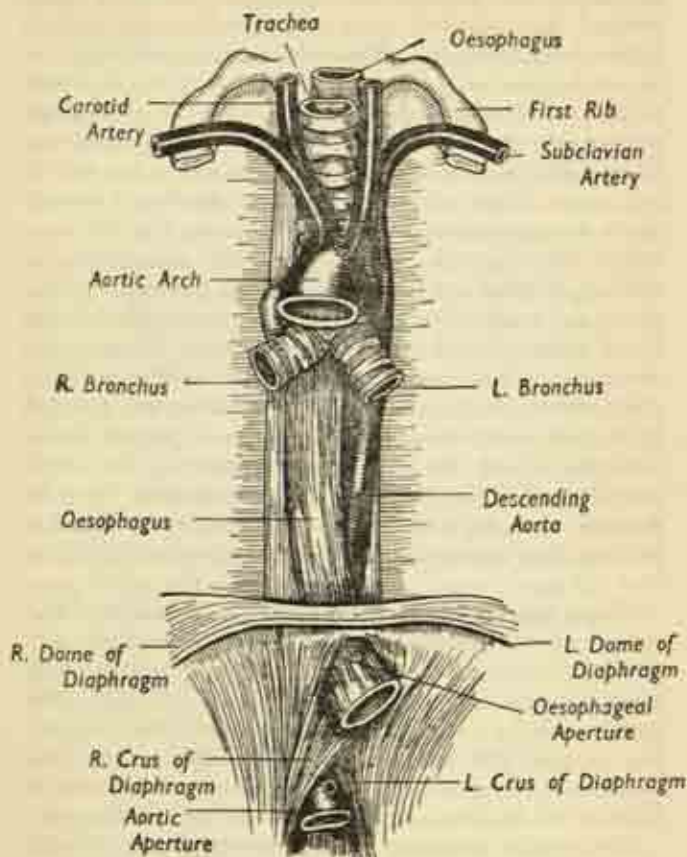


FIG. 121. Structures of the posterior thoracic wall : oesophagus and descending aorta. The heart and lungs have been removed. (After Gray).

round the aorta so that the two vessels are related in the same way as are adjacent fingers when crossed over each other. Behind the aortic arch it divides into the right and left pulmonary arteries which pass out of the mediastinum into the roots of the lungs with the corresponding pulmonary veins and bronchi. The *pulmonary veins* are not seen from in front; two on each side, they drain into the back of the left atrium.

### **Aorta.**

This is the largest artery of the body, the beginning of the general or *systemic* circulation—as opposed to the local *pulmonary* circulation. It arises at the upper border of the heart from the summit of the left ventricle and its subsequent course is as follows:

(i) a short *ascending portion* running up to the left of the superior vena cava;

(ii) the *aortic arch* curving horizontally backwards in front of the lower part of the trachea and over the left bronchus;

(iii) the *descending aorta* running downwards on the vertebral column at the back of the thoracic cavity, to pass through the diaphragm where it becomes continuous with the abdominal aorta.

**Branches of the aorta.** From the summit of the aortic arch three great vessels arise. On the right is the *innominate*, which divides into the right *subclavian* artery for the arm and the right *common carotid* for the head and neck. On the left there is no innominate artery, the left subclavian and carotid springing directly from the arch. Only the lower parts of these great vessels lie within the thorax, the level of the innominate bifurcation being at the inner end of the clavicle; they lie closely applied to the front and sides of the trachea. The corresponding veins lie more superficially and there is an innominate vein on both sides and not only on the right; the vessel

equivalent to the common carotid artery is the internal jugular vein. The little *coronary arteries* arise from the very beginning of the aorta, immediately above the semi-lunar valves; there is a right and left vessel and any disease of these seriously or fatally impairs the local circulation in the muscular wall of the heart itself; indeed coronary disease after middle life is a common cause of heart attacks and sudden death.

The *descending aorta* gives off on each side the pairs of *intercostal arteries* which encircle the chest in the intercostal spaces; note that the corresponding veins do not enter the *venæ cavæ* directly but through separate intervening channels, the *azygos veins*.

It can be seen that the aortic arch forms a great sweep from the front of the chest to the back, with an upward convexity from which arise the main arteries of the head, neck and arms. Plate 9 shows this and also how the concavity of the arch embraces the pulmonary arteries and veins and the bronchi, i.e. the structures entering the roots of the lungs. Note also in this Plate a little artery running the whole length of the back of the sternum from above downwards; this is the *internal mammary artery*, a branch of the subclavian in the neck, and we have seen that it ends below by entering the sheath of the rectus muscle as the superior epigastric artery to anastomose with the inferior epigastric coming up from below.

The arch of the aorta not only carries it backwards but also inclines it to the left, so that the descending portion is rather to the left of the midline and nearer the left lung than the right.

#### **Remaining structures of the posterior thoracic wall.**

The *oesophagus* or gullet enters the chest from the neck at the thoracic inlet, lying immediately in front of the vertebral column; it travels down the middle of the back of the cavity between the roots of the lungs, to



traverse the diaphragm below. It does not pursue a straight course, for it inclines forward and to the left in its passage, allowing the descending aorta to intervene between its lower portion and the spine; and it is more closely related to the right than the left lung. It is a hollow muscular tube down which food is propelled to the stomach by waves of contraction or *peristalsis*; unlike many other parts of the bowel, it has no serous coat as it lies entirely away from the pleura at the back of the mediastinum. For this reason, any infection arising from a perforation of this tube does not get sealed off and usually spreads diffusely with fatal results.

The *thoracic duct* begins below, as we have seen, as the upward continuation through the aortic aperture of the diaphragm of the cisterna chyli of the abdomen, the channel receiving digested fat from the bowel as well as the lymphatic drainage from the legs. The duct ascends on the front of the vertebral column in the chest, lying just to the right of the aorta, behind the oesophagus; it crosses to the left side at the level of the aortic arch, enters the root of the neck on that side and discharges its contents into the junction of the left subclavian and internal jugular veins. Because this is the main channel for the absorption of fat, any wound of the duct which disperses its contents by leakage before they enter the blood stream results in serious or fatal wasting, even though the injury is not otherwise serious.

#### **Nerves within the thorax.** (Plates 8 and 9.)

The important nerve trunks within the thoracic cavity are these:

- (i) The *vagus* nerves, one on each side. These are the tenth pair of cranial nerves which have travelled down the neck and entered the thoracic inlet. The *right vagus* runs alongside the trachea; passes behind the right lung-root, where it breaks up into a



pulmonary plexus; reforms again as a single trunk and accompanies the oesophagus through the diaphragm. The *left* vagus runs with the left carotid and sub-clavian arteries; crosses the arch of the aorta; passes behind the left lung-root to form a similar plexus; and finishes the rest of its thoracic course alongside the oesophagus as does the right. The vagi are part of the great *parasympathetic* system described at p. 267 concerned with automatic regulation of the viscera; in the chest they give branches to heart, lungs and oesophagus.

(ii) The *sympathetic* trunks lie one on each side, an inch or two away from the vertebral bodies. They consist of a chain made up of a number of sympathetic *ganglia* lying on the necks of the ribs behind the parietal pleura, and connected by the longitudinal sympathetic fibres. This chain is continuous with that in the neck above; and leaves the thorax below with the *psoas* muscle to become the abdominal sympathetic. It also is part of the *autonomic* or *vegetative nervous system* and shares with the vagus the dual control of the viscera. Plates 8 and 9 show several branches running down from the main trunk; these are the *splanchnic nerves* which pierce the diaphragm to join the coeliac or solar plexus we have already noticed surrounding the commencement of the abdominal aorta.

(iii) The *intercostal nerves*, derived from the spinal cord, run round the chest wall in the intercostal spaces with the corresponding vessels. At their origins they lie deeply behind the pleura and are connected to the sympathetic ganglia by little communicating twigs which link the voluntary and involuntary nervous systems into a whole.

(iv) The *phrenic nerves* arise in the lower part of the neck for the supply of the muscle of the diaphragm.

The right phrenic runs down alongside the superior vena cava and the right side of the heart; the left crosses the aortic arch and the left side of the heart. Both pierce the dome of the diaphragm and break up into twigs on its under-surface.

## CHAPTER IX

### HEAD AND NECK

#### THE HEAD

##### **The Skull.**

THE skull is an intricate framework of many bones fitting into each other in jigsaw fashion at the immobile fibrous sutures. Though complicated at first sight, it is easily understood by reducing it to its three essential parts—cranium, facial skeleton, and mandible.

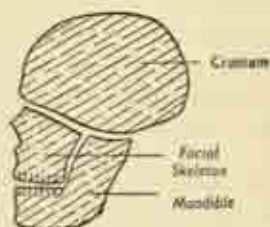


FIG. 122. The basic plan of the skull.

The *cranium* is the bony box enclosing the brain and its membranes; it has a domed vault and a base set deep beneath the soft structures.

The *facial skeleton* is attached to the underside of the base anteriorly, and includes the nasal bone, maxilla (upper jaw), and others.

The *mandible* or lower jaw is entirely separate and slung to the underside of the base at the back by a freely-mobile joint.

The skull bones are mostly flat; in several places, particularly the vault, they have an outer and inner table of compact bone sandwiching a loose red-marrow-filled layer—the diploë. And at certain sites they are expanded by internal air spaces or *sinuses*.

*Frontal Bone*

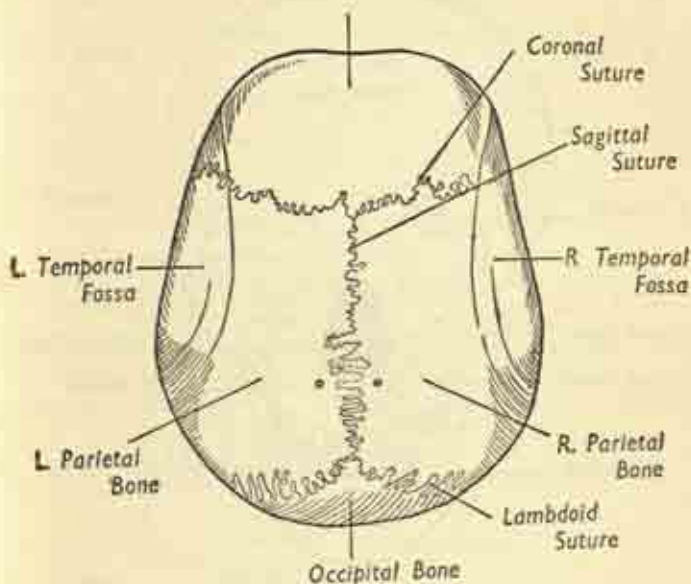


FIG. 123. The vault of the skull, or vertex, from above.

The vault is made up of 4 main bones—frontal, two parietals, and occipital. The *frontal* bone is the substance of the forehead and overhangs the orbital cavities in front. The *parietals* lie on each side above the temples, and the *occipital* at the back of the head. The *coronal suture* separates frontal and parietals; the *sagittal suture* divides the two parietals in the midline; the *lambdoid suture* posteriorly is the meeting-place of parietals and occipital.

At birth, the angle of junction at either end of the sagittal suture is a small space unclosed by bone and filled in with membrane, the anterior and posterior *fontanelles*;

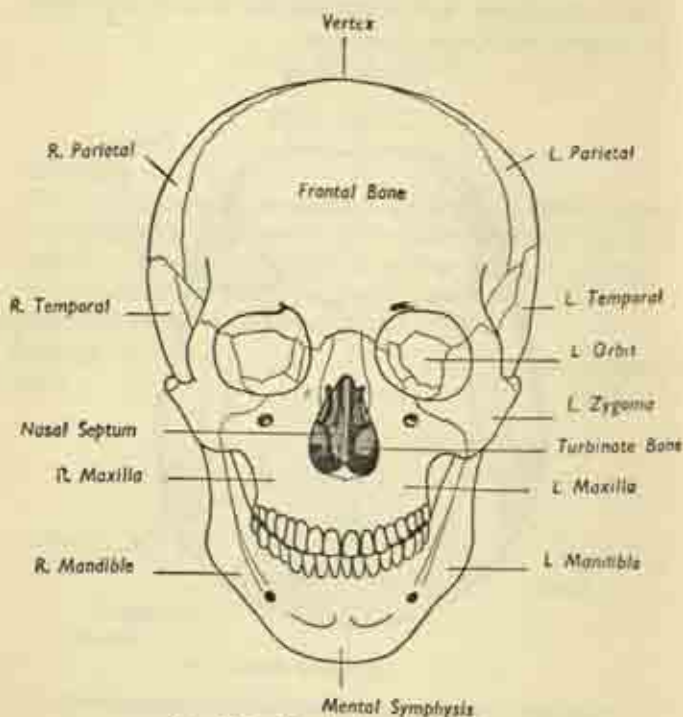


FIG. 124. The skull, anterior view.

the posterior is closed by the end of six months, the anterior not till the second year. The vault is very resilient and often yields to violence without fracturing; but it may transmit a compression-wave round to the rigid base so that the latter undergoes an indirect fracture.

Figs 124 and 125 are anterior and lateral views of the

whole skull. Note, in the anterior view, the frontal bone coming down as a roof over the *orbital cavities*, the bony eyesockets; the openings of the *nasal cavities*, with the nasal bones above and the bony nasal septum separating the two sides; the *maxilla* or upper jaw carrying the upper teeth. Note, in the *lateral view*, the side aspect of the vault and how the temporal bone helps to form the lower part of the sidewall in the hollow above the cheek;

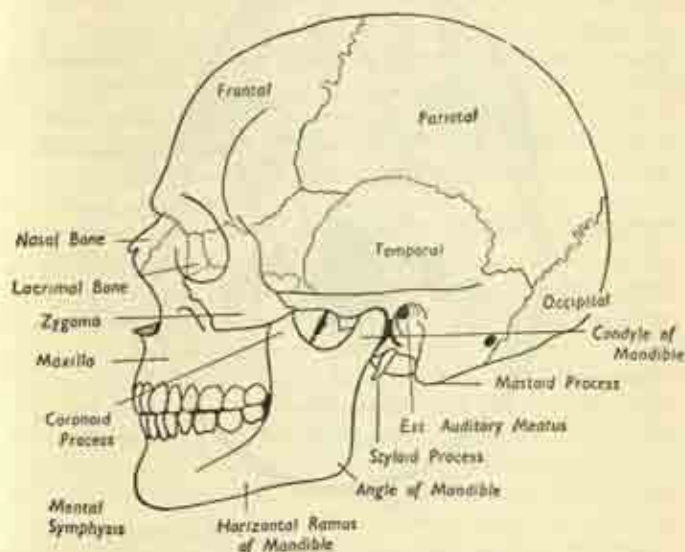


FIG. 125. Lateral view of skull.

the cheek bone or *zygoma* arching across from maxilla to temporal; the *mastoid process* behind the bony external opening of the ear canal; and the *styloid process* jutting out from the base below.

### The skull base.

If we remove the skull cap and look in, our view of the upper surface of the base is shown in fig. 126.



Note the great *foramen magnum*, nearer the back, where the spinal cord becomes continuous with the medulla of the hindbrain; and the numerous scattered smaller *foramina* where veins and cranial nerves make their exit and the cerebral arteries their entry. At various places the inner table is grooved by narrow channels for

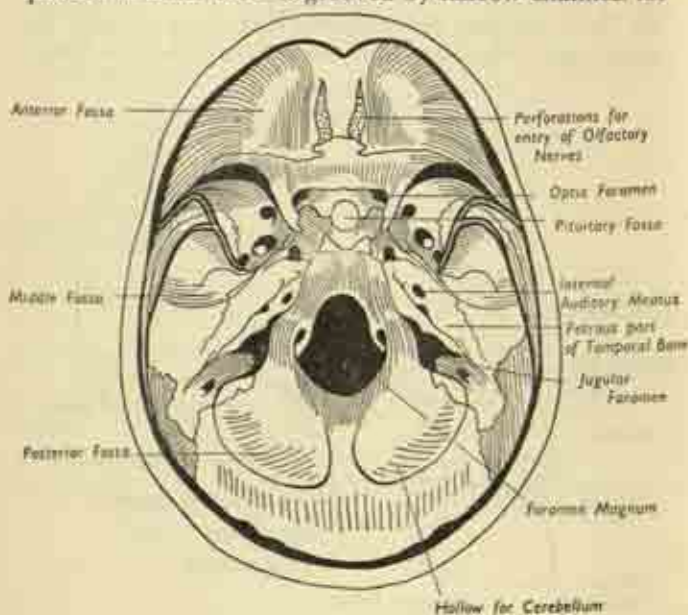


FIG. 126.

The skull base, seen from within, after removal of the skull cap, the meningeal arteries supplying the brain membranes; or marked by wider paths for the venous sinuses which flow between the layers of the dura mater, the outermost of these coverings. The base is divided on each side into three pockets or *fossae* which become successively deeper and more extensive from before backwards.

The *anterior fossa*, right in front, houses the frontal

lobe of the brain; and its floor is the roof of the underlying orbit and nose. Where the two anterior fossae meet in the midline, tiny perforations in their floor exist for the upward passage of the olfactory nerves from nose to brain.

The *middle fossa* houses the temporal lobe of the brain; through a little opening just behind the anterior fossa the optic nerve connects eyeball and brain. In its floor can be seen large foramina for the exit of the fifth or trigeminal cranial nerve, concerned with sensation in face and jaws and the movement of the masticatory muscles; and for the entry of the internal carotid artery into the skull. Note, between the two middle fossae, a little pocket embedded in a small raised platform; this is the *pituitary fossa* in which lies the pituitary gland, slung from the undersurface of the brain.

The *posterior fossa* is separated from the middle by an obliquely-lying bony ridge, the petrous portion of the temporal bone, a mass enclosing the inner-ear cavity and containing the opening of the internal auditory meatus for the passage of the eighth (acoustic) nerve from ear to brain. The posterior fossa is mainly composed of the occipital bone; it contains the foramen magnum and a large jugular foramen for the exit of the internal jugular vein accompanied by various nerves.

On the undersurface of the base, on each side of the foramen magnum, are two articular processes or condyles, forming a joint with the first cervical vertebra, the atlas.

The *mandible* is formed by two symmetrical halves joining in the midline anteriorly at the chin, the *mental symphysis*. Each half consists of a horizontal *body* carrying the lower teeth on its alveolar (gum) margin; and a more or less vertical *ramus*. Body and ramus are connected at the angle of the mandible, an angle which is rather obtuse in infancy, approaches 90° in the adult, and

recedes again in edentulous old age. At the upper end of the ramus are the pointed *coronoid process*; and the rounded *condyle* which articulates with the undersurface of the temporal bone at the *temporo-mandibular joint* in front of the ear (fig. 125).

The *air-sinuses* of the skull are mostly accessory to the nose, i.e. they are extensions of the nasal cavities and their lining mucous membrane is similarly continuous, even though the connecting passages may be intricate and narrow. The main ones are the *frontal* and *maxillary*; there are also certain groups deep in the skull—*ethmoids* and *sphenoids*. The maxilla is entirely hollowed out by a great cavity, the *maxillary antrum*. All these are susceptible to infection derived from the nose, and because their drainage is so imperfect they may perpetuate the infection in chronic suppurating pockets. The *mastoid* air cells, which honeycomb the mastoid process, are independent structures, but are often infected from the middle ear.

The *hyoid* is a little bone which can be felt in the neck in front, between chin and larynx, giving attachments to the muscles of the floor of the mouth and the tongue. It has a tiny body with spreading lateral wings.

### Surface Anatomy of the Head.

Most of the external surfaces of the cranium, facial skeleton and mandible are easily palpable through the skin, though the base is of course quite inaccessible. In the *cranium*, the vault can easily be felt through the overlying scalp, which is freely mobile over the bone. In front, the overhanging ridges of the frontal bone, which are the upper margins of the orbital cavities and lie immediately beneath the eyebrows, meet in the midline at the depression of the root of the nose. There are four bulges on the vault, the *frontal eminences* of the forehead and the *parietal eminences* a couple of inches above

the ears. And the lowest accessible part of the skull in the midline posteriorly is the external protuberance of the occipital bone, which is also arrived at by tracing upwards the median furrow between the muscle masses at the back of the neck.

In the *face*, the *nasal* bones are the firm skeleton of the upper part of the nose, but the softer bulbous portion at the tip is supported by cartilage only; a finger in the nostril touches the *septum* between the two nasal cavities and this again is cartilage in front, the bony septum being further back out of reach. The *zygomatic arch*, the cheek bone, is felt running between the orbit and ear; and above it is the depressed temporal fossa; in this lies the *temporalis* muscle which shuts the mouth and can be felt to contract on clenching the teeth.

The *auricle* is the external visible part of the ear, the actual aperture being the *external auditory meatus*; note that this channel is again cartilaginous to begin with, its bony portion being further in. Immediately behind the ear is the mastoid process, with its rounded tip below; and just in front of the ear, below the back of the zygoma, the condyle of the mandible can be felt moving at the *temporomandibular joint* when the mouth is opened and closed.

Body, ramus and angle of the mandible are all accessible, though the coronoid process is under cover of the zygoma and not palpable. The outer surface of the ramus is covered by the *masseter* muscle, which closes the mouth, and stands out on firm biting. If this muscle is so contracted by clenching the teeth, a small tubular structure can be rolled under the skin running parallel to the zygoma and a finger's breadth below; this is the duct of the parotid salivary gland running forward to open into the mouth.

The *scalp* includes all the superficial structures overlying the vault. Its skin is profusely supplied with hair



follicles, and the subcutaneous fat is a thin dense layer; beneath this is a muscle sheet which is most developed in the frontal and occipital regions as the frontalis and occipitalis bellies, connected by an aponeurotic sheet—the *galea*—stretching over the vault. The *galea* is separated from the bone by loose areolar tissue, and all the layers of the scalp are welded into one which moves freely over the skull when its muscles contract, as in raising the eyebrows. Retraction of these muscles causes

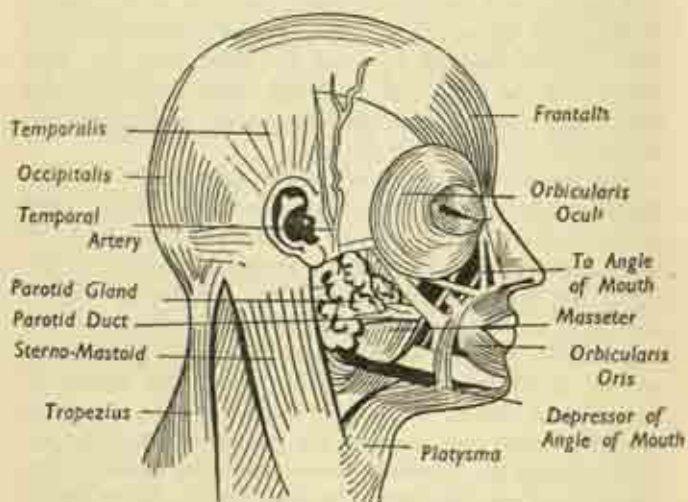


FIG. 127. Facial muscles and associated structures.

incised wounds of the scalp to gape widely; and wounds bleed freely as the arterial supply is abundant. The scalp veins communicate freely with those of the diploë, the venous sinuses of the dura, and of the brain; so that an external infection may spread inwards to the brain.

### The Face.

The *facial skin* is thin, mobile and vascular, and the

facial muscles or muscles of expression lie immediately beneath its dermal layer.

The muscles are shown in fig. 127. Note that both eye and mouth are surrounded by circular muscles, the *orbicularis oculi* and *orbicularis oris*, which shut the eyelids and lips. Small muscles attached to the nasal cartilages wrinkle the nose and dilate the nostrils. Others running up and down from the corners of the mouth lift or depress these angles; and the *platysma* muscle of the neck is a broad sheet which spreads up over the body of the mandible to take a share in the control of expression.

All these are supplied by the seventh (*facial*) cranial nerve, which leaves the base of the skull in front of the mastoid, runs forward in the parotid gland, and breaks up into diverging branches to face and scalp at its anterior border.

The *muscles of mastication* are a separate and deeper group supplied by the fifth (*trigeminal*) cranial nerve. They include the *masseter* and *temporalis*, already referred to as responsible for biting; and two others, the *pterygoids*, lying very deeply on the inner side of the ramus, responsible for the side-to-side and rotary movements of chewing. A very deep muscle, the *buccinator*, runs transversely between mouth and masseter in the substance of the cheek.

The *parotid salivary gland* lies under the skin in front of the ear, covering the back of the masseter; and reaches up to the zygoma and down to the mandibular angle. The facial nerve is embedded in it, and it overlies the internal carotid artery and internal jugular vein as they travel deeply between the neck and the skull-base. The *parotid duct* leaves its anterior border just below the zygoma, and runs forward on the masseter to open into the mouth by piercing the buccinator muscle opposite the second molar tooth.

The other external salivary gland is the submaxillary.



which lies below, and partly under cover of, the angle of the mandible; its duct pierces the floor of the mouth.

### Facial vessels and Nerves.

The *superficial temporal artery* runs up in front of the ear, where it can be felt pulsating against the bone, to supply the scalp. The *facial artery* ascends from the neck over the body of the mandible and runs obliquely upwards and forwards to the angle of eye and nose, giving branches to the lips on its way. Both vessels are branches of the external carotid, and the veins correspond in distribution.

The seventh (facial) nerve has already been mentioned, and is mainly motor to the muscles of expression.

The sensation of the face and scalp is supplied by the fifth (trigeminal) nerve, which also innervates the masticatory muscles.

Most of the lymph drainage of the face is to groups of parotid and submaxillary lymph glands; except from the lower lip, which goes to some small glands under the chin.

### The Mouth.

This is the first part of the digestive tract. It is bounded by the cheeks and lips at the sides and in front; roofed by the palate; and its floor is the muscular oral diaphragm, separating it from the neck, in which is embedded the root of the tongue. The oral cavity is everywhere lined by a glandular mucous membrane, and is continuous behind with the cavity of the pharynx. A minor part of the main cavity is the *vestibule*, the space between lips and teeth.

The red surface of the *lips* is the mucous membrane, which is sharply demarcated from the skin at the mucocutaneous junction; each lip has a branch of the facial artery running in it parallel to its free margin, and this is felt pulsating when the lip is gripped between finger and

thumb. Each is attached at its midpoint to the underlying gum by a fold of mucous membrane.

### The Teeth.

These are set in the opposed (alveolar) margins of the upper and lower jaws, where mucosa and underlying periosteum are firmly blended to form the gum. The first, temporary, set of milk teeth erupt at intervals throughout the first two years; the second, permanent,

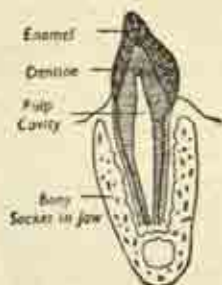


FIG. 128. Longitudinal section of tooth.

set begin to replace them at 6 years and are complete by 25, except for the last molar or wisdom tooth which is often delayed or may never appear.

The teeth are named from before backwards as *incisors*, *canine* (tearing), *premolars* and *molars* (grinding); and are symmetrical as between either side and as between upper and lower jaws, so that each quarter of the whole set is the same. This may be expressed in the formulæ:

Mol. Premol. Can. Inc. Inc. Can. Premol. Mol.

Upper	3	2	1	2		2	1	2	3	$= 32,$
Lower	3	2	1	2		2	1	2	3	

for the permanent dentition, and:

Upper	2	0	1	2		2	1	2	2	$= 20,$
Lower	2	0	1	2		2	1	2	2	

for the milk dentition. Note the smaller number in the latter owing to the absence of premolars.

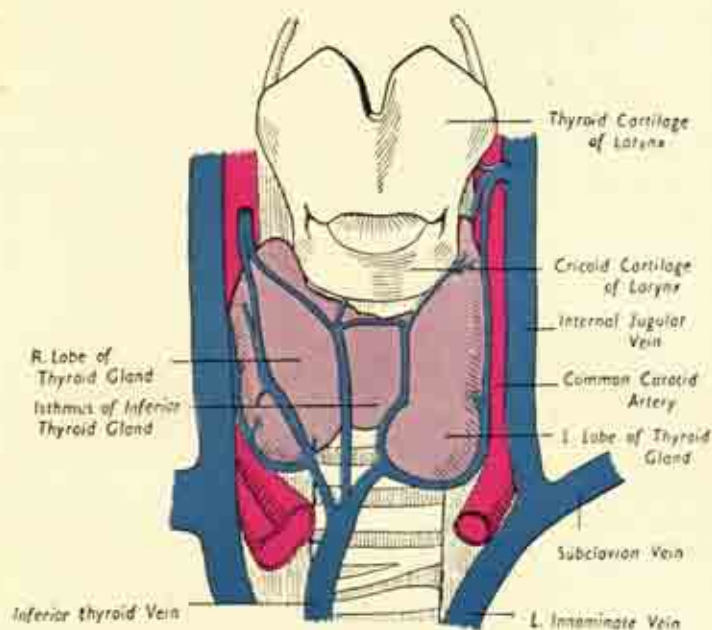
Each tooth has a visible *crown* projecting beyond the gum; a *root*, embedded in the alveolus; and an intermediate constricted *neck*. Longitudinal section shows the central *pulp cavity*, containing the soft vascular pulp and nerves; outside this the *dentine* or ivory, the main bulk of the tooth; and an outermost coating of thin hard *enamel*. The root is fixed in its socket by a layer of dental cement, and the vessels and nerves enter the pulp through a small foramen at the tip of the root (fig. 128).

The *palate* is the roof of the mouth, and the floor of the nasal cavity. It consists of the bony *hard palate* in front; and the mobile, muscular *soft palate* behind, projecting back into the pharynx. The soft palate is an arched structure, with its supporting pillars attached on either side of the back of the tongue; each of these pillars splits to enclose the *tonsil*, a mass of lymphoid tissue. From the free posterior edge of the soft palate there hangs down, midway between the tonsils, a small conical process, the uvula.

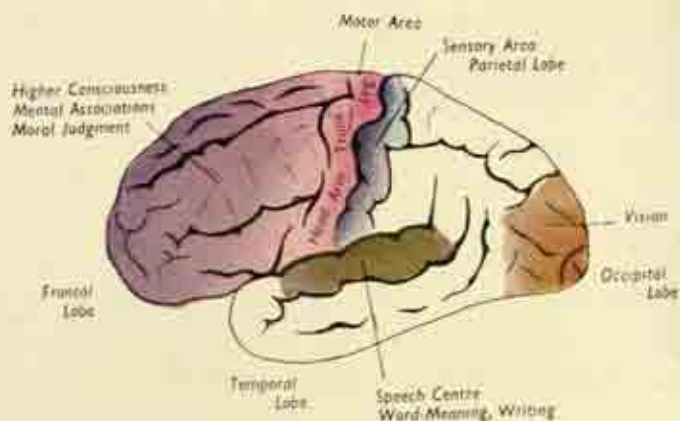
In the *floor of the mouth*, if the tip of the tongue is elevated, a fold or frenulum is seen tethering the under-side of the tongue to the mucous membrane; and where the frenulum is attached to the floor the duct of the submaxillary salivary gland opens on each side on a little papilla. Between the frenulum and the jaw on each side a loose mucosal flap can be seen, or rolled by the tongue; this is the sublingual fold overlying the *sublingual salivary gland*, which has many small ducts opening directly into the mouth cavity.

Parotid, submaxillary, and sublingual glands make up the three main salivary glands; they discharge saliva reflexly into the mouth with the stimulus of eating.

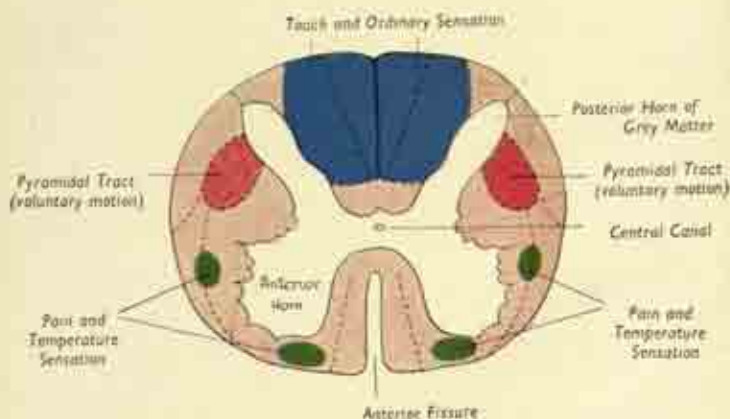
The *tongue* is a muscular organ concerned with swallowing, taste and speech. Its main anterior portion lies



Larynx, thyroid gland, great vessels of neck.  
(After Bruce and Walmsley.)



Functional areas in the left cerebral hemisphere. The right side is identical, save for the absence of a Speech Centre.



Cross-section of Spinal Cord, showing the important nerve tracts.

horizontally in the floor of the mouth; but the back of the tongue is curved round to lie more vertically, and forms the anterior wall of part of the pharynx. The *root* of the tongue is embedded in the oral diaphragm, and is attached by various muscles to the hyoid bone and mandible; and indirectly to the soft palate by the arches of the latter structure.

The *dorsum* is the upper surface and on it are a number of *papillæ*, hair-like processes, and *taste-buds*. The tip rests normally against the back of the upper teeth; and the under surface is attached to the floor of the mouth by its frenulum. In structure, the organ is mainly muscular, with right and left halves separated by a fibrous partition; it has a mucous covering which is specialized for the sensation of taste.

## THE NECK

The neck connects the head and trunk; its bony framework is made up by the 7 cervical vertebræ behind, and it is traversed by the food and air passages on their way to the chest, and by the great vessels and nerves running between the thoracic inlet and the base of the skull.

In addition, in the root of the neck on each side there is an outflow of nerves and vessels over the upper surface of the first ribs into the arms.

Cross-section of the neck shows the relative disposition of these structures. But it must be remembered that whereas a section above the level of the sixth cervical vertebra shows the air and food passages as larynx and pharynx, these at a lower level have become the trachea and oesophagus respectively.

The main points to be noted are (fig. 29):

- (i) the supporting *cervical vertebræ*, rather nearer the back of the neck;
- (ii) the thick *muscle masses* applied to the back of



the spine, the upper part of the great sacro-spinalis muscle;

(iii) the *oesophagus*, immediately in front of the spine;

(iv) the *trachea* between skin and oesophagus;

(v) the separate compartments of deep fascia on each side, the *carotid sheaths* in which run the *carotid artery*, *internal jugular vein*, and the *vagus nerve*.

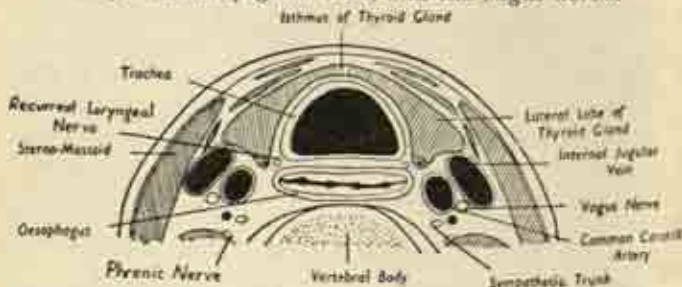


FIG. 129. Cross-section of the neck below the level of the 6th cervical vertebra. The section does not include the back half of the vertebra and associated spinal muscles. (After Gray).

Longitudinal section indicates the vertical arrangement, and the level of transition from larynx to trachea and from pharynx to oesophagus (fig. 131).

### Triangles.

The neck is conventionally divided into several triangles, which are marked off by the various muscles. The key to this pattern is the *sterno-mastoid*, a long flat rectangular muscle on each side, whose origin is by two heads from the inner end of the clavicle and upper border of the manubrium; it passes up and out to its insertion on the mastoid process. The area in front of the muscle is the anterior triangle; that behind it the posterior triangle (fig. 130).

The *anterior triangle* is bounded by the anterior mid-line of the neck and the anterior border of the sterno-

mastoid, meeting at the apex below; its base, above, is the mandible. It is further subdivided as shown into four smaller triangles. The *muscular triangle* contains several small flat muscles which depress the larynx in swallowing; the *carotid triangle* contains the upper part of the common carotid artery as it divides into internal and external carotids, the internal jugular vein, and important nerves; the *digastric triangle* contains the submaxillary salivary gland; and, the *submental triangle* only a few small lymph glands.

The *posterior triangle* is bounded by the back of the sternomastoid and the front of the trapezius, meeting at the apex at the occipital bone; and its base is the clavicle. It is divided by the tiny omohyoid muscle into an upper *occipital* and a lower *supraclavicular triangle*. The former is mainly muscular in content; but the latter contains the subclavian vessels and the brachial plexus of nerves, passing out on their way to the arm.

### Surface Anatomy of the Neck.

*Anterior.* The *sterno-mastoid* is very prominent especially when rendered taut by turning the head to the opposite side; then its sternal tendon can easily be picked up between finger and thumb. Between the sternal heads of the two muscles is the *suprasternal notch*, a skin-hollow resting on the upper border of the manubrium. The *external jugular vein* can usually be seen running under the skin obliquely down and back, superficial to the sternomastoid.

The main structures in the midline of the front of the neck, from above down, are as follows:

Feeling backwards in the hollow beneath the chin one reaches the small *hyoid bone*, with its wings on each side, felt when the throat at this level is grasped between finger and thumb. Immediately below the hyoid is the *laryngeal prominence*, or Adam's apple, composed of the

two halves of the thyroid cartilage meeting at a V-angle in front, and with a notch palpable at their upper border. Below this is the *cricoid cartilage* of the larynx, at the level of the sixth cervical vertebra behind; and lower still are the cartilaginous rings of the upper part of the *trachea*.

The pulsation of the *carotid arteries* is felt by pressure along the anterior border of the sternomastoids; behind this muscle, the posterior triangle is marked by a broad depression of the overlying skin, and at the base of this, behind the upper border of the clavicle, the *subclavian artery* can be felt beating on deep pressure. (Plate 10.)

*Posterior.* At the back of the neck the median longitudinal furrow between the muscle bellies overlies the indistinctly felt spinous processes of the cervical vertebrae.

### Fasciae and muscles of the Neck.

Just as elsewhere in the body, there is an envelope of deep fascia between the subcutaneous fat and the underlying muscles; in the neck this forms a continuous encircling sheet. But in addition there are deeper concentric layers, encircling the trachea and, deepest of all, the vertebral bodies. The muscles are partitioned off between layers of fascia, and a local condensation of this membrane forms on each side of the cylindrical carotid sheath containing the common carotid artery, internal jugular vein, and vagus nerve.

The cervical muscles are grouped as follows:

- (i) *Superficial: platysma, trapezius, sternomastoid.*

Trapezius and sternomastoid have already been met with. Both are supplied by the eleventh (*accessory*) cranial nerve. Each sternomastoid acts by bringing the ear down to the shoulder on its own side and turning the chin away to the other side; both acting together flex the cervical spine, bringing the chin down to the sternum.

The *platysma* is a muscle of facial expression, a broad sheet replacing the subcutaneous fat, without bony attachment. It arises from below the clavicle, and spreads up the side of the neck and inward over the body of the mandible to blend with the facial muscles at the angle of the mouth.

(ii) The *supra-hyoid* muscles are a small group between hyoid and mandible forming the floor of the

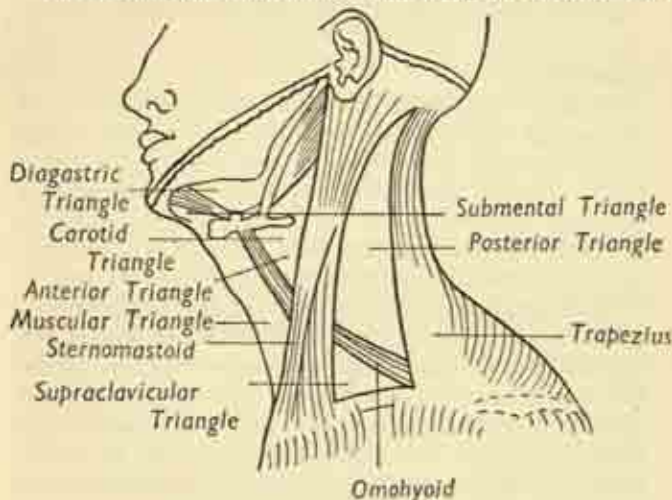


FIG. 130. Muscular triangles of the neck. (After Gray).

mouth, or oral diaphragm, and giving attachment to the base of the tongue.

(iii) The *infra-hyoid* group are several slender strap-like muscles descending from the hyoid bone and thyroid cartilage on each side of the midline to be attached to the back of the manubrium below. They depress the larynx in swallowing.

(iv) The *prevertebral* muscles are the deepest group, running up the front of the vertebral bodies behind

all the other structures of the neck; they help flex the cervical spine.

(v) The *scalene* muscles are found in the posterior triangle on each side, for they run downwards and out from the transverse processes of the cervical vertebrae to the upper borders of the first and second ribs. They elevate these ribs in inspiration and assume close relationship with the subclavian vessels and brachial plexus as these run out over the first rib to the arm.

### Pharynx.

In the lower part of the neck, and in the chest, the air passage (larynx and trachea) and the food passage (oesophagus) are quite separate. But in the upper part of the neck, above the entrances to larynx and oesophagus, there is a common cavity for food and air extending up as far as the base of the skull. This is the *pharynx*, situated immediately in front of the vertebral column.

In longitudinal section of the head and neck (fig. 131) it can be seen that the pharynx, from above downwards, is placed successively behind the nasal cavity, the back of the mouth, and the opening of the larynx, and it is divided therefore into *nasopharynx*, *oral pharynx*, and *laryngo-pharynx*. Its blind upper end reaches the under-surface of the base of the skull, and it is continuous below with the oesophagus at the level of the sixth cervical vertebra.

The pharyngeal wall itself is a muscular cylinder designed to propel food between mouth and oesophagus, and is composed of three *constrictor muscles*—*superior*, *middle* and *inferior*—roughly corresponding to the subdivisions of the cavity. In swallowing it is essential to prevent food passing upwards into the nose round the free back edge of the soft palate, or down into the larynx. Therefore the soft palate is opposed to the posterior pharyngeal wall so as to shut off the nasopharynx; and



the *epiglottis*, a flap of elastic fibrocartilage situated at the summit of the larynx behind the root of the tongue, is bent over backwards to shut off the entry into the larynx. During the act the larynx is pulled bodily upwards and then recedes again.

**Larynx.** (Plates 10 and 11.)


The larynx is the organ of voice and one part of the air passages of the respiratory system. It opens above into the laryngeal portion of the pharynx at the back of the tongue, and it is continuous with the trachea below; and it projects forward in the upper part of the neck with little to separate it from the overlying skin.

The skeleton of the organ is a framework of cartilages connected by ligaments and membranes to form a hollow resonating chamber containing the vocal cords. The *thyroid cartilage* is the largest; its two leaves meet in the midline as the projecting Adam's apple, with a superior notch opposed to the back of the hyoid bone. From the back of this notch arises the stalk of the *epiglottis*, a leaf-like fibrocartilage plate sticking up behind the hyoid and the base of the tongue. It guards the entry to the larynx by falling backwards to seal it off when swallowed food is passing through the pharynx. The *cricoid cartilage*, the lowest piece of the framework, is a signet-ring shaped structure, and immediately below is the first ring of the trachea.

The *vocal cords* are a pair of mucosal folds, strengthened by an underlying ligament, one on the deep surface of each thyroid leaf, stretching from front to back. The muscles associated with the larynx are either *extrinsic*, e.g., the infra-hyoid group, designed to move the organ as a whole as in swallowing; or *intrinsic*, concerned with the regulation of tension in the vocal cords. The latter may lie relaxed at the sides of the cavity, meet in the midline and shut off the airway completely, or occupy



an intermediate position, giving varying gradations of pitch. The interval between them is the *glottis*; this is the narrowest point of the respiratory tract and therefore the site most likely to be blocked by inflammatory swelling or the impaction of foreign bodies.

The *trachea* or windpipe is a hollow cartilaginous and membranous tube, some four inches long, extending from the larynx above through the thoracic inlet to its bifurcation into the two bronchi. It is not a cylindrical but a D-shaped tube, with the convexity under the skin of the front of the neck, and the base of the  resting on the oesophagus behind, which separates it from the vertebral column. Its framework consists of a number of cartilaginous rings, incomplete behind, with connecting membranes. In the neck, the second, third, and fourth rings are crossed by the narrow isthmus connecting the two lobes of the thyroid gland, one of which lies on each side. And the common carotid arteries lie beside the trachea, the thoracic relations of which have already been discussed (p. 198).

The trachea has a lining mucous membrane which, like that of the other parts of the respiratory tract, is *ciliated*, i.e., each cell bears a hair-like process which wafts such foreign irritants as particles of dust upwards toward the base of the tongue, where they are all swallowed.

The *oesophagus* has been discussed already, in part, in Chapter VIII. About 10 inches long, it is a muscular channel for the passage of food between pharynx and stomach. In the neck it begins at the level of the cricoid cartilage as the continuation of the lowermost portion of the pharynx. It descends on the front of the vertebral column behind the trachea and enters the thoracic inlet.

The *thyroid gland* is one of the group of endocrine or ductless glands which includes the pituitary, suprarenals, etc. It lies in the lower part of the neck as a right and

left lobe on each side of the trachea, with a connecting isthmus crossing that tube (Plate 11). Each lobe is pyramidal in shape, apex upwards, and is applied to the sides of the cricoid and thyroid cartilages; laterally it overlaps the carotid sheath. The gland is exceedingly vascular and composed of numerous tiny vesicles containing *thyroxin*, the secretion essential for normal growth, bodily and mental activity; deficiency of this leads to cretinism in infants, slowness or idiocy in adults. Any enlargement of the organ is called a *goitre*, which may be associated with over- or under-production of the internal secretion.

The *parathyroid glands* are four pea-like bodies embedded in the lobes of the thyroid, an upper and a lower on each side. They are ductless glands controlling the utilization of calcium, and their overaction causes rarefaction of the skeleton and spontaneous fractures.

### Great vessels of the Neck.

We have seen that, on the right side, the innominate branch of the aorta divides at the level of the sternoclavicular joint into subclavian and common carotid arteries. Also that on the left side there is no innominate vessel, the subclavian and carotid arising directly from the arch of the aorta.

In the neck, the *common carotid* ascends on either side of the trachea and thyroid gland to the level of the upper border of the thyroid cartilage, where it divides into *internal* and *external* branches (Plates 10 and 11). It runs in the carotid sheath with the internal jugular vein lateral to it and overlapping it in front, and with the tenth cranial (*vagus*) nerve. Just before the bifurcation there is a dilatation, the *carotid sinus*, where the walls of the vessel are liberally innervated and very sensitive to changes in the blood pressure; this carotid sinus automatically maintains a reflex control of the circulation to

the brain. Apart from its terminal division, the common carotid has no branches.

The *internal carotid* continues its course to the base of the skull, enters the cranium and supplies the brain as well as the contents of the orbit.

The *external carotid* is mainly responsible for supplying the neck and the outside of face and head. It gives large branches to thyroid gland, larynx and tongue; gives off the facial artery as we have seen; and ends by running up behind the ramus of the mandible in the substance of the parotid gland to end as the superficial temporal artery to the scalp which can be felt pulsating in front of the ear. It also supplies the main artery to the upper and lower jaws.

The *internal jugular vein* corresponds to the common and internal portions of the carotid artery (Plate II). It leaves the base of the skull as a continuation of the venous sinuses of the brain through a special foramen, in company with the ninth, tenth, eleventh and twelfth cranial nerves, and runs down the neck lateral to the carotid artery, and more under cover of the sternomastoid. It ends by joining with the subclavian vein behind the sterno-clavicular joint to form the innominate vein, and this pattern is the same on both sides. There is no vein corresponding to the external carotid artery; but some veins from the face and scalp join to form the *external jugular vein* which we have met running superficially over the sternomastoid, and which ends by piercing the deep fascia above the clavicle to enter the subclavian vein. The latter arches in over the first rib on each side from the arm.

**The main nerves of the neck** fall into these groups :  
(i) *Cranial nerves*. The ninth (*glossopharyngeal*), tenth (*vagus*), eleventh (*accessory*) and twelfth (*hypoglossal*) pairs of cranial nerves enter the neck from within the cranium by traversing foramina in the base of the skull.

The first three of these travel in company with the internal jugular vein.

The *glossopharyngeal* is concerned with sensation and taste in the pharynx and back of the tongue, and pierces the side wall of the pharynx in its upper part to supply its mucous membrane.

The *vagus* runs down in the carotid sheath, between and behind the vein and artery, giving branches to pharynx and larynx; we have noted it within the chest and abdomen supplying the viscera, and its place in the autonomic system is referred to later on p. 269. An important branch to the intrinsic muscles of the larynx is known as the *recurrent laryngeal nerve*, for it hooks round the underside of the subclavian artery on the right to turn back and reach the larynx; the right recurrent laryngeal nerve is therefore entirely within the neck, but the left descends within the thorax to hook round the aortic arch before ascending again. Each recurrent nerve is intimately related to the back of the thyroid gland, and disease or injury here may result in permanent loss of voice.

The *accessory nerve* supplies the sternomastoid muscle and the trapezius; after leaving the first it runs down and back in the upper part of the posterior triangle to reach the anterior border of the trapezius.

The *hypoglossal nerve* supplies the muscles of the tongue and the floor of the mouth.

(ii) *Cervical spinal nerves.* The roots of the spinal nerves emerge in pairs between the vertebræ on each side. The upper roots form a small *cervical plexus* supplying various muscles. And the lower roots, C. 5, 6, 7, 8, together with the first thoracic root, form an important network, the *brachial plexus*, which lies in the lower part of the neck in the posterior triangle, and which gives rise to the main nerves of the arm. This plexus forms a bundle with the subclavian artery and



vein, the whole collection passing out over the upper surface of the first rib to reach the arm. Thus the plexus is partly in the neck above the clavicle, and partly in the axilla below the clavicle.

(iii) *Sympathetic chain.* In the neck the sympathetic chain consists of three *ganglia*, the *superior*, *middle* and *inferior*, with a connecting *sympathetic trunk*; these lie on the prevertebral muscles on each side, very deeply

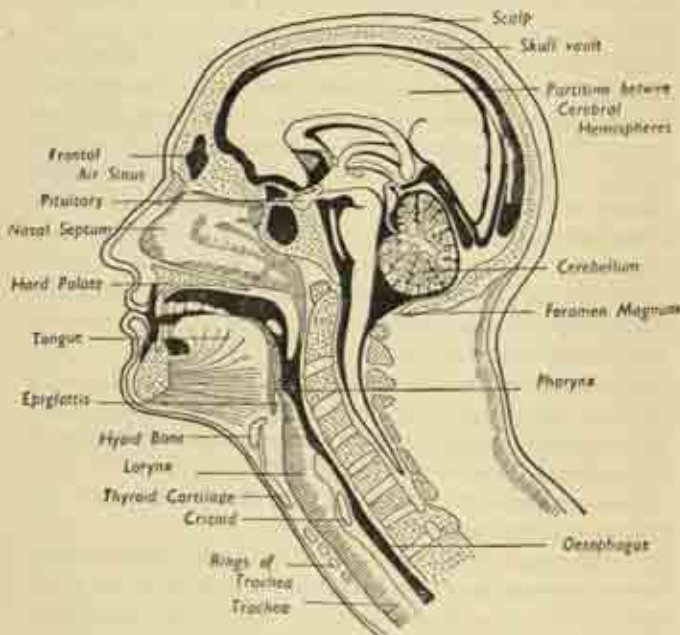


FIG. 131. Head and neck in longitudinal (sagittal) section.

behind the carotid sheath. And the trunk is continuous with the thoracic portion of the sympathetic chain through the thoracic inlet.

**Lymph glands of head and neck.** The main collecting

glands for the head and face are those associated with the ear—the pre- and post-auricular; those on the surface of the parotid and submaxillary salivary glands; the submental glands under the chin; the occipital glands at the skull base behind; and deep retropharyngeal glands lying between pharynx and vertebral column.

In the neck itself there are superficial and deep chains of glands and lymphatic vessels. Roughly, the superficial glands are grouped around the external jugular vein and accessory nerve, and occupy the posterior triangle; the deep glands surround the internal jugular vein and carotid vessels.

At the base of the neck, on the right side, a major lymphatic trunk is formed from all the vessels draining the right arm and the right side of head and face; this discharges into the angle of union of subclavian and internal jugular veins. On the left side, it will be recalled that the thoracic duct, which has collected all the lymph from both legs and from the abdominal and thoracic viscera, arrives in the posterior triangle. Here it adds to itself the vessels of the left arm, head and neck, and empties itself likewise into the corresponding venous angle. The thoracic duct is thus much larger and more important than the right lymph trunk, but even so it is often only just visible and even when distended is rarely thicker than a matchstick.



## CHAPTER X

### SPINAL COLUMN

THE spine is the central bony axis of the body and, to allow flexibility, is composed of numerous individual vertebrae in a segmental pattern. These articulate with each other, and the sum of the limited motion between the individual pairs is a considerable range. The column is traversed throughout by the central canal which encloses the spinal cord; and it supports the weight of the trunk and transmits it to the legs.

The vertebrae are grouped regionally as :

- 7 *cervical* (neck);
- 12 *thoracic* (chest);
- 5 *lumbar* (abdominal);
- 5 *sacral* (hip);
- and 4 *coccygeal* (tail).

Though modified considerably in the different regions, the essential features of a vertebra are the same everywhere (fig. 133). In front, a massive rounded *body* projects forward, with upper and lower surfaces facing those of the vertebrae above and below. Behind is the *neural arch* which, with the back of the body, forms a complete bony ring—the *neural canal* for the spinal cord. The arch is attached to the body by two pillars or *pedicles*; projecting at either side are the two *transverse processes*; and the *spinous process* sticks out backwards and downwards from the back of the ring to be felt under the skin of the back. In addition there is a pair of small *articular facets* on the upper surface of the arch and a pair below for articulation with adjacent vertebrae. The vertebral

body consists almost entirely of spongy bone, with a thin compact shell.

A pair of vertebrae so fit together as to leave on each side an *intervertebral foramen* for the exit of a spinal nerve; so that there are 34 pairs of spinal nerves all told, since the first cervical nerve emerges between the base of the skull and the uppermost cervical vertebra, while there is only one coccygeal nerve below.

The *cervical* vertebrae are delicate, with small bodies, as there is little weight bearing for them to do; and a very large neural canal, as the cord is thickest at its upper end before it has given off most of its roots. The transverse processes are pierced by a foramen transmitting a vessel, the vertebral artery, which runs up the neck from the subclavian and enters the foramen magnum to supply the hindbrain. The spinous process is short and bifid. The first cervical vertebra is the *atlas*, supporting the head. It is a simple bony ring without a body, and its upper surface articulates with the condyles of the occipital bone to form the joint at which the movement of nodding occurs. The second cervical vertebra is the *axis*; from its upper surface a peg-like process sticks up within the axis ring. Skull and atlas together rotate on this peg in sideways twisting of the head.

The *thoracic* vertebrae increase in size down the column. The bodies are heart-shaped seen from above, with facets at the sides for articulation with the heads of the ribs; a similar facet at each end of the transverse process articulates with the neck of the rib. The neural canal here is relatively small, the spinous process is long and projects well down.

The *lumbar* vertebrae are under considerable strain and are consequently of great size, with massive bodies. The neural canal is triangular, intermediate between the cervical and thoracic in size; and the blunt square spinous processes project almost horizontally backwards.

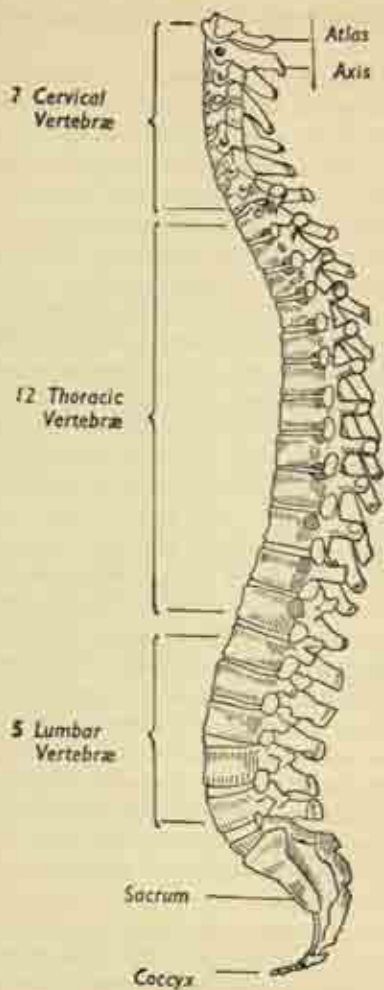


FIG. 132. The spinal column, lateral view.

The *sacral* vertebræ have become fused into one bone, the sacrum, intervening between the two innominate bones as the posterior segment of the pelvic ring; this fusion is essential as stability is so important here. It is a large flattened triangular bone with anterior (pelvic) and posterior (subcutaneous) surfaces. The base above articulates with the fifth lumbar vertebra at the lumbo-sacral joint, the apex below with the coccyx. It is placed obliquely so that its long axis is directed backwards as much as down; and the anterior surface is concave—the sacral hollow in which lies the rectum.

Though a single fused mass, the general features of the component vertebræ are still obvious, the bodies being marked off by transverse ridges. Four pairs of foramina transmit the sacral nerve roots; and the body of the bone is traversed by the sacral canal which, at this level, contains not the spinal cord (this has come to an end in the upper lumbar region) but a mass of nerve roots.

Above, the promontory of the sacrum is a prominent ridge of bone at the upper end of the anterior surface which forms the back of the pelvic brim. And on each side of this a spreading wing reaches out to form with the innominate bone the *sacro-iliac joint*, a large irregular interlocking pair of surfaces at which little motion occurs. The back of the sacrum is the lower origin of the sacrospinalis muscle which extends up beside the spine as far as the skull.

The *coccyx* is the rudimentary tail appendage of man, a small irregular mass of four fused vertebræ. It is triangular, angled forward at the sacro-coccygeal joint to parallel the anal canal, and is quite solid with no central channel.

### **The spinal column as a whole.**

The vertebral bodies are not in contact, but separated by thick cushions of fibro-cartilage, the *intervertebral*

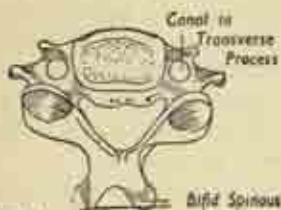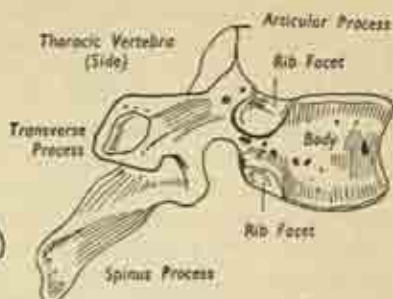
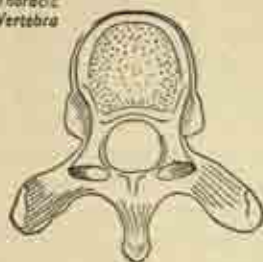
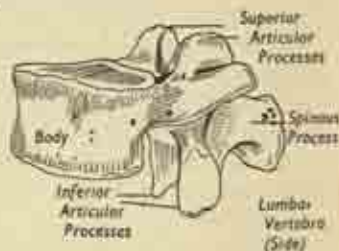
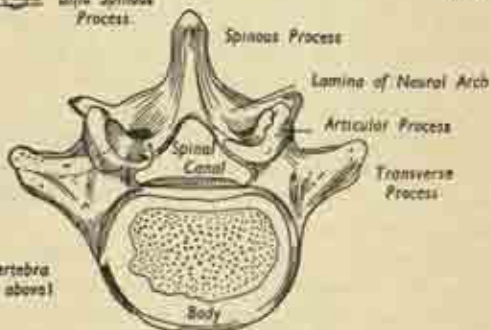
Thoracic  
VertebraCervical  
VertebraLumbar  
Vertebra  
(Side)Lumbar Vertebra  
(from above)

FIG. 133. Some typical vertebrae.

*discs*, which act as shock-absorbers. They increase in size down the column until in the lumbar region they are  $\frac{1}{2}$ -inch thick. Together the discs make up a fourth or fifth of the length of the column. Each consists of an



outer fibrous ring enclosing a marble-like gelatinous core under considerable tension; this is the pulpy *nucleus* which acts as a ball-bearing on which pivot a pair of

*Articulation with 5th Lumbar Vertebra*

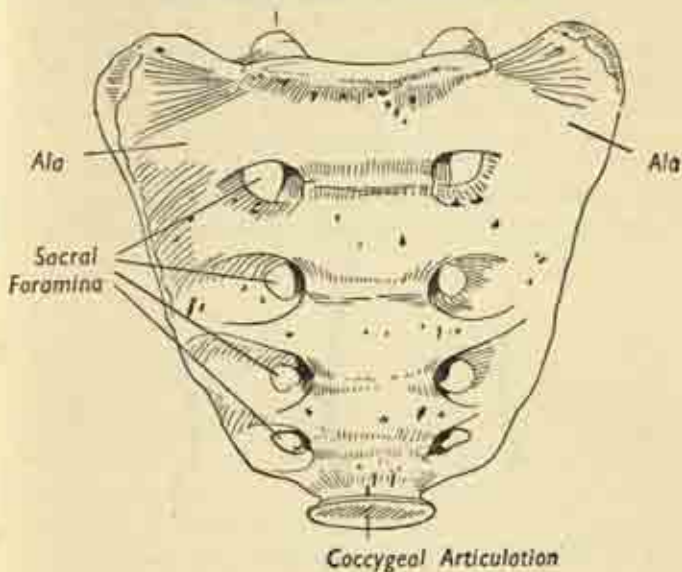


FIG. 134. The sacrum, pelvic aspect.

adjacent bodies. The intervertebral joint thus consists of the disc between the bodies plus the simple plane synovial joints between the pairs of articular processes on the arches. Long strap-like *ligaments* bind the bodies together, the anterior and posterior ligaments which traverse the length of the column on the front and back of the bodies; and shorter bands connect the spinous and transverse processes. The whole makes up a flexible rod which is one single entity.

Though the spine should be quite straight looked at

from in front or behind, there are in side view a series of normal curvatures alternating in direction from above down. The cervical and lumbar curves are forward convexities or *lordoses*; the thoracic and sacral curves are forward concavities or *kyphoses*. And this arrangement of successive arcs, spanned by the chords of the spinal muscles, is obviously sounder than a more rigid, straight column would be. The child's spine at birth does not

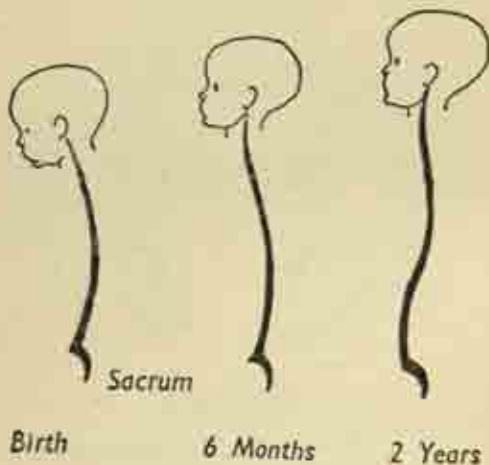


FIG. 135. Spinal curves at different ages.

possess the cervical and lumbar curves; there are only the anterior concavity of the whole spine (the crouched foetal position) and that of the sacrum, the two primary curves. As the head is held up in the first six months the cervical lordosis develops; and the lumbar curve results from sitting up and standing in the second year of life.

In the adult the vertebral bodies are somewhat wedge-shaped to conform to the shape of the curves—except in the lumbar region where the intervertebral discs are considerably thicker in front than behind.

*Spinal movements.* These are :

(i) *flexion*, forward bending, maximal in the cervical region, though also occurring to a considerable extent in the lumbar spine;

(ii) *extension*, backward bending, maximal in the lumbar region but also taking place in the neck;

(iii) *rotation*, a twisting of the column on the longitudinal axis traversing the nuclei of the discs, freest in the upper thoracic region and negligible elsewhere;

(iv) *sideways bending*, maximal in lumbar and cervical regions;

(v) *circumduction*, a swaying movement combining all the above, in which the trunk describes the surface of a cone, apex down.

## CHAPTER XI

### NERVOUS SYSTEM

THE brain and spinal cord, enclosed in the cranium and spinal canal, and continuous with each other at the foramen magnum in the skull base, make up the *central nervous system*. The 12 pairs of cranial nerves arising from the brain and the 31 pairs of spinal nerves arising from the cord constitute the *peripheral nervous system*. Together, the central and peripheral arrangements form the cerebrospinal or voluntary nervous system, which is mainly concerned with the control and sensation of the somatic structures of the body wall—skin, muscle, bones and joints—though many of its activities are far from conscious.

In contradistinction to this, the semi-independent *autonomic* or *vegetative nervous system* deals with the automatic functioning of the splanchnic structures—viscera, glands and vessels. Nevertheless, the two systems are closely interconnected as we shall see later.

### CEREBROSPINAL SYSTEM

#### Membranes, cerebrospinal fluid.

Brain and cord have three enveloping membranes, which are prolonged as sheaths along the nerve roots which pierce them on their way out. The outermost layer is the *dura mater*, a tough protective envelope, loosely applied, and not entering the interstices of the cord or following the convolutions of the brain; in the

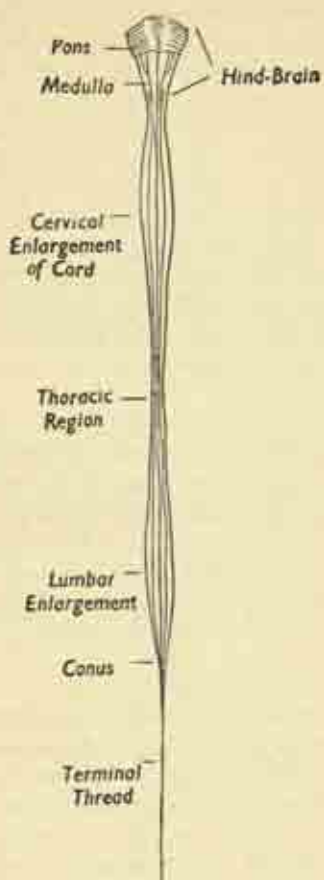


FIG. 136. Spinal cord and hind-brain. (After Grey).

cranium it also forms the inner lining periosteum of the skull bones. The innermost layer is the *pia mater*, a fine vascular membrane closely applied to the outer surfaces of brain and cord, entering and exactly following every cleft and crevice, and carrying in with it the fine blood vessels. Intermediate is the *arachnoid layer*; this fits closely inside the dura, but there is a considerable *sub-arachnoid space* separating it from the pia, a space filled with cerebrospinal fluid and traversed by spidery meshes of connective tissue (fig. 139).

The cerebral and spinal membranes are continuous with each other, the fluid freely bathing the outer surfaces of brain and cord. The fluid also occupies the hollow chambers or ventricles of the brain which communicate with the small central canal of the cord. It is formed as the secretion of the vascular *choroid plexus* lining the ventricles, circulates inside the brain and cord, escapes through the roof of the hindbrain to the outer subarachnoid space, and is finally reabsorbed into the blood stream via the venous sinuses of the cranium. Thus there is a continuous circulation of fluid from the blood-vessels in the ventricles, round the brain and cord, and back into the blood stream again.

### Spinal cord. (Figs. 136-140.)

The spinal cord is elongated and cylindrical with two fusiform swellings, the *cervical* and *lumbar enlargements*, which are the sites of origin of the roots of the brachial and lumbar nerve plexuses for upper and lower limbs.

In the foetus the cord occupies the whole length of the spinal canal. But it fails to keep pace with the growth of the spine, until in the adult it ends at the first lumbar vertebra in a tapering conical extremity. And since the nerve roots must still emerge at the correct levels from the pairs of intervertebral foramina, they have to run more and more obliquely downward and out as they arise



lower in the cord; so the spinal canal below the termination of the cord is filled with a mass of roots—the *cauda equina* or “horse’s tail”—descending almost vertically to their appropriate lumbar and sacral exits. This apparent

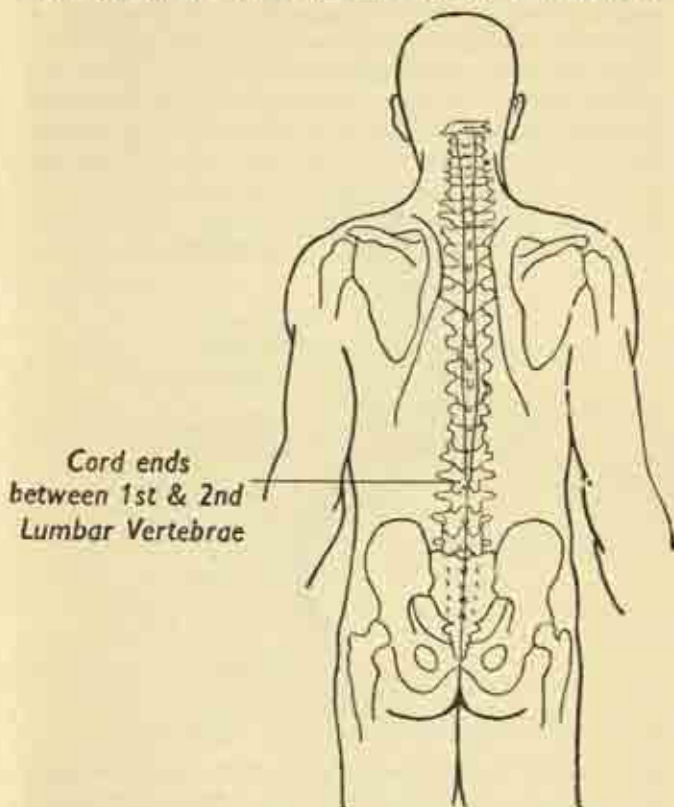


FIG. 137. Surface marking of the spinal cord. (After Gray).  
recession of the cord with growth is responsible for the lumbar enlargement being actually in the lower thoracic region.

Cross-section of the cord shows the inner H-shaped arrangement of *grey matter* composed mainly of nerve cells; and the surrounding white matter—descending and ascending tracts of nerve fibres. In the very centre is a minute canal. In the midline, a cleft anteriorly and a fissure posteriorly approach the centre of the cord, dividing it into symmetrical right and left halves. (Plate 12.)

On each side the grey matter projects in front and behind as the *anterior* and *posterior horns*. The *anterior horn* contains the motor nerve cells whose fibres are

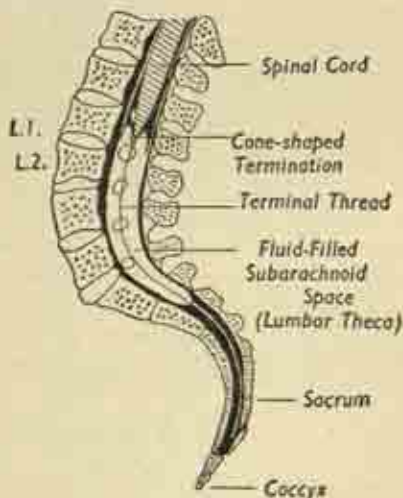


FIG. 138. The termination of the spinal cord in the upper lumbar region. (After Gray).

destined for the stimulation of muscles, and these leave the cord in a bundle as the anterior or motor nerve root.

The *posterior horn* contains sensory cells; fibres enter it from the posterior or sensory nerve root and are mediated by a group of cells forming a knob or ganglion on this root just outside the cord.

### Spinal nerves.

The two roots on each side join just beyond the ganglion to form the spinal nerve proper, the junction lying just within the intervertebral foramen before the nerve leaves the spine. Thus the spinal nerve contains mixed sensory and motor fibres which are not separated out again until, in the later distribution of the nerve and its branches in limb or trunk, specific motor and sensory twigs are given off to particular muscles and areas of skin.

The peripheral nerves follow the simplest pattern in the thoracic region, the spinal nerve on each side encircling the chest in its appropriate intercostal space

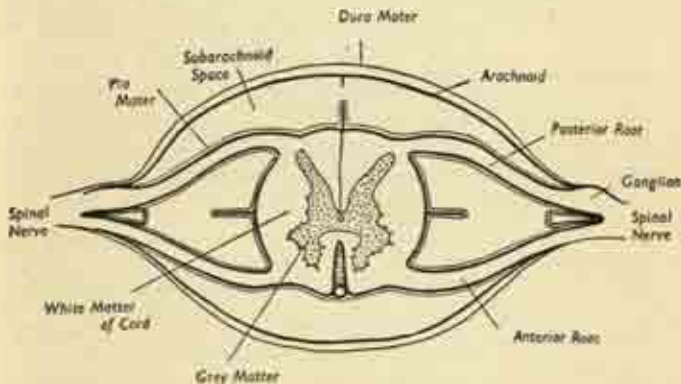


FIG. 139. Cross-section of the spinal cord and its membranes.  
(After Gray).

without connection with its neighbour above and below. But, as we have seen, the lower cervical and the lumbar and sacral nerves form complex networks as soon as they have left the spinal column. From these brachial and lumbosacral plexuses emerge the actual peripheral nerves of the limbs, e.g., median and ulnar in the arm, sciatic and femoral in the leg; and these are usually

mixed motor and sensory nerves, though some are almost entirely one or the other, e.g., the radial in the arm is mainly motor to the extensor muscles.

**The Reflex Arc.** It is obvious that the spinal cord provides a relatively simple means for the performance of certain primitive and essential actions without the intervention of the brain. Thus an irritation of the skin sends

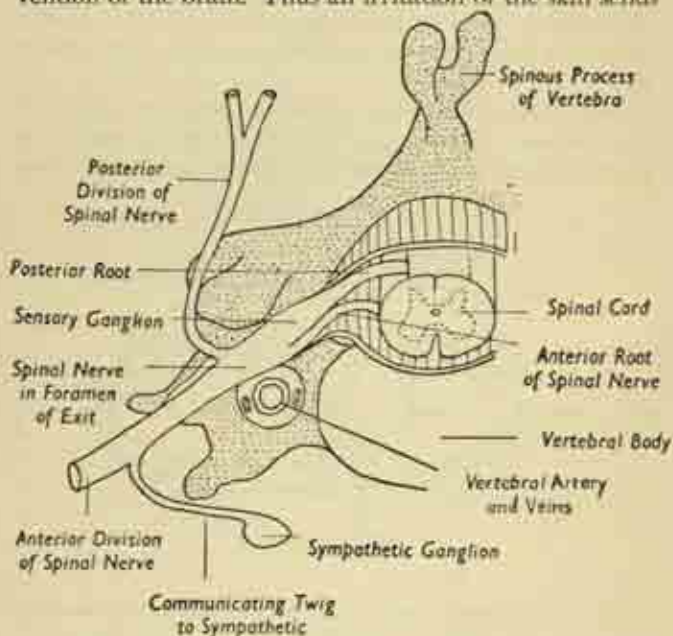


FIG. 140. Cross-section showing the spinal cord, its issuing roots, and the appropriate spinal nerve, as they lie in relation to the bony spine. The section is in the cervical region. Note the communicating twig to the sympathetic ganglion. (After Gray).

a sensory impulse through the posterior root to the posterior horn; this is transmitted or relayed to the anterior horn cells of the same segment of the cord, and

becomes a motor impulse travelling out through the anterior horn to activate muscles which remove the affected part from the noxious agent. This is the *reflex arc* at its simplest in the withdrawal reflex, the only pattern of nervous action in lower animals; and it is independent of the brain, though the brain is aware of its results and can to some extent modify them.

On a more complex level, but basically similar, are the reflexes of micturition, defaecation, sexual orgasm, child-birth, all controlled by a particular segment or group of segments of the cord. All these actions are possible even when the cord-brain link is completely severed by injury, so that the body is completely paralyzed as far as conscious sensation and volition are concerned.

**The Tracts of the Cord.** The grey matter is composed mainly of cells, with short fibre-connexions at the same transverse level. The white matter is made up of fibres running longitudinally in the cord in cable fashion, and these are grouped in a constant pattern of individual tracts, some of which are sensory and some motor. A few tracts run the length of several cord segments only; but most run from cord to brain and link the anterior or posterior horn cells with the appropriate controlling or receptive centres of the brain. Thus, from that part of the motor area of the cerebral cortex concerned with arm movement fibres run to the anterior horn cells of the seventh cervical segment of the cord; and from these cells fibres leave to take part in the brachial plexus, enter the median nerve, and actuate the flexors of the wrist. Again, sensory impulses from the knee travel up in the femoral nerve, through the lumbar plexus, to the posterior horn cells of the fourth lumbar segment of the cord, and are then relayed up the long sensory tracts of the latter to the sensory portion of the cerebral cortex.

In other cases other parts of the brain are the termini—cerebellum or midbrain—but an invariable principle is



that of crossing or decussation; at some point, usually in the brain stem, the fibre tracts cross completely from one side to the other so that the sensory and motor regions of the brain control the opposite halves of the body. The relays in this system, which are situated where the long fibres meet the anterior and posterior horn cells, are known as *synapses*. Here each long fibre (which is the axon of a brain cell) ends by arborizing round the small processes or dendrites of a cord cell. There is no anatomical continuity, but the passage of electrical impulses is free. Some of the more important tracts of the cord are shown in Plate 12.

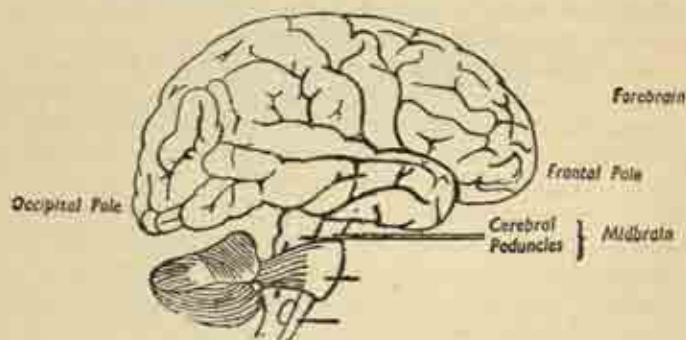


FIG. 141. The brain in side view. Diagrammatic. (After Gray).

### The Brain.

The brain is the greatly expanded and elaborated upper end of the cerebrospinal nervous axis. It has the same enveloping membranes as the cord; it almost entirely fills the cranial cavity; and it makes indentations on the inner aspect of the cranial bones. The arrangement of grey and white matter is the reverse of that in the cord, for the grey matter is now on the surface and the white fibre tracts within. The main portions of the brain are, from above down, as follows:—



The *Forebrain* is the great overhanging pair of *cerebral hemispheres*, the bulk of the organ, symmetrical rounded masses of convoluted nervous tissue which completely hide the lower parts of the brain when viewed from above.

The two hemispheres are separated by a deep median fissure which contains a partition of the dura mater; but are connected at the base of this cleft by a great bridge of fibres from side to side. The superficial grey matter, the cerebral cortex, has an enormous area owing to the intricate pattern of convolutions. This produces a number of elevated ridges or *gyri* separated by narrow valleys or *sulci*; and the increasing complexity of this pattern in evolution through the vertebrates to Man is a measure of the increase in intelligence and consciousness.

Each hemisphere is composed of several *lobes* which are not clearly demarcated from each other. In side view, the *frontal lobe* is seen at the anterior end of the hemisphere, occupying the anterior cranial fossa, its tip the anterior pole of the brain. Behind is the *occipital lobe* lying in the posterior cranial fossa, its tip the posterior pole. The *temporal lobe* lies immediately behind the frontal and projects below, occupying the middle cranial fossa; and the *parietal lobe* is an ill-defined area squeezed in between frontal and occipital regions above the temporal lobe.

Plate 12 shows the areas of localization of function in the cerebral cortex, those known to control movement or to act as the main reception centres for sensation. The main motor and sensory areas are placed midway between the poles, and the body is represented in these areas in inverted fashion, i.e., the areas for the legs are uppermost, those for the head below. There is a vaguely localized centre for the appreciation of the meaning of words in the temporal lobe of the left side, concerned with the correlation of the meanings of spoken, written, read and heard words; but this is situated on the right

side in left-handed people. All these functional areas are concerned with the opposite half of the body; though the visual area of the occipital cortex is concerned, not so much with the opposite eye, as with the gathering up all the visual impulses from the opposite field of vision which have entered both eyes. It will be seen that a considerable area of cortex is assigned no particular function. These are the *psychic* or *association* areas, concerned with the correlation of sensory and motor data and with

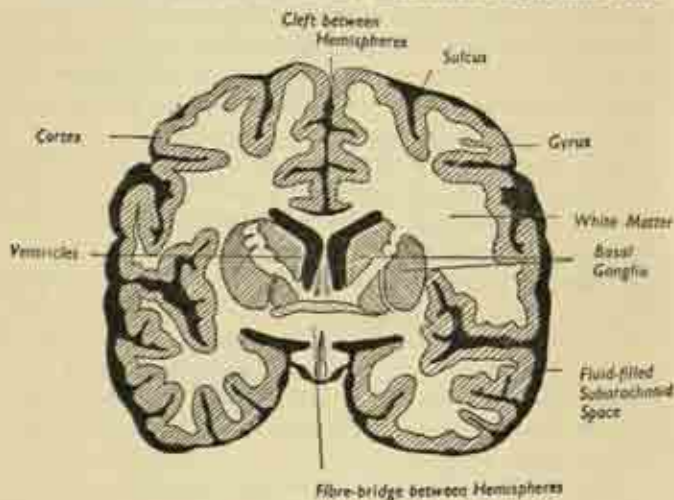


FIG. 142. The forebrain in cross-section.

the higher level of consciousness and personality, particularly in the frontal lobes. The latter may be destroyed or removed without interfering with essential activities, though with considerable changes in mood and capacity for self-appraisal.

Cross-section of the forebrain shows the surface pattern of sulci and gyri, the contrast of grey and white matter, and the cleft between the hemispheres. It shows on each

side the hollow chamber or *ventricle* in the depths of the hemisphere, filled with cerebrospinal fluid, and great masses of grey matter on each side of the ventricles, the *basal ganglia*, one of which—the *thalamus*—is intimately connected with the emotions.

The *Midbrain* is deeply situated at the base of the hemispheres, and partly consists of a squat cerebral *peduncle* on each side, a pillar supporting the corresponding hemisphere and carrying fibres to and from it. The roof of the midbrain contains the important nuclei of the third cranial nerve, which controls the movements of the eyeballs.

The *pituitary body*, an important endocrine gland, projects from the undersurface of the brain just in front of the peduncles.

The *Hindbrain* is best seen on the underside of the organ (figs. 131, 136, 141, 143). It includes:

(i) the *medulla oblongata*, the bulbous expansion formed by the upward prolongation of the spinal cord, the lowest part of the brain, containing the nerve centres which control heart-beat and respiration;

(ii) the *cerebellum*, a pair of rounded hemispheres, finely convoluted, occupying the deepest part of the posterior cranial fossa;

(iii) the *pons*, a broad bridge of fibres connecting the cerebellar hemispheres.

Each cerebellar hemisphere is concerned with the opposite side of the body, automatically regulating muscle tone and posture in virtue of the changing sensory impulses of position and tension it receives from joints, tendons, and the semi-circular canals of the internal ear. It is concerned, that is to say, with the essential postural mechanisms of the head and trunk, the automatic righting reflexes which restore the upward carriage of the head after any upsetting of balance.

### Fibre Tracts of Brain and Cord.

The brain may be regarded as a series of cell-stations situated at higher and lower levels in the grey matter of the cerebral cortex, basal ganglia, midbrain, medulla and cerebellum. To and from these, great tracts of nerve

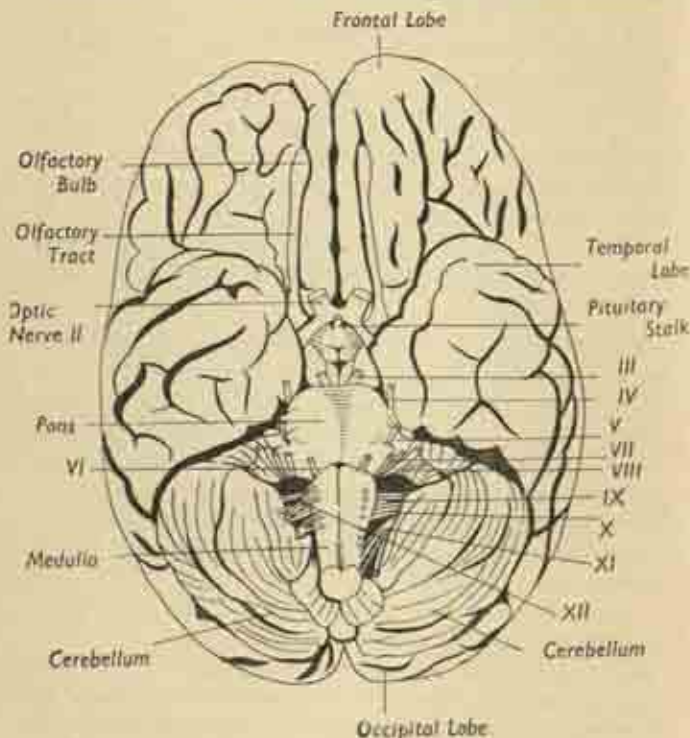


FIG. 143. The underside of the brain, showing the attachments of the twelve pairs of cranial nerves.

fibres ascend and descend within the central white matter of the brain stem, the axial conducting core of medulla and midbrain. These tracts have already been

encountered in the cross-section of the spinal cord, and may be classified as motor (descending) and sensory (ascending); at some level, usually in the hindbrain, these fibres all cross to the opposite side, so that functional areas of the brain represent the other half of the body. The principal tracts are as follows (Plate 12):

### Motor Tracts.

(i) *Pyramidal*, running from the cerebral motor cortex to the anterior horn cells of the cord at all levels, thence relayed to the motor roots. Concerned with voluntary motion.

(ii) *Cerebello-spinal*, running from the cerebellum to the anterior horn cells, concerned with the automatic regulation of tone and posture.

### Sensory Tracts.

(i) The posterior bundles of the cord carrying touch and sensation to the cerebral sensory cortex.

(ii) The anterior and lateral bundles of the cord, carrying pain and temperature sensation to the sensory cortex.

(iii) The spino-cerebellar bundle carrying postural sensation to the cerebellum.

All the sensory bundles are relaying impulses entering the cord via the posterior sensory roots and the posterior horn cells. Since the sensory tracts acquire an increasing influx from higher roots as they ascend, and since the motor tracts shrink as they descend because they shed fibres to successive segments of the cord, the bulk of the cord as a whole tapers from above downwards.

*The Ventricles.* We have seen that the brain is hollow, traversed by channels for the cerebrospinal fluid. Within each cerebral hemisphere is a large *lateral ventricle*, and between and below these is a small *third ventricle* from the floor of which the pituitary body is slung. These communicate and lead on to a tiny channel, the *aqueduct*,



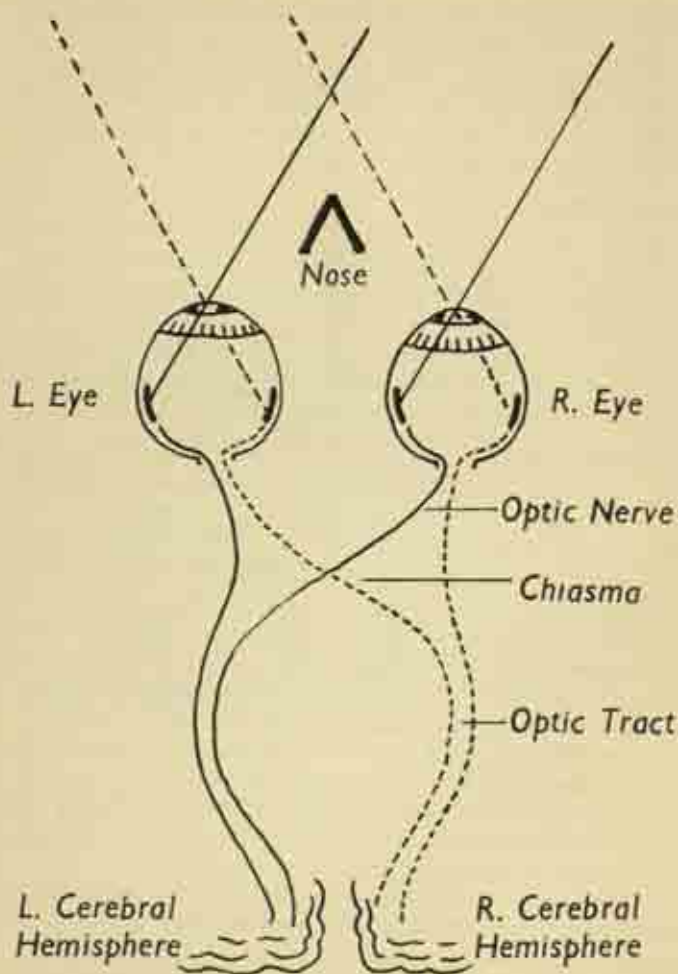


FIG. 144. The visual pathways from eye to brain.



which leads backwards through the midbrain to expand as the *fourth ventricle* of the medulla. This is continuous with the central canal of the spinal cord; and from its roof, under cover of the cerebellum, the fluid escapes through three little apertures to bathe the outer surface of the brain and cord in the subarachnoid space. Growing from the smooth linings of the lateral and fourth ventricles is the highly vascular *choroid plexus* which secretes the fluid; any block to its free flow within the ventricles, or at its exit from the hindbrain, results in a damming-up within the brain, which is slowly ballooned out to produce the condition known as *hydrocephalus* or "water on the brain".

### Vessels and Nerves of the Brain.

The main *arterial* supply of the brain is derived from the two internal carotids, which enter the skull base. They form, with the vertebral arteries which have entered the foramen magnum, a vascular circle around the stalk of the pituitary body. From this circle, *anterior*, *middle* and *posterior cerebral arteries* are given off to the frontal, parieto-temporal, and occipital parts of the brain respectively. The hindbrain is supplied directly by the *vertebral artery*.

The main *veins* are grouped as venous sinuses which run between the layers of the dura mater and eventually drain to the internal jugular; the *superior sagittal sinus* of the vault, which runs the whole length of the brain from front to back between the hemispheres, also drains off the cerebrospinal fluid, which is thus reabsorbed as constantly as it is formed.

The brain substance itself is not supplied with nerves and is quite insensitive; it can be handled and cut at operation without reaction, even in the conscious patient. But its covering membranes are extremely sensitive, particularly to distension, which causes severe headache.

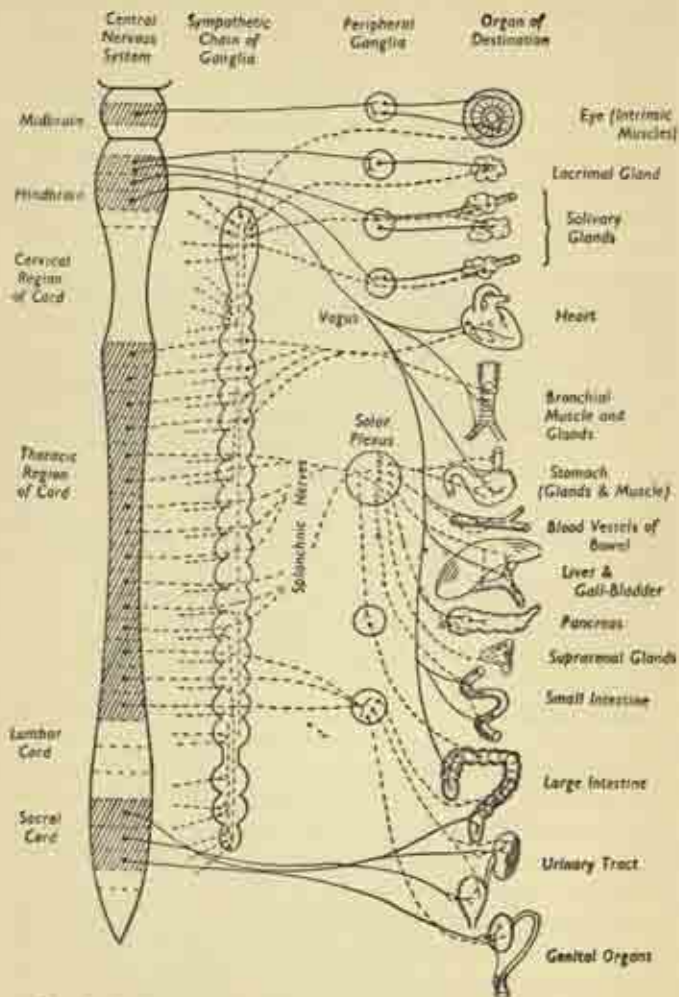


FIG. 145. Plan of the autonomic nervous system. (After Gray).

**Cranial Nerves.** (Fig. 143.)

In certain parts of the brain aggregations of nerve cells from the nuclei from which arise the twelve pairs of cranial nerves, best seen on the underside of the organ. These are mainly concerned with sensation and movement in the head and face, including the eye and ear; but one (the eleventh) controls certain neck muscles, and another (the tenth) is widely distributed to the thoracic and abdominal viscera. They may be described from above downwards, corresponding to the different levels of the brain at which they arise.

I. The first or *olfactory* nerves are those of smell. On each side a group of some 20 rootlets ascends from the nasal mucous membrane, through the perforations in the floor of the anterior cranial fossa, and ends in the olfactory bulb on the undersurface of the frontal lobe. From this the long olfactory stalk relays the impulses to the cerebral hemisphere. It should be noted that the sense of smell is responsible for a good deal of what is normally regarded as taste, as witnessed by the effect of a severe cold on the appreciation of food. These nerves are purely sensory.

II. The second or *optic* nerve is concerned with sight. Each carries fibres from the nerve cells of the retina and leaves the back of the orbital cavity through the optic foramen to enter the middle cranial fossa. The two nerves from an X-shaped crossing or *chiasma* on the underside of the frontal lobes, just in front of the pituitary stalk, the hind limbs of the X being the *optic tracts*. The effect of this crossing is that fibres from the outer half of each retina remain in the optic tract of the same side, while those from the inner halves cross over into the opposite tract. This means that the right tract carries all the fibres from the right halves of both retinae, and therefore all the sensation from the whole of the left half of the visual field; and *vice versa* for the left tract. This separating

out is essential to maintain the principle of one-sided representation of function in each half of the brain. For though each eye is a one-sided organ it sees on both sides of the body, and what is needed for efficient co-ordination is that the whole of one side of the *visual field* should be represented as such in the cerebral cortex. The impulses are relayed to the visual area of the occipital cortex, and there is an intimate connexion with the nucleus of the third nerve which controls eye movements. The optic nerve is purely sensory.

III. The third or *oculomotor* nerve controls four of the six small muscles moving the eyeball. It is purely motor.

IV. The fourth or *trochlear* nerve controls another of the ocular muscles. It is purely motor.

V. The fifth or *trigeminal* nerve has a large sensory root carrying a ganglion; this root is divided into three branches:

(i) *ophthalmic*; this conveys sensation from within the orbit other than sight, i.e., ocular pain, and sensation from the forehead and front of the scalp;

(ii) *maxillary*; this conveys sensation from the upper jaw and teeth and overlying facial skin;

(iii) *mandibular*; this conveys sensation from the lower jaw and teeth and overlying skin, and ordinary sensation (but not taste) from the front of the tongue and mouth.

The mandibular division passes down to enter a canal traversing the lower jaw. The ophthalmic division enters the back of the orbit. The maxillary division runs in a canal sandwiched between the orbital floor and the roof of the maxilla to emerge on the front of the cheek.

The fifth nerve also has a small *motor root*, concerned with the muscles of mastication, which leaves the skull with the mandibular division. Thus it will be seen that the fifth nerve is a mixed sensory and motor nerve.



VI. The sixth or *pathetic* nerve controls the last of the ocular muscles. It is purely motor.

VII. The seventh or *facial* nerve is mainly concerned with the facial muscles, though it also activates the secretion of some of the salivary glands, and conveys taste sensation from the front of the tongue. It leaves the posterior fossa of the skull by entering the internal auditory meatus on the inner aspect of the temporal bone in company with the eighth nerve. After a winding course within the temporal bone it emerges outside the skull, immediately in front of the mastoid process, and enters the substance of the parotid gland, in which it divides into several twigs supplying the various groups of facial muscles—scalp and eyelids : cheek, nose and mouth : and the platysma in the neck. It is a mixed sensory and motor nerve.

VIII. The eighth or *auditory* nerve connects the inner ear, deep in the substance of the temporal bone, with the hindbrain; it is really double, serving two distinct functions :

(i) The *acoustic portion*, which carries sensations of sound and pitch from the true organ of hearing, the cochlea; these sensations are relayed to the auditory part of the cerebral cortex.

(ii) The *vestibular portion*, which carries postural sensation from the semi-circular canals of the internal ear, the organ of balance, to the cerebellum. It provides constant information as to the changes of position, to aid in maintenance of the erect position.

IX. The ninth or *glosso-pharyngeal* nerve is almost entirely sensory, though it also activates parotid secretion and some little muscles associated with the pharynx. It conveys sensation from the pharynx, tonsil, and back of tongue, including taste.

X. The tenth nerve, the *vagus*, is very important and complex, extending through the neck and thorax to the

abdomen. It is an essential component of the autonomic system controlling the viscera, as we shall see later. Its anatomical course in neck and chest has been referred to previously. Its main branches are :

(i) In the *neck*, for movements of the pharyngeal and laryngeal muscles, sensation of the linings of pharynx and larynx;

(i) In the *chest*, it forms the cardiac plexus controlling heart action; the pulmonary plexuses at the roots of the lungs; and it also supplies the muscle of the oesophagus and bronchi, and their associated glands, and carries sensation from their mucous linings;

(iii) In the *abdomen*, it supplies the muscle, glands and mucous membranes of the stomach and duodenum, and sends twigs to the liver, spleen and kidneys.

XI. The eleventh or *accessory* nerve is purely motor, and supplies the muscle of soft palate and pharynx, and the sternomastoid and trapezius.

The ninth, tenth and eleventh nerves all arise from the medulla, and leave the skull base through the jugular foramen with the internal jugular vein.

XII. The twelfth or *hypoglossal* nerve controls the muscle of the tongue and floor of the mouth.

One point, common to both spinal and cranial nerves, must be made here. The fibres of motor cranial nerves, or the motor portions of mixed cranial nerves, and those of the motor roots of the cord, arise from their cells in the cerebral nuclei or anterior horns and pass out without a break to their destined muscles. But sensory fibres, passing in from the skin or other sensory surface, end at a group of cells situated outside the brain or cord; these cells make up the *ganglia*, knobby swellings on the posterior spinal roots, or on the sensory cranial nerves as they lie on the skull base. It is invariable that all sensory nerves have such a ganglion; and it is the axons of the



ganglion cells and not the original sensory fibres which ultimately enter the cerebrospinal axis. In other words, motor impulses are direct, sensory impulses are mediated. The outgoing motor pathways are known as efferent, the incoming sensory fibres are afferent.

## AUTONOMIC NERVOUS SYSTEM

### **Sympathetic and parasympathetic.** (Fig. 145.)

The autonomic nervous system is distributed to the viscera—the hollow internal organs—and to the blood-vessels. It controls their smooth musculature and the secretory activity of their associated glands. Because all its nerve fibres are ultimately derived as an outflow from the cerebrospinal axis itself, it is analogous to a Local Authority in more or less complete charge of sewage and transport arrangements, but only in virtue of powers delegated to it by Government itself. And these arrangements are susceptible to indirect modification by that Government, not through an act of will but through emotion which intimately affects visceral activity.

The system contains two complementary parts, the *sympathetic* and *parasympathetic*, which are anatomically and functionally different. Both supply the viscera and vessels, but their influence is mutually antagonistic. Each acts by liberating at its nerve endings in the organs specific chemical substances—*adrenaline* in the case of the sympathetic, *acetylcholine* in the parasympathetic. And the actions of these substances are mutually antagonistic.

The effects of the sympathetic are those of great bodily activity and preparation in relation to the primitive reactions of fear and flight. It constricts the skin vessels, so raising the blood pressure and shunting more blood to heart and brain; speeds the heart beat; dries up glandular

secretion; and relaxes the walls of the hollow organs, allowing them to fill.

In contrast, the parasympathetic deals with more constructive building-up activities in times of tranquillity. It dilates the peripheral vessels, lowers the blood pressure and decelerates the heart; excites secretion; and empties the hollow organs by relaxing their sphincters and contracting their walls.

Nevertheless, this generalization of their actions is an over-simplification. The two parts of the system are in complex and reciprocal control of the internal organs, though one or other may dominate in markedly anxious or placid individuals. To pursue our analogy, we may imagine a Local Authority employing builders who both make new houses and knock down old ones, but whose activities overlap at many points and require constant co-operation.

#### *Anatomical Arrangements.*

The *sympathetic* system is a chain of ganglia on each side, running the whole length of the spinal column from atlas to coccyx, where the two meet and fuse in a single ganglion. We have met this chain lying on the sides of the vertebræ at the back of the abdominal and thoracic cavities, where there is one ganglion to each segment and spinal nerve; and in the neck, where there are only three. The outflow from the central nervous system to the sympathetic is by a little communicating twig from each spinal nerve in the thoracic and upper lumbar region to the corresponding sympathetic ganglion (fig. 140). From this ganglion the peripheral sympathetic distribution is effected in two ways:

- (i) by a returning twig to each spinal nerve, the fibres travelling out in it to the somatic structures;
- (ii) by the formation of plexuses, branches of which form a network around the vessels travelling to the

viscera, e.g., the cardiac and pulmonary plexuses of the chest, the splanchnic nerves running down from the thoracic chain through the diaphragm to the solar plexus and thence to the bowel.

The *parasympathetic* system is less obviously distinct, for its fibres are merely contained in certain cranial and sacral nerves at either end of the cerebrospinal axis. The former supply the glands and vessels of the head, the latter the bladder, rectum and genital organs. But the tenth cranial nerve—the *vagus*—is the great parasympathetic nerve of the body, traversing neck, chest and abdomen to supply the viscera.

The ultimate sympathetic and parasympathetic twigs to the individual organs are often distributed in common, and are always interrupted by a relay at a peripheral ganglion before reaching their destination.

## SPECIAL SENSE ORGANS

### The Eye.

The globe of the eye lies embedded in the orbital fat, embraced by the six small *ocular muscles* which spring from the bony walls of the orbital cavity and move the eyeball in all directions. It is a sphere almost an inch in all diameters, with a more local convex bulge at the anterior pole formed by the transparent window of the *cornea*. The *optic* nerve is attached behind and runs back in the orbit like a stalk to reach the cranial cavity via the optic foramen.

The eyeball has three coats :

(i) an outer fibrous coat, the tough opaque protective *sclera*, the white of the eye which surrounds the whole globe except where it merges into the cornea anteriorly;

(ii) an intermediate pigmented layer, the *choroid*, which lines the sclera and is modified in front to form

the diaphragm of the *iris*. This rests on the lens and has the central aperture of the *pupil*, the size of which is varied by the contraction of the underlying muscular *ciliary body*;

(iii) the innermost nervous layer is the *retina*, adapted for the reception of light stimuli, and extending forward no further than the ciliary body. It is pigmented, containing the visual purple which is bleached by exposure to strong light, and consists of a very complex layered pattern of nerve cells whose fibres ultimately leave the eye in the common bundle

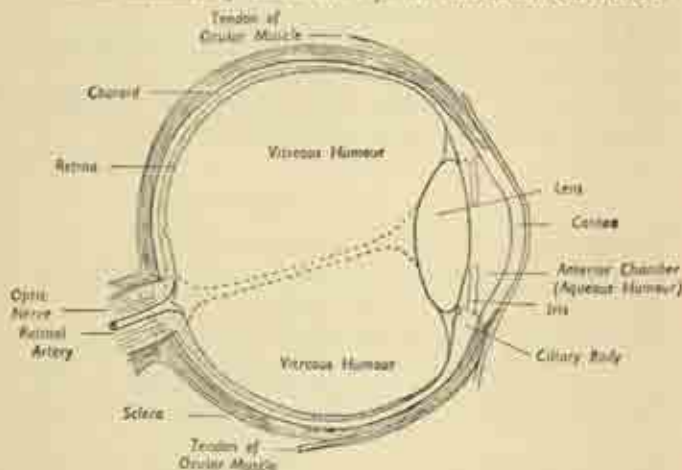


FIG. 146. Section through the globe of the eye.

of the optic nerve. The point of attachment of the latter to the retina is the *optic disc* or blind spot, as here there is no room for visual reception; and it is here that the central retinal artery and vein enter the eye by traversing the centre of the optic nerve.

The refracting media of the eye are also three in number :

(i) the watery *aqueous humour* fills the anterior chamber, the space between the cornea and the front of the iris and lens; and also pervades the little posterior chamber, the narrow marginal cleft between lens and back of iris. Like the cerebrospinal fluid, the aqueous is being constantly secreted from the circulation and reabsorbed, and any interference with the latter may cause a dangerous rise of ocular tension—glaucoma.

(ii) the translucent *lens* is a solid structure enclosed in a capsule, and markedly more convex on its posterior than its anterior aspect; and this curvature is modified by changes in the tension of its suspensory ligament to accommodate for near and far vision.

(iii) the great bulk of the eye is filled with the thin translucent jelly of the *vitreous humour*, traversed by a central canal running from the entrance of the optic nerve to the back of the lens.

#### *Eyelids and Lacrimal Apparatus.*

The supporting substance of each lid is the tarsal plate, a layer of dense connective tissue; the eyelashes are attached at the lid-margins, and the inner surfaces are lined by a delicate membrane, the *conjunctiva*, which is reflected over the cornea and sclera in front. This is kept moist by the secretion of tears by the *lacrimal gland*, which is situated in the upper and outer part of the orbital cavity and has several ducts opening under the upper lids. The secretion is collected in the *lacrimal sac* at the inner angle of the lids, and from this the *naso-lacrimal duct* runs down the sidewall of the nasal cavity to discharge the tears into the nose.

#### **The Ear.**

The ear falls naturally into three parts: the *external ear*, the *middle ear* or *tympenic cavity*, and the *internal ear* or *labyrinth*.



The *external ear* consists of the *pinna*, the funnel-shaped organ for the collection of sound waves, a thin plate of elastic fibrocartilage covered with skin; this leads inwards to the middle ear along a narrow canal, the *external auditory meatus*. This is a channel an inch long with walls which are cartilaginous at the surface but bony as they approach the skull, and lined by intumed skin possessing wax-secreting glands. Thus the external ear is mostly outside the skull, while the middle and inner compartments are situated actually within the temporal bone. At the bottom of the external meatus, the tense circular *tympanic membrane*—the eardrum—completely

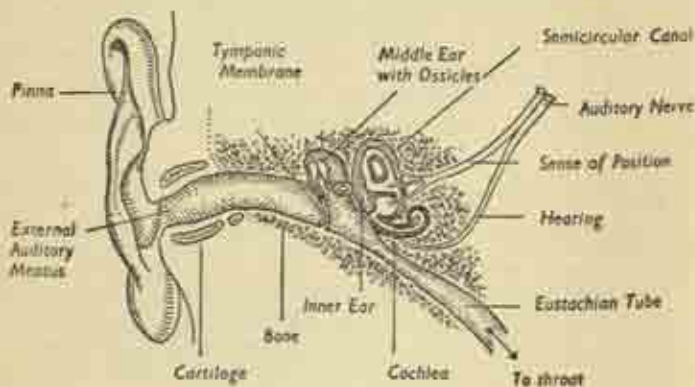


FIG. 147. The Ear.

shuts off the middle ear cavity, except when previous disease has left a perforation.

The *middle ear* itself is a roughly cuboidal cavity. Its roof is the floor of the middle cranial fossa of the skull; the eardrum is its outer wall; and the bony case of the inner ear lies medially. And a canal, the *Eustachian tube*, connects it with the naso-pharynx, providing a route for ascending infection and also a means for the regulation of air-pressure in the chamber. The

cavity is spanned by three tiny bones, the *auditory ossicles*, which link the tympanic membrane with the outer wall of the inner ear, transmitting by bone-conduction the vibrations which are set up by the sound impulses in the resonant eardrum.

The *internal ear*, deep within the temporal bone, is a complex organ, the *membranous labyrinth*, which is housed in an exactly-fitting bony chamber. One part is

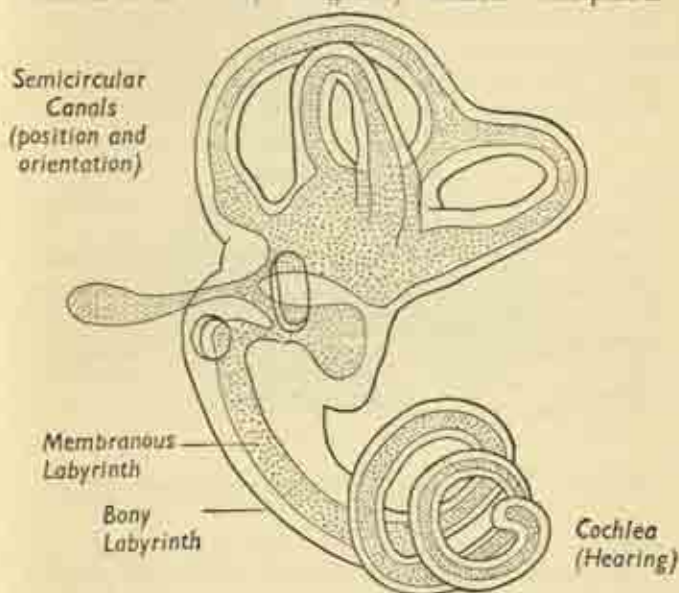


FIG. 148. Internal Ear.

concerned only with the sense of position and orientation in space. This consists of three fluid-filled *semicircular canals* arranged in three different planes mutually at right angles. Postural changes cause movement of the contained fluid, exciting the hair-tipped cells lining the canals, and these impulses are transmitted

in the vestibular portion of the eighth nerve. The other part is the *cochlea*, the true organ of hearing, a spirally-coiled structure responding to pitch and transmitting it via the acoustic portion of the eighth nerve.

Two little windows lie between the inner and middle ears, but these are closed by membrane and by one of the ossicles. On the inner cranial side an *internal auditory meatus* allows the passage of the seventh and eighth cranial nerves into the temporal bone from the brain.

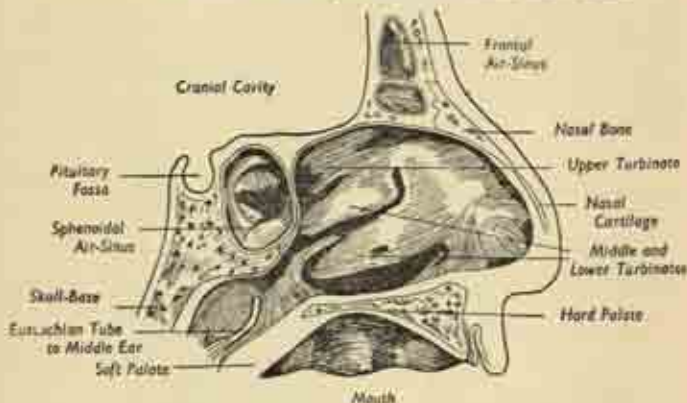


FIG. 149. The nose. The septum has been removed, and we are looking at the side wall of the left nasal cavity. (After Gray).

### Nose.

We have seen that the external part of the nose is partly bony at its base, where it is part of the skull; while the tip and much of the body is fibrocartilaginous. The nasal cavity itself is divided into right and left halves by the nasal septum, cartilaginous in front and bony in the depths. The two cavities open externally on the face at the nostrils or *anterior nares*, and behind into the nasopharynx at the *posterior nares*. The side wall of each cavity is marked by three ridges, the superior, middle

and inferior *conchæ*, the substance of each of which is a fragile scrolled *turbinate bone*; and beneath each overlying turbinate is a corresponding recess or *meatus*. The accessory nasal air sinuses open more or less directly into one or other meatus, the maxillary antrum straight into the middle meatus, the frontal sinus by a more tortuous channel. And the lining nasal mucous membrane is therefore freely continuous with that of the sinuses, which may be secondarily involved by a nasal infection. The actual smell-sensitive region is on the roof of each cavity, where the mucosa contains the olfactory cells whose fibres make up the first cranial nerve; the remainder of the cavity is purely respiratory in function.

*The Taste Organs* are certain modified epithelial cells, the taste buds, found mainly on the dorsum and sides of the tongue, and particularly numerous over its posterior third. They are also found on the soft palate and epiglottis. Their impulses are collected up in the seventh and ninth cranial nerves.

## CHAPTER XII

### ENDOCRINE GLANDS

Most of the glands of the body are organs of external secretion. An obvious duct carries their secretion into a body cavity (salivary glands to mouth) or hollow organ (pancreas to duodenum) or on to the skin surface (sebaceous glands). The endocrine glands have no ducts. Their internal secretions or *hormones* are absorbed into the blood-stream and diffused throughout the body, over whose functions they exercise an intimate and delicately sensitive control. They include the pituitary, thyroid, parathyroids, suprarenals, pancreas, ovaries and testicles. Some organs are capable at one and the same time of both internal and external secretion; the pancreas secretes digestive juice into the bowel as well as insulin into the blood, the ovaries and testicles form ova and spermatozoa as well as their male and female hormones.

The *Pituitary* has been described as "the leader of the endocrine orchestra" for it controls the activity of the other glands to some extent. The size of a pea, it is slung from the under-surface of the forebrain immediately behind the crossing of the optic nerves; it occupies a little socket between the right and left middle cranial fosse. Section shows it to consist of two lobes of differing function. The *anterior* lobe is concerned with growth. Overactivity in childhood causes gigantism; deficiency of this portion results in stunting or dwarfing. In adults, overactivity causes the condition known as acromegaly,



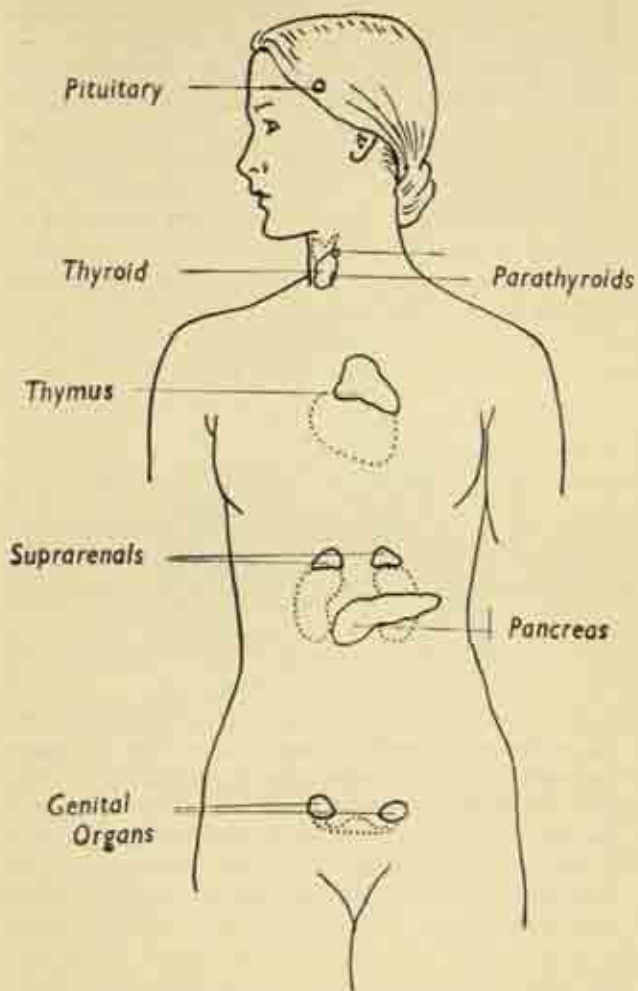


FIG. 150. The endocrine glands.

an enlargement of the head and hands accompanied by mental retardation. The *posterior* lobe controls the water balance of the body; diseased conditions result in the secretion of an excessive amount of dilute urine. It also increases the tonus of smooth muscle generally, raising the blood pressure and helping to empty the bowels and bladder.

The pituitary as a whole is intimately concerned with the ovary in regulating the female cycle of ovulation and menstruation, the development of the pregnant uterus, and the process of birth or parturition.

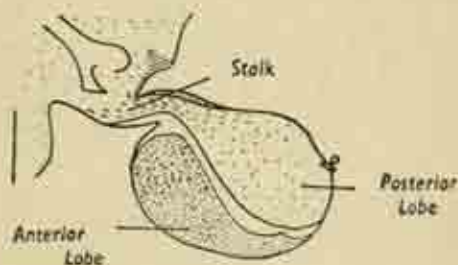


FIG. 151. The pituitary gland, longitudinal section.  
(After Gray).

The *Thyroid* has already been described in the section of this book dealing with the neck. Its secretion controls the rate of body metabolism, the general cycle of building-up and breaking-down of body tissues. Excess causes the overexcitability, rapid pulse, staring eyes and wasting of the condition known as Graves' disease. Deficiency causes cretinism in childhood, and an obese slow-wittedness in later life.

The *Parathyroids* are four small glands embedded in the thyroid capsule; they control the metabolism of calcium, and thus the degree of calcification of the skeleton generally.

The *Suprarenal* glands have been described in the abdomen as triangular cap-like organs sitting on the upper poles of the kidneys. They have an outer rind or *cortex* and an inner *medulla*. The function of the medulla is intimately connected with that of the sympathetic system, and indeed the two have developed in common. Through its hormone—adrenaline—an immediate response is possible to emergency situations; a

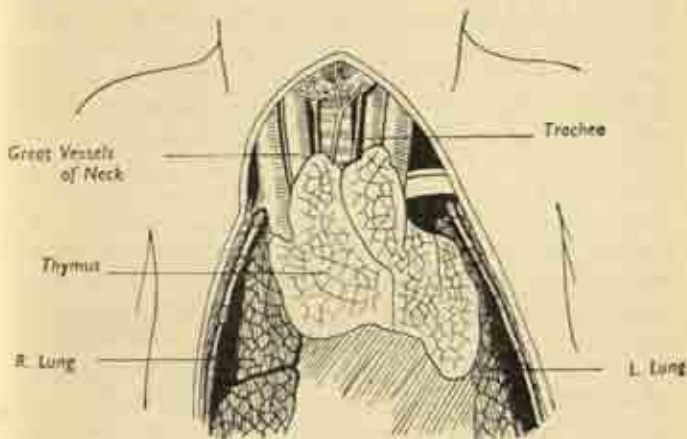


FIG. 152. The thymus in the new-born child  
(After Gray).

speeding-up of the circulation, raising of blood pressure, and mobilization of the liver-sugar. The cortical function is less clear; it concerns water and salt metabolism, and deficiency is slowly fatal, with profound prostration.

The internal secretion of the *pancreas* is *insulin*, essential to the utilization of sugar by the tissues; its deficiency is the cause of diabetes.

The *Gonads*. The ovaries and testicles, besides forming the reproductive cells—ova and spermatozoa—secrete the male and female sex hormones. These are responsible

for the development of what are called the secondary sexual characteristics, the attributes, though not the essentials, of male and female sexuality. These include hairiness, deep voice, coarse skin and narrow pelvis in men; hairlessness, smooth skin, broad pelvis and subcutaneous fat in women.

Two other organs are sometimes classed as endocrine glands, though it is by no means certain that they possess any specific function. The *pineal* gland is a tiny outgrowth from the roof of the third ventricle of the brain, a vestigial relic of the third eye in the top of the skull possessed by some lizards.

The *Thymus* is a large lobed structure in the foetus behind the upper part of the breastbone, covering the front of the great vessels and the upper pericardium. It greatly diminishes in size and may even disappear after the first few years of life. Overgrowth of the thymus in adult life is sometimes found to accompany certain rare and serious diseases of the muscles and nervous system. The minute structure of the organ is very similar to that of a lymphatic gland.

## CHAPTER XIII

### REPRODUCTION AND DEVELOPMENT

#### Reproductive Organs

THE essential sex organs are known as the *gonads*: a pair of *testes* in the male forming the spermatozoa, a pair of *ovaries* in the female forming the ova. The general plan of the reproductive system in both sexes is not dissimilar; but the final adult forms appear very different because, while the ovaries remain in the abdominal cavity, the testes come to lie outside it. And in the female there is a uterus to house the developing embryo, while the penis of the male is represented in the female only by a diminutive organ called the clitoris.

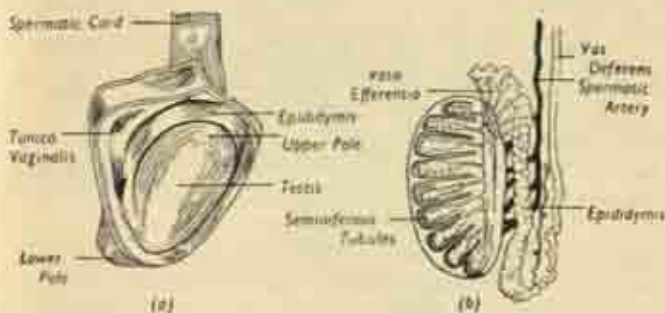


FIG. 153. (a) Testis and epididymis exposed by reflection of their serous covering, the tunica vaginalis. (b) The same in longitudinal section.

**Male Organs.** The testes develop in the abdominal cavity, but pass down shortly before birth to enter the loose skin pocket of the scrotum externally, where they hang down in the perineum on each side of the root of



the penis. There remains an oblique valve-like passage through the abdominal muscles just above the inguinal ligament, the inguinal canal, occupied by the stalk of the testis or spermatic cord which carries blood-vessels to the organ and the sperm duct back to the pelvic cavity.

The testes are ovoid structures, with a tough fibrous capsule, made up of lobules containing the fine tubes in which the spermatozoa are formed. Applied to their outer side is a curved organ, the *epididymis*, which

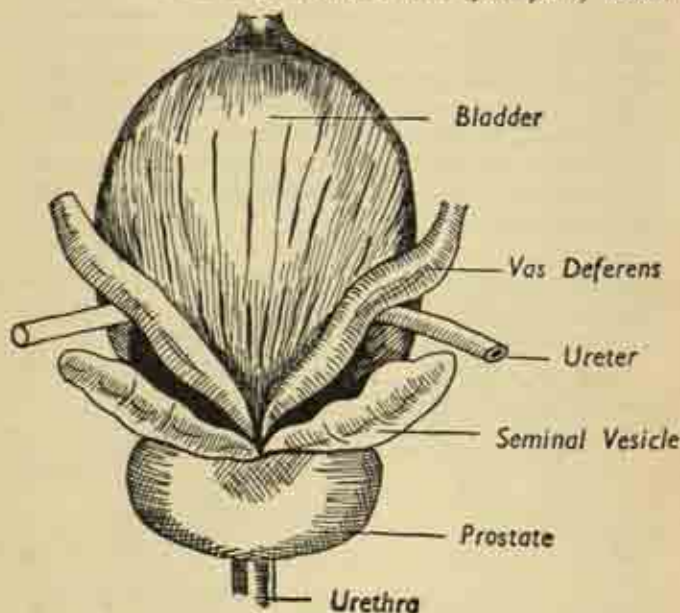


FIG. 154.

Bladder and associated organs in the male. Posterior aspect.

receives the sperm from the testis; it is an intricately coiled tube from which issues the main spermatic channel, the *vas deferens* running up to the abdomen. Testis and epididymis lie vertically in the scrotum, with upper and

lower poles, surrounded by a loose serous sac which is sometimes distended with fluid to produce a hydrocoele.

The vas deferens runs down the side wall of the pelvis to reach the back of the lower part of the bladder, where it lies on the upper surface of the prostate; here there is an associated sac attached to its outer side, the *seminal vesicle* for the reception and storage of sperm. The ducts of vas and vesicle open via a common *ejaculatory duct* into the urethra, which lies embedded in the prostate gland. Sperm are continuously formed in the testis, stored in the vesicle, and only enter the urethra in the final ejaculatory act of sexual orgasm, when they are discharged via the urethra and penis into the female vagina. It should be noted that the ejaculated fluid is not just the sperm, but a complex seminal fluid containing also the secretions of vesicles and prostate.

The *penis* consists of a central *bulb* arising from the centre of the perineum and traversed by the urethra; and two lateral *crura* springing from the sides of the pubic arch. These all soon join to form the shaft of the organ, a cross-section of which shows the disposition of its constituents (fig. 155). Here, the part containing the urethra, the continuation of the bulb, is the *corpus spongiosum* below, with the *corpora cavernosa*, continuations of the two crura, above on each side. It is to these latter that the organ owes its remarkable property of rapid increase in length and girth on sexual excitement, becoming rigid and capable of introduction into the vagina. This process of erection, contrasted with the flaccid state, is due to the presence of a system of cavernous spaces which can be rapidly distended with blood from the penile arteries.

**Female Organs.** The *ovaries* are a pair of almond-shaped organs, each lying on the side wall of the pelvis just below its brim. They are studded with fluid-filled cysts, the *ovarian follicles* in which the egg-cells or ova

ripen, one coming to maturity every month. The ovaries are embedded in a membranous sheet, the *broad ligament*, which stretches like a wing from the uterus to either side of the pelvis. And in the upper free edge of this ligament are the *uterine tubes*, attached to the uterus like outstretched arms to the shoulders. These muscular channels open into the uterus medially, and have at their outer ends a fringed funnel-like entrance which tends to curve towards and embrace the ovaries, so as easily to receive the ripe ovum when it is shed.

*Uterus.* The womb is a hollow organ, with thick muscular walls, lying in the middle of the pelvis between bladder in front and rectum behind. It communicates

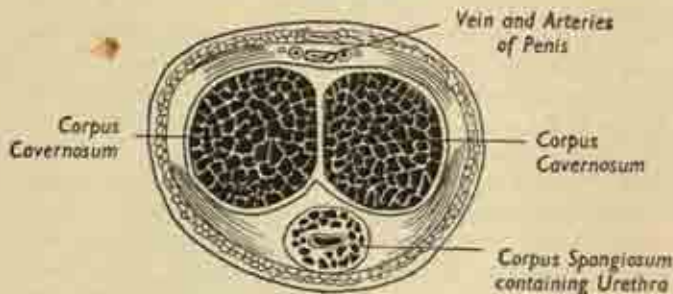


FIG. 155. Cross-section of shaft of penis. (After Gray).

below with the vagina and at each side with the uterine tubes. The organ is tilted forwards so that the anterior surface rests on the bladder, and the posterior surface faces up as well as back; both surfaces and the dome (or *fundus*) are covered with peritoneum, and the peritoneal pouch between uterus and rectum is the deepest part of the abdominal cavity.

The virgin uterus is three inches long, its wall an inch thick. Longitudinal section shows the upper *body*, two inches long, with a triangular cavity; and the lower *cervix*, an inch in length and traversed by a narrow

cervical canal opening into the main cavity at its internal orifice and into the vagina at its external orifice. The lining mucous membrane of the body, or *endometrium*, contains numerous mucous glands and undergoes striking regular changes during the menstrual cycle. The organ as a whole becomes enormously enlarged in pregnancy, but returns almost to normal after childbirth by a process of involution, though the cavity never quite regains its virgin state. The uterus is small and undeveloped in childhood, and shrinks and atrophies in old age.

The *vagina* is a distensible canal capable of receiving

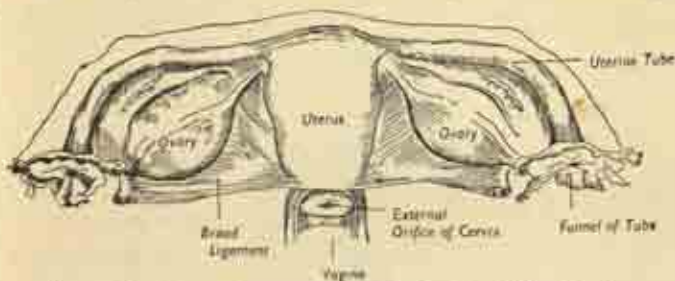


FIG. 156. Internal sex organs of the female. (After Gray).

the penis during intercourse and allowing the passage of the child in parturition. It extends from the uterus, which it meets at an angle of  $90^\circ$ , to run down and forwards through the pelvic floor and open externally on the perineum. Part of the cervix actually protrudes into the vaginal vault, the encircling rim of which is known as the fornix. The front wall of the vagina is intimately blended with the back of the bladder and the urethra; the back wall is separated from the rectum by fibrous tissue.

The *external female genitalia* are known collectively as the *vulva*. This includes the *mons pubis*, a fatty hair-covered eminence in front of the pubic symphysis; the skin folds forming the lips of the vaginal orifice, comprising

the outer thick *labia majora* and the inner slender *labia minora*; the *clitoris*, a diminutive but sensitive erectile equivalent of the penis lying at the meeting of the labia in front; and the *hymen*, an incomplete partition of mucous membrane stretching across the vaginal orifice in the virgin, which is ruptured by intercourse to leave a few peripheral tags. The external opening of the urethra is just behind the clitoris and immediately in front of the vaginal orifice. There are numerous mucous glands in this region.

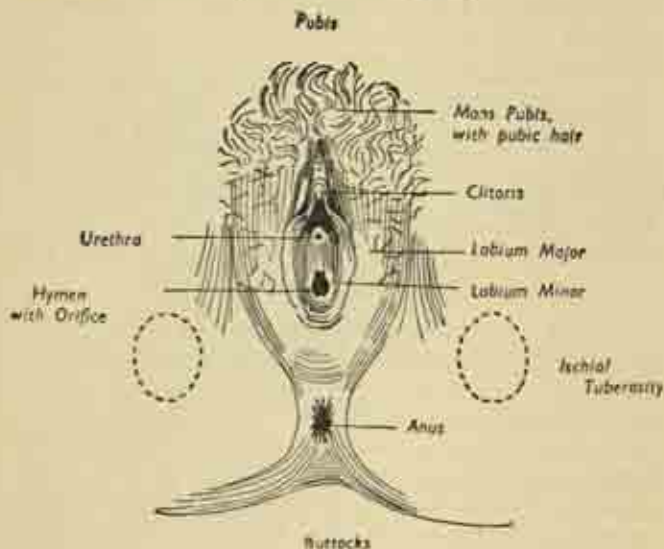


FIG. 157. The female perineum.

There is an inguinal canal in the female as in the male, but this contains no essential part of the genital organs, only a supporting ligament of the uterus terminating in the tissues of the groin.

The *breasts* may be described here, as the mammary



glands are accessories of the genital system; designed for milk secretion, they occur in a rudimentary form in the male as well as the female. In the latter, they form two large rounded eminences between the skin and deep fascia on the front of the chest, overlying the pectoral muscles; they extend from the second to the sixth ribs, and from beside the sternum out towards the axilla. Small before puberty, they develop then with the uterus, hypertrophy in pregnancy and especially at the lactation period after delivery, and atrophy in old age. There are minor cyclical changes with menstruation.

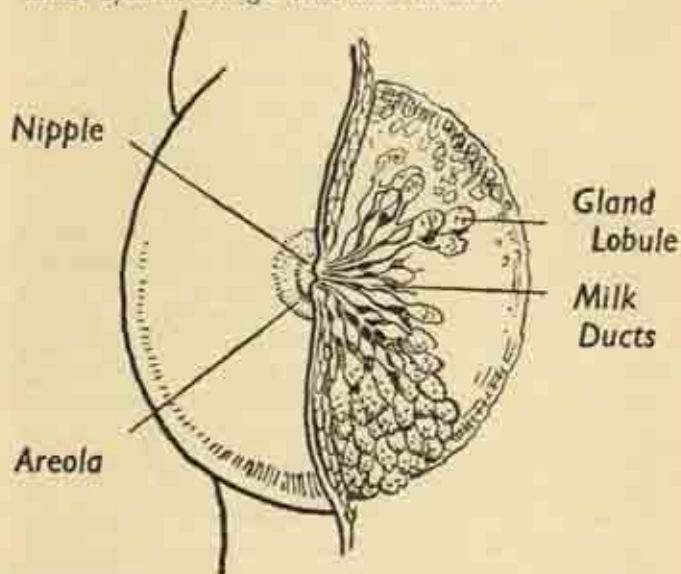


FIG. 158. The female breast, partly dissected to show the lobules.

The pigmented nipple at the apex of the breast is surrounded by a coloured area of skin, the *areola*; this is studded with sebaceous glands, is pink in the virgin and permanently darkened in the first pregnancy. The

nipple is perforated by 15-20 milk ducts opening at its summit; it is sensitive and contains erectile tissue. The gland itself is divided into numerous lobes by fibrous partitions, some strands of which go deeply to fasten the organ to the chest wall. Each lobe contains a branched system of secreting gland-spaces supported by much pervading fatty tissue; the larger ducts converge on the nipple, and expand just before reaching it as the milk sinuses or reservoirs. The gland spaces are only distended with milk during active functioning, and the organ as a whole is liberally supplied with blood-vessels for this purpose.

### **Reproduction.**

We may now give a brief account of the reproductive process, a complicated cycle regulated and controlled by the endocrine glands, particularly in the female by the pituitary. Each month an ovarian follicle ripens in the ovary, discharging an ovum into the peritoneal cavity—the process of *ovulation*. This egg-cell is taken up by the orifice of the uterine tube and propelled along that channel by peristalsis towards the uterus. Here the lining has become highly vascular and thickened, prepared for the embedding of a fertilized ovum; and if, as is usually the case, the ovum has not been fertilized, the mucous membrane is eventually shed to cause the bleeding of *menstruation*. This is taken as the beginning of the monthly cycle; it lasts 3-5 days, and then a new lining begins to be built up again and is completed by the fourteenth day of the cycle, midway between two periods; and it is just at this time that ovulation occurs again in the ovaries. Thus the cycle affects both ovaries and uterus; ovulation and menstruation alternate regularly at fortnightly intervals, the uterine lining is completed and receptive during the latter half of the cycle, destroyed at menstruation, and rebuilt in the first half.

*Fertilization*, the union of the male spermatozoon with

the female ovum, occurs normally in the uterine tube as the egg is moving towards the uterus. It can only occur if at this time a living sperm derived from the male by recent intercourse has made its way up the vagina, through the cervix and uterus into the tube, success, therefore, depends on a near coincidence of intercourse and ovulation.

### Development.

The nuclei of the two germ cells fuse, and the egg at once begins to divide or segment to form a rounded mass of cells, whose number is doubled at each division. This process begins before entry into the uterus, the journey

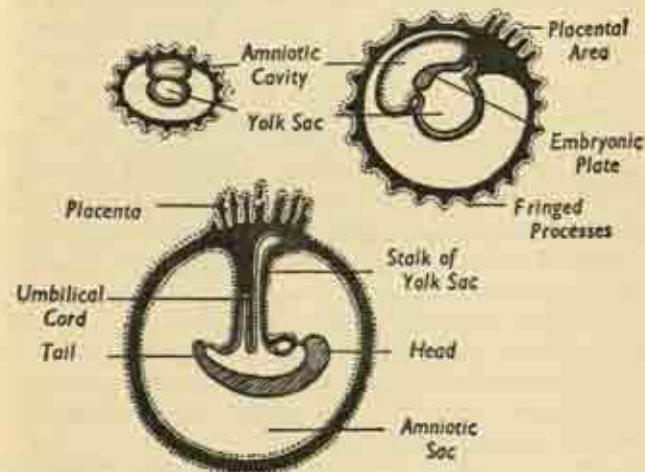


FIG. 159. Stages in the development of the early embryo.

along the uterine tube taking several days; once in the uterine cavity the ovum adheres like a parasite, excavating for itself a cavity in the mucous membrane, in which it becomes embedded and sealed off by a blood clot.

The early embryo consists of little more than a pair of sacs or vesicles, the *amniotic cavity* and the *yolk-sac*,

with an intervening plate which is the actual embryonic area at which individual development occurs. The amniotic cavity soon greatly expands, coming to line the whole of the uterus, and is filled with the amniotic fluid bathing the embryo. At the actual site of implantation the amniotic membrane develops a complex system of fringed vascular processes penetrating the uterine wall and bathed freely in the blood spaces of the latter. This constitutes the mass of the afterbirth or *placenta*, a thick fleshy disc of 6-8 inches diameter when maximally developed. It is here that maternal and embryonic circulations are in closest proximity; but there is no direct communication, oxygen and food substances having to diffuse across the separating layer of cells. The other embryonic cavity, the yolk-sac, becomes squeezed by the growth of the amnion into a narrow stalk, the core of the *umbilical cord* which connects the developing child, floating freely in the amniotic fluid, to the centre of the placenta. The cord is 20 inches long at birth, spirally twisted, and carries in its jelly-like substance the two umbilical arteries and the single umbilical vein of the foetus.

Since the foetus sends its stale blood to the placenta for oxygenation and nutriment, the umbilical vessels resemble the pulmonary trunks, i.e., the arteries contain stale venous blood, the veins fresh arterial blood.

**Embryonic layers.** The early embryo soon comes to possess three layers of cells responsible for the origin of all body tissues and organs.

The outer layer or *ectoderm* forms the skin, its glands, hair and nails; the nervous system; and the essential parts of the eye, ear and nose. The nervous system originally lies on the surface of the back of the body and is infolded in development as the neural tube, the precursor of the spinal cord, with a bulbous expansion at the head end marking the brain. All the sense organs originate in this outer layer; an infolding of greatly-

modified skin surface meets an outgrowth from the central nervous system. This arrangement is well shown in the eye where the retina, an extension from the brain on the stalk of the optic nerve, cups the transparent lens developed from the overlying skin.

The innermost layer or *endoderm* forms the whole of the bowel and its associated glands, such as liver and pancreas; the lining of the respiratory tract and lungs; the thyroid and parathyroid glands. We have noted that the intestine develops on the back wall of the abdominal

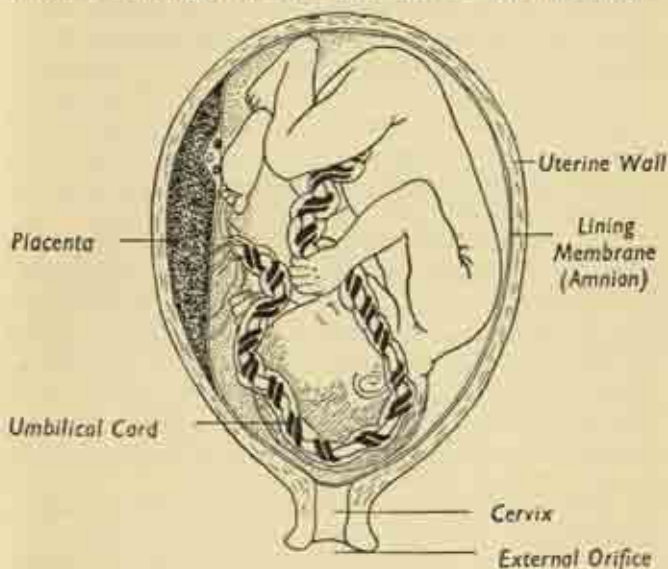


FIG. 160. The foetus in utero. (After Gray).

cavity, and then comes to lie suspended in that cavity by a mesentery still attached to the posterior wall. And though the small intestine retains this position, the large bowel undergoes a complicated rotation to bring the caecum and ascending colon to the right and the



descending colon to the left—a rotation that may be reversed, or left incomplete.

The intermediate layer is the *mesoderm*, origin of all the connective tissues of the body; the bone and cartilage of the skeleton; the teeth; all the muscles of both voluntary and involuntary type; the heart and blood-vessels; and the urogenital system.

The general features of the development of the limb-buds have already been touched on at p. 51. At any point in the unimaginably complex pattern of development things may go wrong, or not go far enough. The spinal cord may be left on the surface of the back as an open layer instead of a tube; or it may develop normally, but the two halves of the vertebral column fail to enclose it completely, leaving a gap behind, usually in the lumbosacral region—the condition known as *spina bifida*. The palate may remain cleft if its two halves fail to meet in the roof of the mouth; the septum of the heart may remain incomplete, allowing a vicious and disabling admixture of venous with arterial blood; a bone or a limb may fail to develop wholly or in part, fingers and thumbs may be too few or too many. What is outstanding in all this is the overwhelming frequency with which the developmental process inches its way to an accurate ending at a constant time, reciprocal organs maturing together. The surprise, indeed, is that any error is a rarity.

### Time-scale.

A note on the times of certain important stages may be given. The two primitive vesicles of the embryo are present some 10 days after fertilization, and the intervening embryonic area begins to develop in the third week; head and tail folds, neural groove and heart, are obvious by the fourth week. In the fifth week there appears the lens of the eye, the rudiments of the face, the

gill-arches, and the stumps of the limb-buds; and the embryo is now a fifth of an inch long. The sixth week sees the body well curved on itself, the head approximating to the long tail, the umbilical cord attached to the belly near the latter; the liver enlarges, the limb-buds grow out and are demarcated into their segments.

By the end of the eighth week the embryo is an inch long and is thenceforward known as the *foetus*; eyes, ears and nostrils are formed, the external genitals differentiated, and the fingers and toes clearly marked out. Fine downy hair appears in the fourth month, when the foetus is 8 inches long; in the fifth, foetal movements begin and the skin becomes covered with a greasy secretion.

By the seventh month the eyelids have opened and the testicles descended into the scrotum; and though the foetus may now be viable (i.e., capable of living) if born prematurely, it is not adequately clothed with subcutaneous fat until the end of the ninth month.

At birth, the uterus contracts, rupturing the membranes and expelling first the foetus and amniotic fluid, then the placenta, and finally the membranes turned inside out like an umbrella. Certain important changes occur in the child at and soon after this moment of birth. During foetal life the lungs have remained unexpanded and airless; they need no blood and the stream in the pulmonary artery is shunted through a bypass directly into the aorta. With the first cry the lungs expand, the pulmonary circulation is established, and the bypass soon closes off. The portions of the umbilical vessels contained within the foetus also become shrivelled-up and obliterated; and the former parasite has become an independent organism.

## CHAPTER XIV

### EVOLUTION

We may define man's place in the world of living creatures by successively narrowing our terms. He is an animal, and not a plant; multicellular, and not unicellular; a chordate—and a vertebrate chordate, not an invertebrate; a vertebrate with jaws, and not a jawless lamprey or hagfish; a terrestrial vertebrate, and not a fish; a warm-blooded mammal, and not a reptile, amphibian or bird; a placental and not an egg-laying or pouched mammal; a primate within the placentals, and an anthropoid within the primates; a man within the anthropoids, and finally a modern man—*Homo sapiens*—as distinct from more primitive forerunners.

Let us discuss these terms in more detail.

**Chordates.** These are a great group of animals ranging from degenerate forms such as sea-squirts to every form of vertebrate, but all derived from a simple, free-swimming, marine fishlike ancestor, an ancestor possessing certain characters separating it from earlier forms and handed down, with modifications, to all chordates since.

The elongated body was clearly differentiated into upper and lower surfaces, and though this body was segmented, segmentation was confined to the muscle mass along the back, the abdominal organs in the ventral portion of the body remaining as a unified system. This is quite different from the segmentation common in lower forms of life, such as the earthworm, where each body segment reduplicates the next and carries a complete set of organs. Chordate segmentation was also apparent,

not only in the dorsal muscle blocks, but in the nerves supplying them which emerged from a nerve cord running the length of the body. Finally, and characteristic of this group of animals—as its name implies—a stiffening rod, or *notochord*, the forerunner of the vertebral column in vertebrates proper, traversed the body from end to end immediately in front of the nerve cord, providing an axis of leverage for the muscles. The signs of this primitive organisation persist even in man. A relic of the notochord is to be found in the simple jelly of the pulpy central nucleus in each fibrocartilaginous disc between a pair of vertebral bodies—a relic still occupying its old place anterior to a nerve cord which has become the spinal cord. And the segmentation of the muscles of the back, and of the spinal nerves supplying them, is still to be seen—most clearly in the rib spaces—distorted though the pattern has been made by the evolutionary emergence of the limbs.

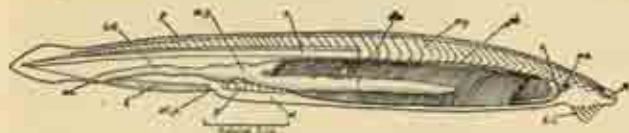


FIG. 161. A simple chordate still in existence, *Amphioxus*, the lancelet. Note the segmentation of the dorsal muscle blocks (*my*), partly removed to expose the notochord (*n*). The simple intestine (*int.*), mid-gut (*m.g.*) and their prolongation (*div.*), occupy a common ventral abdominal cavity and open externally at the anus (*an.*), *ph* is the pharynx. The nerve cord is not shown here.  
(From Young's *Life of Vertebrates*).

Biologically, the appearance of the fish-like chordate on the evolutionary scene was important. Simpler forms of life often have a free-swimming intermediate or larval stage in their life cycle, but the typical adult is sedentary on the sea floor. With the chordate we meet an active adult able to reach the surface and browse on the ample

food resources of the plankton, the first step from the sea bottom to dry land.

**Vertebrates.** The vertebrates are chordates possessing at least the rudiments of a cranium and some evidence of a vertebral column. The forward end of the simple nervous system has become a complex brain, and in relation to this there have appeared sense organs—eye, nose and ear—permitting a much more elaborate pattern of response to environmental stimuli. Movements became

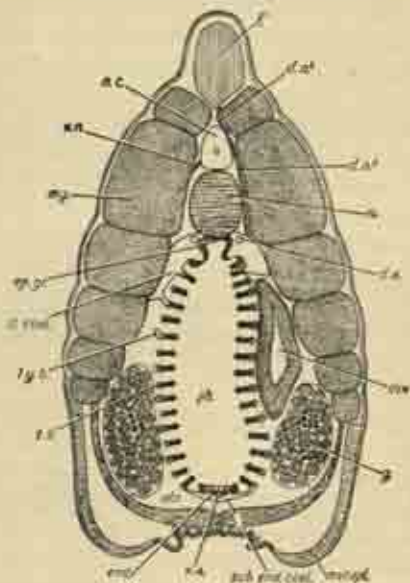


FIG. 162. Cross-section of *Amphioxus* in pharyngeal region. Dorsally, the muscle blocks (*m.*) surround the nerve cord (*n.c.*) with the notochord (*n.*) lying immediately in front. *ph.* is the cavity of the pharynx, which becomes continuous with the gut, and *g.* is the pair of gonads.  
(From Young's *Life of Vertebrates*).



more specialized to meet the needs of these stimuli and the side-fins of fishes were made use of, when vertebrates eventually became land animals, as limbs for locomotion and ultimately as hands for manipulation. In this long development they probably passed through a fresh-water stage and reduced the salt content of their blood. The earliest specimens of vertebrates, like our surviving lampreys, were without jaws; and the acquisition of jaws opened new possibilities in attack and food-gathering and lessened the need for heavy protective armament in the shape of ensheathing scales or bony plates. Typical, also, of vertebrate evolution was the acquisition of a chambered heart and of a respiratory pigment—*hæmoglobin*—carried in little packets in the red corpuscles and not in simple solution in the blood plasma, two changes greatly improving the efficiency of the circulation. This, with the air-breathing lungs and warm blood of birds and mammals, permitted in these two vertebrate forms an extravagant expenditure of energy in movement which had been hitherto impossible; a change almost comparable, in biological progress, to the arrival of atomic energy on the industrial scene.

**The head.** As vertebrates evolved, more and more importance attached to central control from the enlarging brain. An elaborate skull developed to protect this and to house the sense organs. In the dogfish the skull is a simple collection of cartilaginous boxes serving this purpose, boxes developed as modifications of the vertebral segments at this end of the body. (It must be remembered that in more primitive forms there is no particular head or tail end.) The jaws developed as modifications of the gill arches just behind the skull, into which they were eventually incorporated. In fact, the head of higher vertebrates, an apparently unique structure with a specialized neck to connect it to the trunk, is merely the

end-result of continuous evolutionary change in the vertebral segments at one end of the body. Because brain, jaws and sense organs have developed here the local segmentation of the skeleton has been correspondingly distorted to form the skull; and yet, despite their modern complexity, the bony skull and the brain with its pairs of cranial nerves correspond in their origin to the simple segmental elements of spinal column and spinal cord in the trunk proper.

**Mammals.** With the birds, the mammals represent the vertebrate form most adapted to life on land. Their peculiarities enable them to live in the most difficult conditions. As Professor J. Z. Young strikingly puts it, "A camel and the man he is carrying may contain more water than is to be found in the air and sand wastes for miles around", an instance of the extreme *improbability* of mammalian life which is so typical. All life is improbable against the background of the non-living universe, in the sense that living creatures maintain themselves and temporarily put a halt, in their protoplasmic whirlpools, to the general running down of energy. Mammals do this to a greater degree than any other forms, save the birds, and have raised the energy flux through the living body to its height. They can maintain a constant temperature higher than that of their surroundings. They can live in cold polar regions, and can also live and grow through the winters of temperate zones when cold-blooded creatures must hibernate. This free life in the most diverse external conditions is due to their ability to regulate such factors of their internal state as body temperature and the composition of blood and tissue fluids at an amazingly constant level, no matter how the outside world changes physically or chemically.

At the same time mammals have produced devices—limbs, hands, trunks—enabling them to alter their en-

vironment to suit themselves by digging or handling, by building dams—if they are beavers—or blasting pieces off the earth's surface if they are men. To quote Professor Young once more, "Warmth, enterprise, ingenuity and care of the young have been the basis of mammalian success throughout their history . . . They might well be defined as highly percipient and mobile animals with large brains, warm blood, and waterproofed, usually hairy, skins, whose young are born alive". They also have a diaphragm, a four-chambered heart, and a single left-sided aortic arch. Primitive mammals, it is true, shared the characters of other, lower, vertebrates. The surviving platypus has the skeleton and egg-laying habits of a reptile and a bird's bill, an exception which may once have been the rule. But the typical mammal is *placental* i.e., the young develop for a long period within the uterus and are fed during that time through a placenta attached to the inner lining of the uterus (see p. 290). Things are quite different in the few non-placental, pouched mammals, mainly marsupials, where the young are born only a few days or weeks after conception and crawl precociously to the pouch, where they glue themselves to the mother's teats for many days until separately viable.

The true placental mammals, as they evolved, tended to become larger, and their limbs longer; they walked on their digits and not on the soles of their feet; the teeth became specialized for predominantly herbivorous or carnivorous diet; and the brain expanded in certain regions—notably the frontal lobes—at the expense of the parts concerned with smell and so important to lower animals.

**Primates.** The original placentals were tree-living. The *primates*, and the monkeys, apes and men known as *anthropoids* within the larger primate group, remained

so and therefore retained the five fingers and toes and the mobile clavicle which other mammals have lost. In the active life of the treetops quickness of brain and movement, prehensile hands and feet and grasping great toes, the development of eyes and ears at the expense of smell, all progressed apace. The brain became enormously large, especially its occipital (visual) and frontal (associational) lobes. Claws gave way to nails. Mobility of the arm was greatly facilitated by retention of the clavicle, by adding the range of a mobile scapula to that of the true shoulder joint (see p. 78), and by an increasing range of pronation and supination. In reproduction, menstruation now appeared for the first time, a periodic breakdown of the uterine lining after the failure of elaborate preparations for the possible implantation of a fertilized ovum and subsequent placentation. Parents began to care for their young long after birth. The family arrived. Within the primates the anthropoids continued the development of a complex social life based on sight and not on smell, and accompanied by elaborate emotional expression. The outer ears shrank, the large eyes faced directly forward, the enormous cerebral hemispheres overhung the hindbrain, and the rounded head topped a mobile neck.

**Man.** Man's brain is larger than that of any ape and differs more from it than the ape's, in its turn, differs from the brain of other anthropoids. The swollen frontal and occipital lobes point to the greater importance of caution and restraint, reflection and vision, in human life. We have developed awareness of ourselves and of our world, conscious thought, and, above all, speech.

Man walks and balances on two legs routinely, and not occasionally, and his spinal column is correspondingly modified into a sequence of alternating curves under the vertical stresses (see p. 244). The intervertebral discs

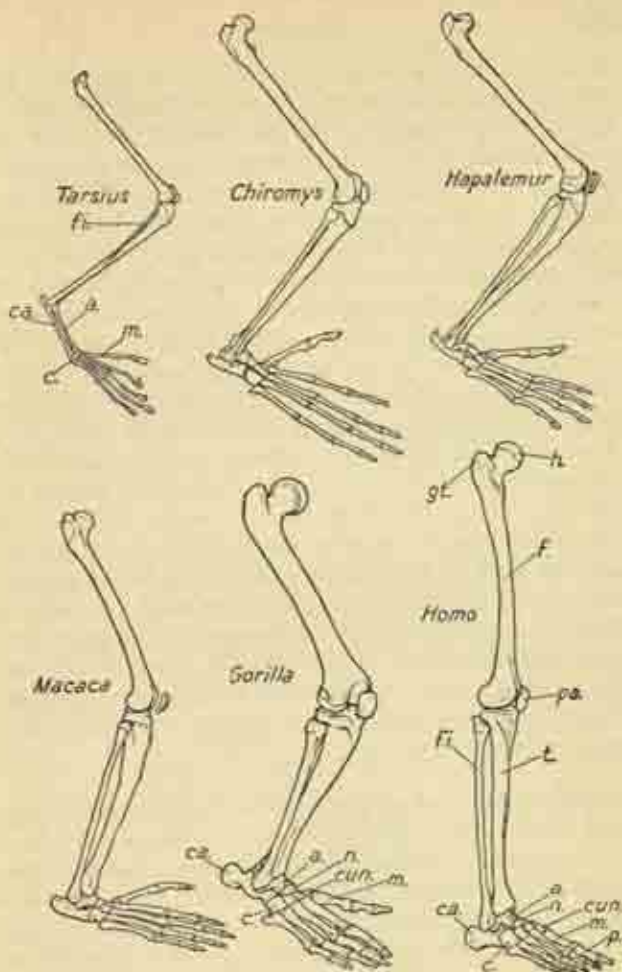


FIG. 163. The bones of the hind limbs of various primates arranged to suggest the evolutionary development of the characteristic features of the human leg—the vertical femur with its long neck and prominent great trochanter (*gt.*), the well-developed heel (*ca.*), and the non-opposable great toe (*m.*). (From Young's *Life of Vertebrates*).



become more important in size and function—and fail oftener. The architecture of pelvis, hip joints, thigh and leg bones also changes; and the internal structure and trabeculation of these bones reflect a purely mechanical solution to the engineering problems presented to them. *Balance*, the achievement of temporary stability in standing on one leg in running or walking, is a problem which produces great hypertrophy of the gluteal muscles in the buttock, whose function it is to fix the pelvis over the weight-bearing hip (see p. 132). The long neck of the human femur increases the leverage available to these muscles; and, although this elongation keeps the upper ends of the femora well away from the body, the inward slope of the thighs brings the knees and feet back under the centre of gravity. The arched system of weight distribution in the feet is peculiar to man; and so is the abandonment of the short mobile first metatarsal segment and the opposable great toe for a long fixed segment strong enough to take the propulsive thrust of walking. This change is not always satisfactorily accomplished; in some individuals the first metatarsal remains short and loose and the great toe adducted, an atavism which produces bunions in young people and makes it difficult to wear ordinary shoes.

The human *arm* and its muscles have become shorter and less powerful than in the apes as they do not have to support the body weight in swinging. And the chest, from which many of the shoulder-girdle muscles arise, is correspondingly puny. In the hand, the small intrinsic muscles controlling the digits have greatly developed, and a truly opposable thumb is seen for the first time in the animal kingdom. All the differences between upper and lower limbs in apes and men result from the single original difference that the ape uses his arms, and man his legs, to get about.

The characteristics of the human *skull* are the result of changes in brain size, changes in dentition, and of a new poise of head on neck. The growth of the frontal

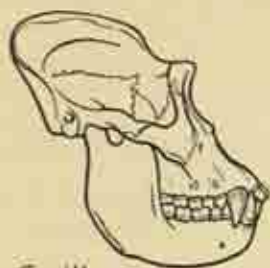
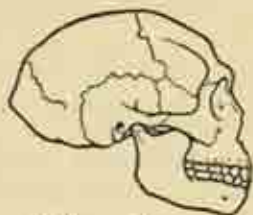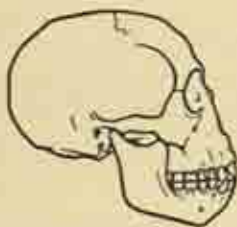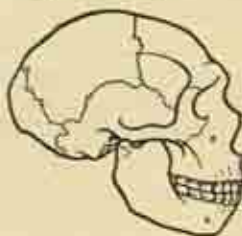
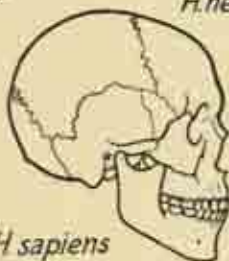
*Gorilla**Pithecanthropus**Eoanthropus**H. neanderthalensis**H. sapiens*

FIG. 164. The skulls of the gorilla and of progressive stages in the evolution of man. Note the general enlargement of the cranium, the rounding of contour, the development of the frontal region, and the recession of the lower jaw. (From Young's *Life of Vertebrates*).

lobes produced the vertical forehead and face, the more apparent since, at the same time, the jaws have receded (though the chin itself is a human phenomenon). The great brow and occipital ridges of the gorilla's skull have disappeared, and a general rounding of contour taken place. Vertical balance of the skull on the cervical spine is more perfect and the sternomastoid muscles, which turn the well-poised head from side to side, have pulled out the prominent mastoid processes from the base of the skull (fig. 125).

The general rate of growth and development of the human body is considerably slower than that of the apes, whose long bones have their epiphyses finally closed by the age of 12-14 instead of 14-18 as in man. But it is this long period of receptive immaturity, mental as well as physical, during which the young human being remains in constant need of care and protection, which also gives him an opportunity for learning and attainment unrivalled by any other creature.

## GLOSSARY-INDEX

- Abdomen**, 143  
     surface anatomy, 146  
**Abdominal cavity**, 143  
**Abdominal muscles**, 146  
**Abduction**, 61, the movement of a limb away from the side of the body  
**Accessory nerve**, 233, 266, the eleventh cranial nerve, supplying muscles in the palate, throat and neck  
**Acromion**, 65, the point of the shoulder  
**Acromion**, 66  
**Adduction**, 61, the movement of a limb towards the midline of the body  
**Adductor muscles**, 152  
**Adipose tissue**, 32  
**Air sinuses**, 218, air-containing spaces within the bones of the skull, extensions of the nasal cavities  
**Ankle joint**, 117  
**Anthropoids**, 299, 300  
**Arms**, 187, the external opening of the large intestine between the buttocks for discharge of food-wastes  
**Aorta**, 172, 207, the great central artery of the trunk, arising directly from the heart  
     branches, 207  
**Appendix**, 163, a small blind tube attached to the caecum, *s.a.*  
**Aqueous humour**, 271, the watery content of the front chamber of the eye  
**Arachnoid**, 248, the intermediate layer of the three membranes covering the brain and spinal cord  
**Arch of foot**, 119  
**Areolar tissue**, 32, loose web-like tissue packing the clefts and spaces of the body and separating skin from deeper structures  
**Aristotle**, 15  
**Arm**, 64  
     blood-vessels, 95  
     muscles, 86  
     nerves, 94  
     subcutaneous structures, 86  
**Artery**, carotid, 207, 233  
     hepatic, 169  
     innominate, 207  
     pulmonary, 204-5  
     subclavian, 207  
**Atria**, of heart, 203, the upper pair of the four heart chambers, thin-walled structures receiving blood from the great veins  
**Auditory nerve**, 265, the eighth cranial nerve, carrying information from the organs of hearing and balance  
**Autonomic nervous system**, 246, 267, the semi-independent and unconscious nervous apparatus controlling the internal organs  
**Ball and socket joint**, 58  
**Biceps**, 68, a large muscle in the front of the upper arm which bends the elbow  
**Birth**, 293  
**Bladder**, 185, a muscular bag situated in the pelvis which collects the urine from the kidneys and expels it into the urethra  
**Blood-vessels**, of arm, 93  
     of brain, 261  
     of large intestine, 163  
     of leg, 140  
     of neck, 233  
     of pelvis, 189  
     of thorax, 205  
**Bone**, 47  
     development, 51  
     growth, 53  
**Bones**, of arm, 68  
     of leg, 102  
**Brain**, 254  
     blood-vessels, 261  
**Breasts**, 296  
**Bronchi**, 198, 201, the main air-tubes of the lungs formed by division of the wind-pipe within the chest  
**Bursae**, 40, smooth tissue-spaces at points of friction over bony prominences which may become blown up with fluid, as in housemaid's knee  
     of leg, 128  
**Caecum**, 162, the roomy cul-de-sac at the beginning of the large intestine  
**Carotid arteries**, 207, 233, the great arteries of the neck running one on either side of the wind-pipe towards the skull  
**Carpus**, 72, the wrist  
**Cartilage**, 46  
**Cells**, 30  
**Central nervous system**, 246, the central axis of brain and spinal cord, as distinct from the peripheral nerves arising from that axis

- Cerebellum, 257, part of the hind-brain, a pair of hemispheres regulating posture and balance.
- Cerebral hemispheres, 255, the two great halves of the fore-brain.
- Chest, muscles, 193.
- Chordates, 294-5, primitive animals possessing a notochord, *i.e.*, and with segmentation confined to the dorsal musculature. All vertebrates have developed from some such ancestor.
- Choroid, 269, the intermediate, pigmented, coat of the eyeball.
- Choroid plexus, 248, 261, a velvety, blood-filled membrane lining certain of the cavities of the brain and secreting the cerebrospinal fluid.
- Circulation, 24.
- Clavicle, 67, the collar-bone.
- Coccyx, 241, the rudimentary tail-bone at the base of the spine behind the anus.
- Colon, 164, the main portion of the large intestine.
- Connective tissue, 32.
- Conatoid, 67.
- Coronary blood-vessels, 264, 268, the small vessels supplying the heart muscle.
- Cranium, 212, that part of the skull forming the brain-case.
- Cranial nerves, 263, pairs of nerves arising from the underside of the brain and travelling out through openings in the base of the skull.
- Deep fascia, 39, a tough sheet of connective tissue separating the skin and subcutaneous fat from the underlying muscles.
- Dermis, 38, the deeper of the two layers of the skin.
- Diaphragm, 177, the muscular and tendinous partition between abdominal and thoracic cavities.
- Digestive system, 22.
- Duodenum, 159, the first part of the small intestine, immediately connected with the stomach.
- Dura mater, 246, the tough outer fibrous layer of the three membranes covering brain and spinal cord.
- Ear, 271.
- Ectoderm, 290, the outer layer of primitive cells in the developing embryo.
- Elbow joint, 77.
- Embryo, 289.
- Embryonic layers, 290.
- Endocrine glands, 278, glands discharging their secretion directly into the blood stream and not through a duct into a body cavity.
- Endoderm, 291, the innermost primitive cell layer in the embryo.
- Epidermis, 30, the superficial layer of the skin, partly composed of dead horny cells.
- Epididymis, 287, a curved organ applied to the side of the testis in the male and collecting the sperm from it.
- Epiphyses, 52, the growing ends of long bones.
- Epithelium, 31, a continuous sheet or layer of cells lining surfaces or cavities.
- Erector spinæ muscles, 194, a pair of powerful straplike muscles running one each side of the length of the spine from skull to buttocks and helping to maintain erect posture and to point the head.
- Extension, 61.
- Eye, 269.
- Eyelids, 271.
- Face, 220.
- Facial nerve, 263, the seventh cranial nerve, activates the facial muscles and secretion by the parotid salivary gland; also conveys taste sensation from the front of the tongue.
- Fasciæ, 39, broad sheets or layers of fatty or fibrous connective tissue forming boundaries and partitions between different levels of the body structure and the packing around internal organs.
- Fat, 39.
- Femoral artery and vein, 140, the principal blood-vessels in the front of the thigh, between groin and knee vein, 140.
- Femur, 106, thigh-bone.
- Fertilization, 288, union of the male spermatozoon with the female ovum.
- Fibula, 108, the outer and relatively slighter of the pair of bones in the lower leg.
- Fingers, 74, 97, 101.
- movements, 81.
- Flat bones, 50.
- Flexion, 61.
- Fontanelles, 214, soft spots in the baby's skull not closed by bone at birth.
- Foot, 139.
- arches, 119.
- bones, 109.
- movements, 118.
- Forearm, 71.
- muscles, 91.
- Forebrain, 255.
- Frontal bone, 213, the bone of the forehead in the skull vault.
- Gait, 123.
- Galen, 12.



- Gallbladder, 168, a small bag on the underside of the liver collecting and storing the bile until required in digestion
- Ganglia, 266, swellings on nerve trunks containing nerve cells at which impulses are relayed
- Genes, 30, the units of inheritance contained in the chromosomes of cell nuclei
- Glossopharyngeal nerve, 265, the ninth cranial nerve, mainly carrying sensation from the back of the throat and tongue
- Gluteal muscles, 131, buttock muscles
- Gonads, 279, the male and female organs—testes and ovaries—forming the reproductive cells and the sex hormones, *q.v.*
- Grey matter, 250, 254, that part of brain and spinal cord composed mainly of nerve cells, as opposed to nerve fibres
- Hamstrings, 134, muscles at the back of the thigh flexing the knee
- Hand, 73, 96-8
- Harvey, William, 14
- Head, 212  
evolution of, 297  
surface anatomy, 218
- Heart, 27, 197, 202  
surface marking, 195  
valves, 205
- Hepatic artery, 169, the principal artery to the liver
- Hindbrain, 257
- Hinge joint, 58
- Hip girdle, 62
- Hip joint, 110
- Hippocrates, 13
- History of Anatomy, 12
- Humerus, 67, 70, the bone of the upper arm
- Hunter, William and John, 14
- Hymen, 286, the membranous partition at the entrance to the vagina in virgins
- Hyoid bone, 216, a small bone in the front of the neck behind the chin; the uppermost part of the 'Adam's apple'
- Inferior vena cava, 172, 205
- Inferior vena cava, 172, 205, the great vein of the trunk, carrying venous blood from the legs and abdominal organs through the diaphragm to the right side of the heart
- Innominate bone, 102, the right or left half of the pelvis, the 'hip bone'
- artery, 297, the first great branch of the aorta (*q.v.*); arising within the upper part of the chest, it soon divides into the carotid and subclavian arteries supplying the head and neck and arm on the right side. On the left side there is no innominate vessel, the carotid and subclavian arising directly from the aorta
- Insulin, 174, the internal secretion, or hormone, of the pancreatic gland; absence or deficiency of insulin is the cause of diabetes
- Intercostal nerves, 210, pairs of spinal nerves running round the chest wall between the ribs
- Intervertebral discs, 243, fibro-cartilaginous buffers separating the bodies of the vertebrae in the spinal column; each disc contains a gelatinous nucleus
- Joints, 54
- Jugular vein, 234; the internal jugular is the main vein of the neck on each side, corresponding to the carotid artery; the external jugular is a much smaller superficial vessel easily seen under the skin
- Kidneys, 175
- Knee joint, 112
- Large intestine, 162, continues the intestinal tract from the end of the small intestine to the opening of the anus and consists of the caecum, colon, rectum and anal canal in that order
- blood-vessels, 165
- Larynx, 231, the voice-box, a group of cartilages in the neck containing the vocal cords
- Latissimus dorsi, 193
- Leg, 102  
blood-vessels, 140  
bones, 102  
muscles, 129  
nerves, 141  
surface anatomy, 123
- Less, 271
- Ligaments, 56
- Limb girdles, 61
- Lips, 222
- Liver, 167
- Long bones, 48
- Lungs, 199  
surface marking, 195
- Lymphatic system, 29, an arrangement of vessels for conveying back into the blood stream the watery fluid permeating the tissue spaces

- Mammals, 257-9, warm-blooded animals whose young are born alive
- Maxilla, 212, 217, the lower jaw
- Man, in evolution, 294, 301-3
- Marrow, 49
- Median nerve, 95
- Medianum, 196, the vertical partition which divides the chest cavity into right and left halves and contains embedded the heart and great blood-vessels
- Medula oblongata, 257, part of the hindbrain, *q.v.*; the lowest part of the brain, it is the upward continuation of the spinal cord and contains the vital centres controlling the heartbeat and respiration
- Membranes, of foetus, 293
- of nervous system, 246
- Menstruation, 288
- Mesentery, 155-6, 161, a double layer of peritoneal membrane enveloping and suspending organs within the abdominal cavity
- Mesoderm, 292, the intermediate of the three primitive cell-layers of the embryo; from it are formed all the connective tissues, bones, cartilage and muscles, and the blood-vessels of the body
- Mesodermis, 292
- Metacarpals, 73
- Metatarsals, 110
- Midbrain, 257
- Mitosis, 86, the elaborate process of cell-division
- Mouth, 222
- Muscle, 34, 40
- Muscles, of abdomen, 148
- of arm, 89
- of chest, 193
- of thigh, 128
- of lower leg, 136
- of mastication, 221
- of neck, 228
- Neck, 225
- blood-vessels, 233
- muscles, 228
- nerves, 234
- surface anatomy, 227
- triangles, 226
- Nerves, of arm, 94
- of leg, 141
- of neck, 234
- of pelvis, 189
- of thorax, 209
- Nerves, accessory, 266
- auditory, 263
- cervical, 233
- cranial, 263
- facial, 269
- glossopharyngeal, 263
- trigeminal, 263
- oculomotor, 264
- olfactory, 263
- optic, 263
- pathetic, 263
- phrenic, 210
- spinal, 251
- trigeminal, 264
- trochlear, 264
- vagus, 233
- Nervous system, 246
- Nervous tissue, 36
- Neurone, 36, the essential unit of the nervous system, a nerve cell with its elongated branches
- Nipple, 195
- Nose, 274
- Notochord, 279, a stiffening rod traversing the length of the body in chordates in front of the nerve cord, the forerunner of the vertebral column
- Occipital bone, 213, the bone forming the back of the skull
- Oculomotor nerve, 264, the third cranial nerve, controlling four of the six small muscles moving the eyeball
- Oesophagus, 209, 232, the gullet
- Olecranon, 71, the point of the elbow formed by a projection at the upper end of the ulna
- Olfactory nerves, 263, the first cranial nerves, conveying smell sensation from the nose
- Omenta, 156, folds of peritoneum attached to the stomach
- Optic nerves, 263, the second cranial nerves, carrying light sensation from the eye
- Ovaries, 265, the female generative organs in which the egg-cells or ova are formed
- Palate, 224, the partition, bony in front and muscular behind, separating the nasal cavity from the mouth and pharynx
- Pancreas, 174
- Parasympathetic, 267, 269, one component, together with the sympathetic, of the semi-independent nervous system controlling the automatic working of internal organs, heart and blood-vessels
- Parathyroid glands, 233, 279, four pea-sized ductless glands embedded in the thyroid gland and controlling the usage and distribution of calcium in the body
- Parietal bones, 213, the two bones forming the right and left sides of the vault of the skull

- Parotid glands, 221, a pair of salivary glands; situated in the back of the cheek, below and before the ear, these glands are painfully enlarged in mumps
- Patefia, 107, the knee-cap
- Pathetic nerve, 263, the sixth cranial nerve, controlling one ocular muscle
- Pelvis, 179, a term applied both to the great basin formed by the two hip (innominate) bones and to that lower portion of the abdominal cavity containing the bladder, rectum and sexual organs, enclosed therein
- cavity, 143
- floor, 184
- nerves, 189
- sex differences, 181
- surface anatomy, 182
- vessels, 189
- viscera, 185
- Penis, 283, the external shaft of the male sexual organ, used in sexual intercourse and in micturition
- Pericardium, 202, the membranous bag enclosing the heart
- Pecotestum, 48, a tough fibrous membrane enclosing a bone
- Pernonum, 145, 154, the smooth, glistening membrane lining the abdominal cavity and reflected on to the abdominal organs
- Phalanges, 74, the bones of the fingers and toes
- Pharynx, 230, the common cavity for food and air at the back of the mouth and nose
- Phrenic nerves, 210, a pair of nerves arising from roots of the spinal cord in the neck and traversing the chest, one on either side of the heart, to supply the muscle of the diaphragm
- Pia mater, 248, the innermost and most delicate of the three meninges enclosing the brain and spinal cord
- Pituitary gland, 257, 276, one of the most important endocrine glands, *i.e.*, a pea-like body hanging from the underside of the brain and occupying a pocket in the base of the skull
- Placenta, 250, or afterbirth, a fleshy disc attached to the inside of the uterus and connected to the developing child by the umbilical cord, across which food and oxygen diffuse from the maternal blood-vessels
- Pleura, 135, 196, a glistening smooth membrane lining the chest cavity and reflected over the lungs, whose movements are thus facilitated
- Popliteal fossa, 135, a diamond-shaped space between the tendons at the back of the knee
- Portal vein, 169, a large vein carrying blood with the products of digestion from the intestine to the liver
- Portal circulation, 29, 173
- Posture, 44
- Primates, 299-300
- Pronation, 80, the movement of the radius on the ulna in the forearm which carries the hand into the palm-down position
- Pulmonary vessels, 204-5, the great arteries and veins connecting heart and lungs and different from all other blood-vessels in that the veins carry oxygenated, and the arteries deoxygenated, blood
- Quadriceps, 133, the great four-headed muscle in the front of the thigh which extends the knee
- Radial nerve, 94, a large nerve in the arm and forearm, mainly concerned in supplying the muscles which extend the elbow and the wrist and fingers
- Radio-ulnar joints, 79-80
- Radius, 71, the outer of the two paired bones in the forearm
- Rectus abdominis, 150, one of a pair of straplike muscles extending the length of the front of the abdomen on either side of the umbilicus
- Rectum, 187, the lower portion of the large intestine, within the pelvic cavity; it discharges the faeces through the anal canal to the exterior
- Reflexes, 252, automatic reactions to stimuli performed without intervention of the will, though often with conscious knowledge
- Reproduction, 281, 288
- Respiration, 192
- Respiratory system, 22
- Retina, 270, the pigmented innermost coat of the eyeball; it consists of nerve cells whose fibres join to form the optic nerve trunk
- Ribs, 190
- Rotation, 61
- Sacrum, 241, a large triangular bone interposed at the back between the two innominate bones; it is the lowest portion of the spinal column, with the exception of the coccyx, and formed by the fusion of five sacral vertebrae
- Salivary glands, 224, the parotid, submaxillary and sublingual glands which discharge saliva reflexly into the mouth on eating

**Sartorius**, 134, a long straplike muscle crossing the front of the thigh obliquely downward and inward, used in sitting cross-legged—the tailor's muscle.

**Scalp**, 219.

**Scapula**, 64, the shoulder-blade.

**Sciatic nerve**, 141, a great nerve trunk in the buttock and back of the thigh: it supplies the hamstrings in the thigh and all the muscles and most of the skin sensation below the knee.

**Sclera**, 209, the tough white outer protective coat of the eyeball.

**Sebaceous glands**, 39, the grease-producing glands of the skin.

**Segmentation**, 21, the division of the body into a series of similar or nearly similar segments from head to tail end which is clearly shown in the earthworm and still hinted at in the repetitive pattern of the vertebral column, spinal cord and ribs in man.

**Semilunar cartilages**, 115, a pair of flat, crescentic cartilage cushions within the knee-joint, interposed between the opposing bone ends of femur and tibia.

**Sesamoid bones**, 31, small bones formed within tendons where these are exposed to friction over bony prominences; the patella is the largest example.

**Short bones**, 49.

**Short long-bones**, 49.

**Shoulder**, 64.

**Shoulder girdle**, 61-2.

**Shoulder joint**, 75.

**Movements**, 77.

**Skin**, 37.

**Skull**, 212.

**base**, 215.

**fossae**, 216.

**Small intestine**, 158, that portion of the alimentary tract continuing on from the stomach to the large intestine at the caecum.

**blood-vessels**, 160.

**Solar plexus**, 172, a mass of sympathetic nervous tissue situated on the posterior abdominal wall behind the stomach and just below the diaphragm.

**Sperm**, or **spermatozoa**, 203, the male reproductive cells, or seed, formed in the testes and designed for fertilisation of the female ova.

**Sphincter**, 157, a ring of muscle guarding the entrance or exit of a hollow organ.

**Spinal cord**, 249.

**tracts**, 253.

**Spinal nerves**, 251.

**Spine**, 238, 241.

**curves**, 244.

**movements**, 245.

**Spleen**, 170.

**Sternomastoids**, 228, a pair of long straplike muscles, to be seen and felt on either side of the larynx, running up and out from the breast-bone and inner ends of the collar-bones to be attached to the skull just behind the ears. They are important in maintaining the poise of head on neck.

**Sternum**, 191, the breast-bone.

**Stomach**, 157.

**Subclavian artery**, 207, the great artery destined to supply the upper limb after giving certain branches to the root of the neck; on the left side it arises directly from the arch of the aorta, on the right side as a branch of the innominate artery, *q.v.*

**Sublingual glands**, 229, a pair of salivary glands in the front part of the floor of the mouth.

**Superficial fascia**, 39, the same given to the great sheet of fatty connective tissue which underlies the skin everywhere save at the eyelids and scrotum, separating it from the deep fascia.

**Supination**, 80, the movement of the radius on the ulna in the forearm which turns the hand palm-upwards.

**Suprarenal glands**, 175, 279, a pair of endocrine glands, one perched on top of each kidney, formed of an outer *cortex* and an inner *medulla* secreting distinct and powerful hormones.

**Surface anatomy**—

- of abdomen, 146
- of arm, 83
- of head, 218
- of leg, 123
- of neck, 227
- of pelvis, 182
- of thorax, 193

**Symmetry**, 21, the similarity of the two halves of the body on either side of the median plane; many of the internal organs, however, are not symmetrical.

**Sympathetic chain**, 236.

**Sympathetic nerves**, 210.

**Sympathetic**, 267-8, the other component, with the parasympathetic, of the autonomic nervous system.

**Synovial joints**, 55, movable joints in which the bone ends are covered with articular cartilage and banded together by a fibrous capsule lined with a *synovial membrane* secreting *slimy synovial fluid*.

**Taste**, 275.

**Teeth**, 223.


**Testes**, 201.

- Testes**, 281, the pair of male generative organs, counterparts of the female ovaries, in which the sperm is formed
- Thoracic duct**, 29, 259, 237, the largest lymphatic trunk in the body, running up the back of abdomen and chest to empty into the great veins at the root of the neck on the left side. It carries the lymph from the whole body except the right arm and right side of head and neck
- Thorax**, 190, the chest cavity, 196  
contents, 198  
nerves, 209  
surface anatomy, 195  
vessels, 205
- Thumb**, 74  
movements, 82
- Thymus**, 280, a large lobed structure, most prominent in young children, lying in front of the upper part of the heart and the great vessels to the chest, immediately behind the upper portion of the breast-bone. Its function is not known, but its minute structure somewhat resembles that of a lymph gland
- Thyroid gland**, 232, 278, a large endocrine gland situated in the neck with a lobe on each side of the windpipe and a connecting isthmus
- Tibia**, 100, the shin-bone
- Tibi-fibular joints**, 115
- Tissues**, 31, aggregations of the same kind of cell with an intercellular substance or matrix peculiar to each
- Tongue**, 224
- Tonus**, 43, the slight degree of contraction normally present even in an apparently inactive muscle, important in the maintenance of posture
- Trachea**, 198, 232
- Trapezius**, 193
- Triangles of neck**, 226
- Triceps**—  
of arm, 88  
of calf, 137
- Trigeminal nerve**, 264, the fifth cranial nerve, conveying sensation from the orbit, upper and lower jaws, and skin of the face, and also supplying the muscles of mastication
- Trochlear nerve**, 264, the fourth cranial nerve, supplying one of the ocular muscles
- Ulna**, 71, the inner of the two paired bones of the forearm
- Ulnar nerve**, 96
- Ureter**, 175, 177, the tube carrying urine from kidney to bladder
- Urinary system**, 22
- Uterus**, 284, the womb
- Vagus nerve**, 209, 235, 265, 285, the tenth cranial nerve, an important nerve trunk traversing neck, chest and abdomen; it supplies the greater part of the parasympathetic contribution to the autonomic system
- Vagina**, 285, the canal in the female running from the neck of the uterus to the exterior into which the penis is received in intercourse and through which the baby is born
- Valve of heart**, 205
- Variation**, 11
- Vascular system**, 24, the blood circulatory system of heart, arteries, capillaries and veins
- Veins**, jugular, 233  
pulmonary, 204  
portal, 169
- Ventricles**—the cavities of certain hollow organs  
of brain, 259  
of heart, 203
- Vertebrae**, 238, the individual bones of the spinal column
- Vertebrates**, 295-7, chordates possessing at least the rudiments of a cranium and some evidence of a vertebral column
- Venallus**, 14
- Viscera**, 37, the organs contained within the chest and abdomen
- Vitreous**, 271, the jelly-like medium occupying the greater part of the eyeball (the posterior chamber) behind the lens
- Vulva**, 285, the external female genital organ, the entrance to the vagina
- White matter**, 250, fiber tracts in brain and spinal cord
- Wrist**, 72
- Wrist joint**, 82, the joint between the lower end of the radius and the carpal bones









ADVERTISING & PUBLICITY ALGEBRA AMATEUR ACTING ANAT  
BOOK-KEEPING BRICKWORK BRINGING UP CHILDREN BUSINESS  
CHESS CHINESE COMMERCIAL ARITHMETIC COMMERCIAL AR  
COMPOSE MUSIC CONSTRUCTIONAL DETAILS CONTRACT BRIDGE  
SPEEDWORDS ECONOMIC GEOGRAPHY ECONOMICS ELECTR  
ENGLISH GRAMMAR LITERARY APPRECIATION ENGLISH RENASCO  
REVIVAL VICTORIAN AGE CONTEMPORARY LITERATURE ETCH  
FREELANCE WRITING FRENCH FRENCH DICTIONARY FRENCH  
LIVING THINGS GEOLOGY GEOMETRY GERMAN GERMAN  
GOOD CONTROL OF INSECT PESTS GOOD CONTROL OF PLANT DISE  
GOOD FARMING BY MACHINE GOOD FARM WORKMANSHIP GOOD  
GOOD MARKET GARDENING GOOD MILK FARMING GOOD PIG KE  
GOOD ENGLISH GREEK GREGG SHORTHAND GUIDEBOOK TO THE  
GREAT BOLIVAR BOTHA CATHERINE THE GREAT CHATHAM CLEM  
LIBERALISM HENRY V JOAN OF ARC JOHN WYCLIFFE LENIN LOUIS  
ROBERT

# GIVE INSTRUCTION TO A WISE MAN...

PHRASE BOOK SAILING SALESMANSHIP SECRETARY  
DEBATE SPELLING STAMP COLLECTING STUDENT  
TYPEWRITING USE OF GEOGRAPHY WAY TO POETRY WRITING  
COOKERY FOR GIRLS DOGS AS PETS FOR BOYS AND GIRLS KNIT  
PHOTOGRAPHY FOR BOYS AND GIRLS RADIO FOR BOYS RIDING  
FOOTBALL FOR BOYS STAMP COLLECTING FOR BOYS AND GIRLS WO  
ACTING ANATOMY ARABIC ASTRONOMY BANKING BE  
CHILDREN BUSINESS ORGANISATION CALCULUS CANASTA C  
COMMERCIAL ART COMMERCIAL CORRESPONDENCE COMMER  
CONTRACT BRIDGE COOKING CRICKET DRAWING DRESS  
ECONOMICS ELECTRICITY ELECTRICITY IN THE HOUSE ELOC  
ENGLISH RENAISSANCE ENGLISH RENAISSANCE TO THE ROMANTIC  
LITERATURE ETCHING EVERYDAY FRENCH TO EXPRESS YOUR  
DICTIONARY FRENCH PHRASE BOOK GARDENING GAS IN THE  
GERMAN GERMAN DICTIONARY GERMAN GRAMMAR GERMAN  
CONTROL OF PLANT DISEASES GOOD FARM ACCOUNTING G  
GOOD FARM WORKMANSHIP GOOD FRUIT FARMING GOOD GRA  
GOOD MILK FARMING GOOD PIG KEEPING GOOD POULTRY KE  
GREGG SHORTHAND GUIDEBOOK TO THE BIBLE HINDUSTANI  
CATHERINE THE GREAT CHATHAM CLEMENCEAU CONSTANTINE CO  
JOAN OF ARC JOHN WYCLIFFE LENIN LOUIS XIV HILTON PERICLES PETER THE  
USE OF HISTORY WARREN HASTINGS WOODROW WILSON HOCKEY  
HOUSEHOLD ELECTRICITY HOUSE REPAIRS ITALIAN JOINERY  
MANAGEMENT MATHEMATICS HAND TOOLS ENGINEERING  
DRAUGHTSMANSHIP METEOROLOGY MODEL CRAFT MODERN DAY  
MUSIC NORWEGIAN PERSONAL EFFICIENCY PHILOSOPHY PHOTO  
SHORTHAND PLANNING AND DESIGN PLUMBING POLISH PO

CENTRAL ARCHAEOLOGICAL MUSEUM  
NEW DELHI

Call No.— 611/Lev 43

Author— David Levy

Title— Anatomy.

Borrower's Name	Date of Issue	Date of Return
P.K. Jain	22/6/73	1.5.77

*"A book that is shut is but a block"*

CENTRAL ARCHAEOLOGICAL LIBRARY  
GOVT. OF INDIA  
Department of Archaeology  
NEW DELHI.

Please help us to keep the book  
clean and moving.

S. D. 148, N. DELHI.